

Detection of Epstein-Barr Virus and *Helicobacter pylori* in Primary Malignant Gastric Lymphomas

Saburo SHIKUWA¹, Keiichiro MATSUNAGA¹, Hajime ISOMOTO², Masayuki OSABE¹, Yusuke TAKEHARA¹, Megumi OFUKUJI¹, Masaya YOSHIMURA¹, Akiro ITO¹, Isao SIMOKAWA³, Masahiro ITO³, Kuniyuki MURASE², Fuminao TAKESHIMA², Katsuhisa OMAGARI², Yohei MIZUTA², Shigeru KOHNO²

1) Department of Internal Medicine, Omura Municipal Hospital

2) Second Department of Internal Medicine, Nagasaki University School of Medicine

3) Department of Pathology, Nagasaki University School of Medicine

We studied five patients diagnosed with primary gastric lymphoma between 1985 and 1995 in Omura Municipal Hospital to investigate the relationship between *Helicobacter pylori*, Epstein-Barr virus and primary malignant gastric lymphoma. *H. pylori* was detected by hematoxylin-eosin stain, Giemsa stain, immunohistochemistry while EBV was detected by in situ hybridization in the lymphoma and background mucosa. *H. pylori* but not EBV, was detected in all cases. Furthermore, malignant lymphomas were mainly located in the area of the fundic gland where *H. pylori* was frequently identified and caused inflammation. In contrast, malignant lymphomas were not detected in areas with intestinal metaplasia. Our results suggest that malignant lymphoma may develop in a region where the immune system has been activated by *H. pylori*. In contrast, EBV is unlikely to play an important role in the development of gastric lymphoma, compared to *H. pylori*.

Key words: primary gastric malignant lymphoma (PGML), Epstein-Barr virus (EBV) *Helicobacter pylori* (*H. pylori*), in situ hybridization (ISH)

Introduction

The discovery of *Helicobacter pylori* has changed the conventional concept of gastroduodenal disease (1-6). Furthermore, current advances in molecular biology

have enhanced the elucidation of the role played by *H. pylori* infections (1-6) and certain viral diseases in the development of gastrointestinal malignancies (7-20). In this study, we investigated the relationship between *H. pylori*, EBV and primary gastric malignant lymphoma (PGML), as well as the relationship between these diseases and background gastric mucosa in five cases of PGML.

Materials and Methods

Patients

Between 1985 and 1995, five patients were diagnosed with PGML in Omura Municipal Hospital. They included three females and two males with an average age of 51.6 years (range, 35 to 74 years). Treatment included total gastrectomy in three and distal gastrectomy in the other two. Macroscopically, the tumor was of the ulcerative type in four and protruding type in one (Table 1).

Tissue preparation and staining

Surgical specimens were fixed in formalin, embedded in paraffin wax, and stained with hematoxylin-eosin (H&E), Giemsa, and periodic acid Schiff. Histopathologic diagnosis of all PGML was based on the Japanese LSG classification criteria. The distribution of *H. pylori* was examined in H&E stained sections, and Giemsa stained sections of the lesser curvature of the resected stomach. We also examined the relationship between PGML and background mucosa including inflammation, atrophy, and intestinal metaplasia.

Address Correspondence:

Saburo Shikuwa, M.D.
Department of Internal Medicine,
Omura Municipal Hospital,
133-22 Kogasima, Omura city, Nagasaki 856-0817, Japan

Table 1. The clinical and histological results

	Case 1	Case 2	Case3	Case 4	Case5
Age	74	42	48	35	59
Gender	F	F	M	F	M
Symptoms	Hematoemesis	Eigastralgia	Epigastralgia	Nausea	Epigastralgia
Location	CM	CM	M	AM	MCA
Size	6.5 x 6.0	7.0 x 6.0	4.5 x 3.5	7.0 x 6.0	11 x 8.5
Macroscopic finding	Ulcerative type	Ulcerative type	Ulcerative type	Ulcerative type	Protruding type
Microscopic finding (LSG classification)	Diffuse large cell type	Diffuse large cell type	Diffuse large cell type	Diffuse large cell type	Diffuse large cell type
MALT component	(-)	(-)	(-)	(-)	(-)
Invasion depth	ssr	mp	mp	sm	mp
Stage	IV	I	I	III	IV
<i>H.pylori</i>	positive	positive	positive	positive	positive

Immunohistochemistry

Immunohistological studies were performed by the avidin-biotin-peroxidase complex method using paraffin-embedded sections prepared from specimens fixed in 10% formaldehyde. The following mouse monoclonal primary antibodies or rabbit polyclonal primary antibodies were used at appropriate dilutions: UCHL1; L26, anti-*H. pylori* IgG used in this study were purchased from Dako Japan (Tokyo).

In-situ hybridization (ISH) of EBV

To determine the localization of EBV, ISH studies were carried out using EBV-encoded small RNA 1 and 2 (EBER) sequences as a target. A commercially available fluorescein-conjugated oligomer sequence served as a complementary probe (DAKO). Tissue sections (6 µm thick) were deparaffinized, dehydrated, treated with proteinase K, dehydrated and air-dried. Hybridization was performed for 2 h at 37°C in a humid chamber. After washing, detection of EBV was achieved using a mouse anti-FITC antibody, an alkaline phosphatase-conjugated rabbit anti-mouse antibody, BCIP/NBT development and Fast Red counterstaining. EBV-positive tonsil specimens from a patient with infectious mononucleosis and samples of EBV-related nasopharyngeal carcinoma were used as positive controls.

Results

Histopathologic findings

Morphological changes: All cases were classified as diffuse lymphoma, large cell type based on LSG

classification (Fig.1c). The depth of invasion was submucosa in one, muscularis propria in three, subserosa g in one. Clinical staging was stage 1 in two patients, stage 3 in one and stage 4 in two patients. In all cases, no component of mucosal associated lymphoid tissue (MALT) lymphoma was observed (Table 1).

Relationship between PGML and lymphoid follicles, neutrophils, atrophy, metaplasia, and H. pylori: In three cases, the PGML lesion was located in the fundic gland region (Cases 1, 2, 3), while in the other two cases (Cases 4, 5), the lesion involved the fundic and pyloric glands, but the main lesion was located in the fundic gland (Fig. 2a-e). None of the lesions was located in areas of intestinal metaplasia. Lymphoid follicles were observed in all tissue samples. *H. pylori* mainly distributed in the fundic glands but was not found in the area of the pyloric gland showing intestinal metaplasia. In Cases 1, 2, *H. pylori* was detected focally or in patches, respectively, over the area of the fundic glands. In Cases 3, 4, 5, abundant *H. pylori* was present diffusely in the area of the fundic glands and pyloric glands (Fig. 1a, b). Neutrophil infiltration was observed in the areas showing diffuse distribution of *H. pylori*.

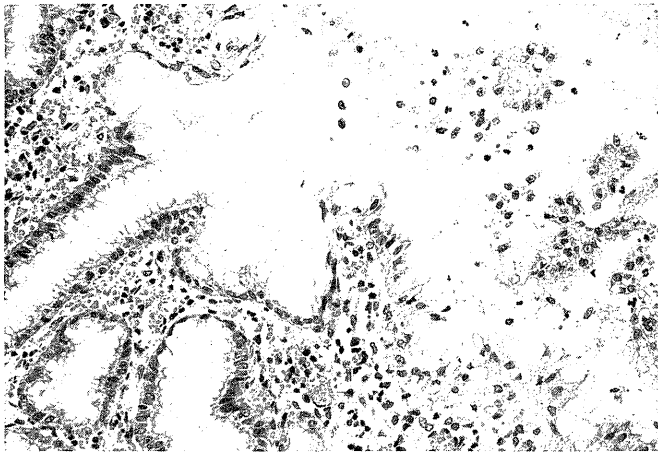
Immunohistochemical studies of PGML and *H. pylori*

H. pylori: Spiral organisms positive for the antibody to *H. pylori* were detected in all cases (Fig. 3a).

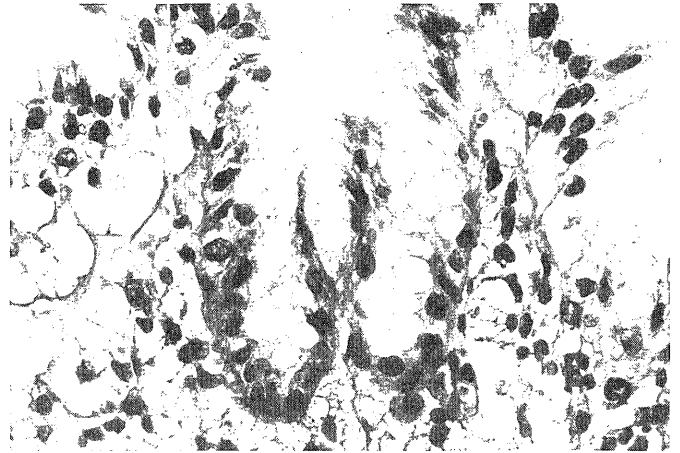
PGML: Neoplastic cells were positive for L26 (Fig. 3b), but negative for UCHL1 in all cases (Fig. 3c).

In-situ hybridization (ISH) of EBV

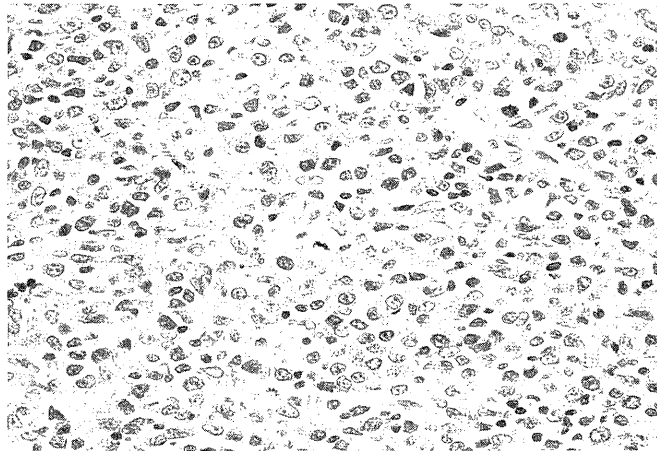
Neoplastic and normal lymphocytes as well as the



a) The affected fundic mucosa with *H. pylori* shows features of moderate chronic active gastritis with neutrophil infiltration in the pits and lamina propria (H&E, $\times 400$).



b) Abundant *H. pylori* diffusely distributed near the lesion involving the fundic gland (Giemsa stain 600).



c) Microscopic examination of a gastric tissue sample showing diffuse lymphoma, large cell type based on LSG classification (H&E, $\times 600$).

Fig 1. Microscopic findings in the stomach of a representative patient (Case 3).


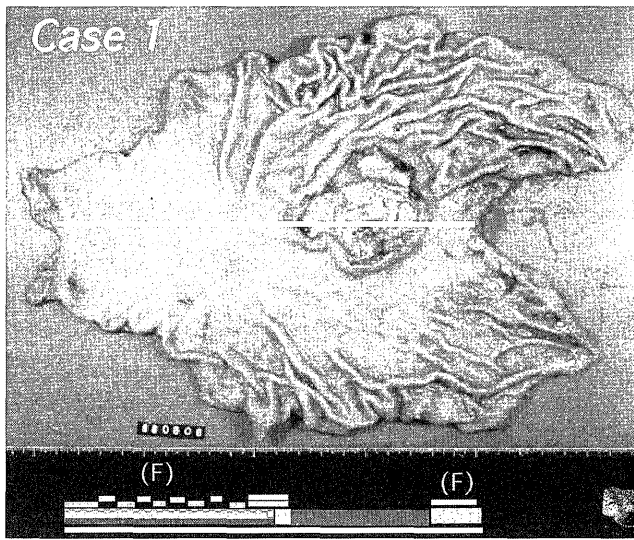
gastric mucosa around the lesion were negative for BHLF and EBER in all cases (Fig. 4a). The control case of malignant lymphoma with an infection of EBV was positive for BHLF and EBER (Fig. 4b).

Discussion

Primary extranodal non-Hodgkin's lymphomas occurring in the gastrointestinal tract frequently differ from lymphomas arising in lymph nodes or in other primary lymphoid organs such as the spleen, tonsils, skin, and thymus. Gastrointestinal lymphomas usually display a B-cell phenotype, and are believed to originate from cells of the mucosa-associated lymphoid tissue (2).


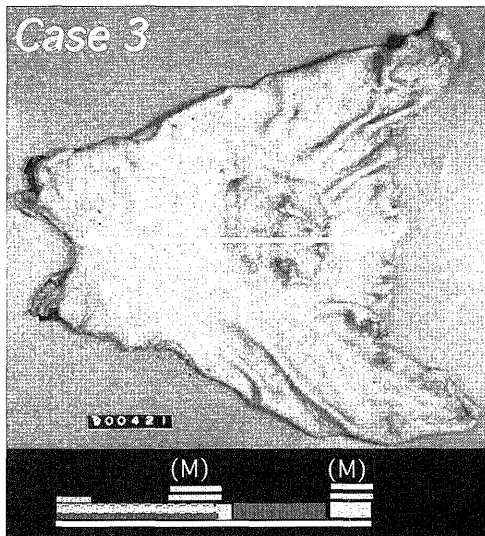
Warren and Marshall discovered the spiral urease-producing *H. pylori* in the human stomach in 1983 (1), and this organism is now known to be associated with gastroduodenal disease including gastric and duodenal ulceration (2-6). Recently, *H. pylori* was also considered to be strongly associated with gastric lymphoma (3-6). For example, Wotherspoon et al. (4) examined 110 cases of gastric MALT and found *H. pylori* infection in 101 of these cases (92%). In addition, other groups reported that eradication of *H. pylori* by antibiotic therapy produced a regression of gastric lymphoma arising from mucosa-associated lymphoid tissue (5, 6). However, to date there is no direct evidence that *H. pylori* causes gastric malignant lymphoma.

Current advances in molecular biology using polymerase chain reaction and in situ hybridization



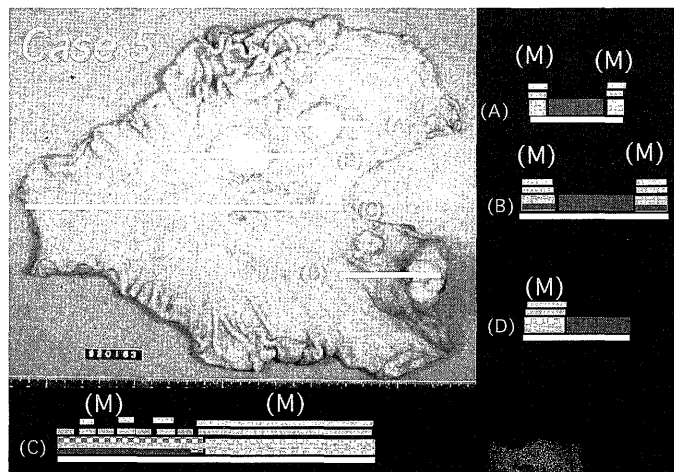
a) Case 1

b) Case 2




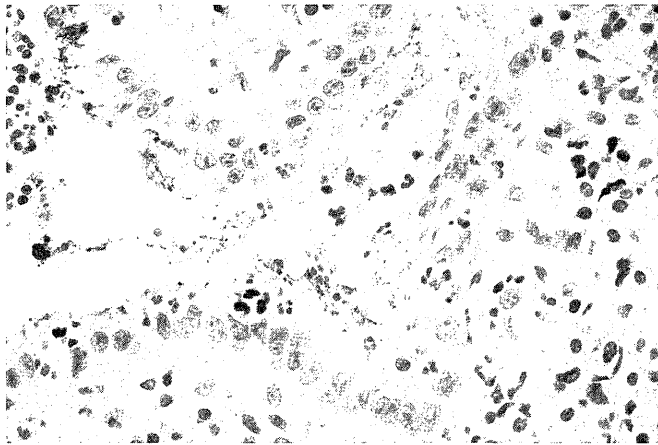
c) Case 3

d) Case 4



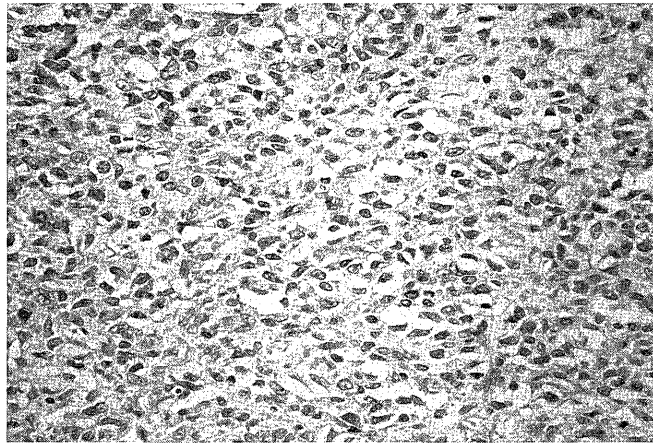
e) Case 5

Fig 2. Relationship between PGML and lymphoid follicles, neutrophils, atrophy, metaplasia, and *H. pylori*.



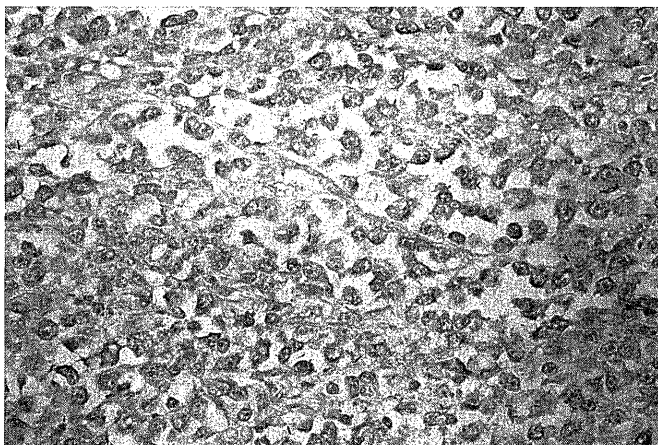
a) Immunohistology demonstrating the presence of spiral organisms positive for IgG-*H. pylori* (ABC 600).

b) Neoplastic cells were positive for L26.

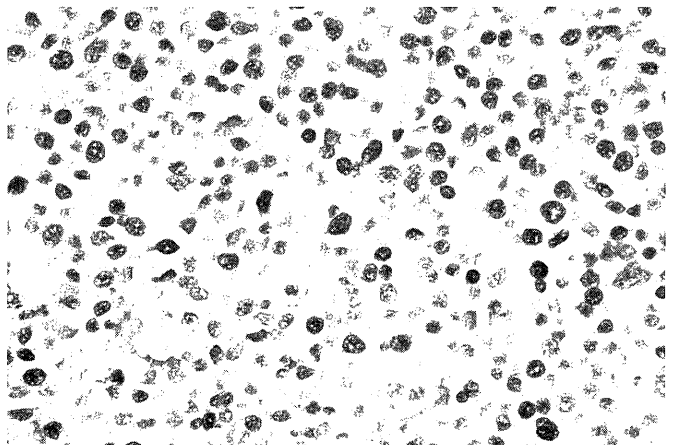


c) Neoplastic cells were negative for UCHLI.

Fig 3. Immunohistochemical findings in a representative patient (Case 3).



a) Neoplastic cells in a case of generalized malignant lymphoma.



b) Neoplastic and normal lymphocytes as well as gastric mucosa around the lesion were negative for BHLF and EBER in all cases.

Fig 4. In situ hybridization of generalized and gastric lymphoma.

have made it possible to determine the involvement of oncogenic viruses, such as EBV, hepatic B virus, HTLV-1, and certain human papilloma viruses, in the development of a large proportion of certain types of human cancers (7-20). Recently, EBV was confirmed to be associated with a variety of neoplasms including Hodgkin's disease, B cell lymphoma in immunodeficient individuals, T cell lymphoma, nasopharyngeal lymphoepithelioma, and gastric carcinoma with massive lymphocytic infiltration (8-20).

EBV infects B cells and exhibits strong tropism for human B cells. The infected B cells are immortalized and can be propagated *in vitro* (17). However, EBV is a ubiquitous and asymptomatic virus because EBV infection is readily controlled by effective immune responses in normal individuals (17). In Africa, immunological disorders due to malaria infection promote the development of Burkitt's lymphoma along with EBV infection and gene-related factors (19, 20). We consider PGML similar to Burkitt's lymphoma with regard to the following characteristics: 1) It frequently originates from B lymphocytes, and 2) it causes chronic active gastritis associated with *H. pylori* that may impair or activate local immune competence in the stomach. We therefore postulated that *H. pylori* and oncogenic viruses, such as EBV, may mutually be involved in the development of PGML. The present study investigated the prevalence of *H. pylori* and EBV in five patients with PGML, and also examined the relationship between these diseases and the background gastric mucosa.

The major findings of our study were: 1) malignant lymphoma was mainly located in the area of the fundic glands where *H. pylori* is frequently distributed and caused inflammation, and was not found in areas showing intestinal metaplasia. 2) In all cases of malignant lymphoma, *H. pylori* but not EBV, was detected in gastric tissues. The above first major finding suggests that PGML may arise in regions where *H. pylori* has activated the immune system. The second major finding suggests that EBV does not play an important role in the development of PGML, compared with *H. pylori*. With regard to the relationship between primary gastric lymphoma and EBV, Qiang et al. (16) examined 49 cases of primary gastric lymphomas consisting of low-grade MALT (16 cases), centroblastic (30 cases) and immunoblastic (3 cases) subtypes. They detected EBV in two cases of MALT and two cases of the centroblastic subtype (8%). On the other hand, Ott et al. (17) examined 55 cases of primary gastric lymphoma consisting of low-grade MALT (27 cases), centroblastic (22 cases), immunoblastic (2 cases), large cell anaplastic (3 cases), and T-pleomorphic (1 case)

subtypes. They demonstrated that primary gastric B-cell lymphoma of MALT and large cell anaplastic type were clearly negative for EBV mRNA, while three PGML were positive for EBV. In two of the three cases, primary gastric B-cell lymphoma clearly arose from a low grade lymphoma of MALT type that was positive for EBV. The above studies suggested that EBV is not particularly associated with primary gastric lymphoma (13-15). However, these studies indicated that the prevalence of EBV in PGML ranged from 5 to 8% (16, 17). Furthermore, recent studies showed that EBV was detected in 6 to 15% of patients with gastric carcinoma (9-15). This suggests that EBV may play a role in the development of PGML and carcinoma of the stomach. However, due to the small sample size in the present study, no firm conclusions could be made regarding the prevalence of EBV in gastric carcinoma. Further studies are required to investigate how oncogenic viruses including EBV are associated with the development of gastric neoplasms.

Acknowledgment

We thank Dr. F.G. Issa (Word-Medex, Sydney, Australia), for the careful reading and editing of the manuscript.

References

- 1) Marshall BJ. Unidentified curved bacilli on gastric epithelium in active chronic gastritis. *Lancet* i:1273-5, 1983
- 2) Isaacson PG, Wright DH. Extranodal malignant lymphoma arising from mucosa-associated lymphoid tissue. *Cancer* 53:2515-24, 1984
- 3) Asaka M. Helicobacter pylori infection and gastric cancer. *Dig Endosc* 7:345-9, 1995
- 4) Wotherspoon AC, Ortizhidalgo C, Falzon MR et al. Helicobacter pylori gastritis and primary B-cell gastric lymphoma. *Lancet* 339:1175-6, 1991
- 5) Wotherspoon AC, Dogliani C, Diss TC et al. Regression of primary low-grade B-cell lymphoma of mucosa-associated lymphoid tissue type after eradication of Helicobacter pylori. *Lancet* 342:575-7, 1993
- 6) Bayerdorffer E, Neubauer A, Rudolph B, Thiede C et al. Regression of primary gastric lymphoma of mucosa-associated lymphoid tissue type after cure of Helicobacter pylori infection. *Lancet* 345:1591-4, 1995
- 7) Voursden KH, Farrel PJ. Virus and cancer. *Br Med Bulle* 50: 560-81, 1994
- 8) Togawa K, Jaskiewicz K, Takahashi H, Metzger SJ, et al. Human papilloma DNA sequences in esophagus squamous cell carcinoma. *Gastroenterology* 107:128-36, 1994
- 9) Buke AP, Yen B, Shekitka KM, et al. Lymphoepithelial carcinoma of the stomach with Epstein-Barr virus demonstrated by polymerase chain reaction. *Mod Pathol* 3:377-80, 1990
- 10) Min KW, Hlmquist S, Peiper SC. Poorly differentiated adenocarcinoma with lymphoid stroma (lymphoepithelioma-like carcinoma) of the stomach; report of three cases with Epstein-Barr virus genome demonstrated by polymerase chain reaction. *Am J Clin Pathol* 96: 219-27, 1991

- 12) Niedobitek G, Herbst H, Young L, et al. Epstein-Barr virus and carcinomas; undifferentiated gastric carcinoma. *Diag Mole Pathol* 1:103-8, 1992
- 13) Shibata D, Weiss LM. Epstein-Barr virus associated gastric carcinoma. *Am J Pathol* 140:769-74, 1992
- 14) Tokunaga M, Land CE, Uemura Y, Tokudome T, Tanaka S, Sato E. Epstein-Barr virus in gastric carcinoma. *Am J Pathol* 143:1250-4, 1993
- 15) Leoncini L, Vindigni C, Megha T, Funto I, Pacenti L, et al. Epstein-Barr virus and gastric cancer: data and unanswered questions. *Intern J Cancer* 53:898-901, 1993
- 16) Qiang L, Ohshima K, Masuda Y, Kikuchi M. Detection of the Epstein-Barr virus in primary gastric lymphoma by in situ hybridization. *Pathol Intern* 45:131-6, 1995
- 17) Ott G, Kirchner TH, Seidl S, Muller-Hermelink HK. Primary gastric lymphoma is rarely associated with Epstein-Barr virus. *Virchows Archiv B cell Pathol* 64:287-91, 1993
- 18) Robbins SL, Angell M, Kumar. *Basic Pathology*. 4th ed. Neoplasia. Philadelphia: W.B. Saunders Company P.275-304
- 19) Morrow RH, Pike MC, Smith PG, et al. Burkitt's lymphoma: a time-space cluster of cases in Bwamba country of Uganda. *Br Med J* 2: 491-2, 1971
- 20) Jones EH, Biggar RJ, Nkrumah FK, Lawler SD. HLA-DR7 association with African Burkitt's lymphoma. *Human Immunol* 13:211-7, 1985