

— Case Report —

## Removal of Transvenous Pacemaker Electrodes under Cardiopulmonary Bypass

Eisuke KUSABA

Division of Emergency Medicine, Nagasaki University Hospital, Nagasaki, Japan

We report a patient in whom removal of transvenous pacemaker electrodes under cardiopulmonary bypass was successfully performed. The patient was a 75-year-old man who had undergone unsuccessful surgical treatments eight times followed by development of skin necrosis and wound dehiscence. The post operative course was uneventful. This procedure is safe and could be preferable in complex cases.

**Key words :** pacemaker electrode, cardiopulmonary bypass, immunological reaction to foreign body

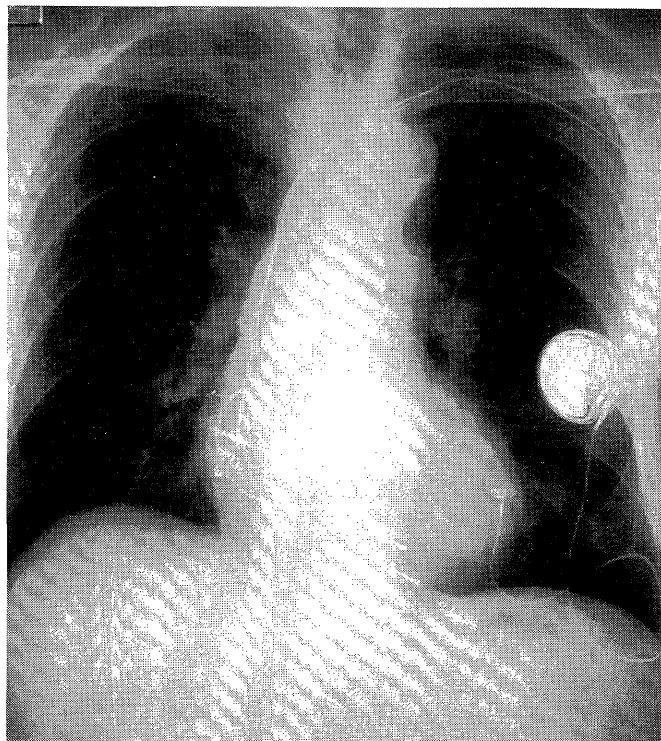
### Introduction

Cardiac pacemaker with transvenous electrode has been widely used with a low morbidity and mortality. Complications are rare<sup>1)</sup>, and mostly seen as skin necrosis around the implantation site with or without infection. Once this occurs, removal of the generator and electrode is usually necessary because these are foreign bodies to the recipient<sup>1)</sup>. However, removal is sometimes very difficult because the tip of the electrode is often fixed tightly to the myocardium. Moreover, the removal maneuver carries the risk of lethal complications<sup>1,3,5,9)</sup>. We report the successful removal of retained pacemaker electrodes under cardiopulmonary bypass (CPB) in a patient who had undergone eight unsuccessful operations before being referred to our clinic.

### Case Report

In January 1988, a 75-year-old Japanese male had a pacemaker generator with an transvenous electric lead implanted in his left anterior chest wall at another institute. Thereafter, further surgical procedures were performed eight times because of erosion or ulcer formation

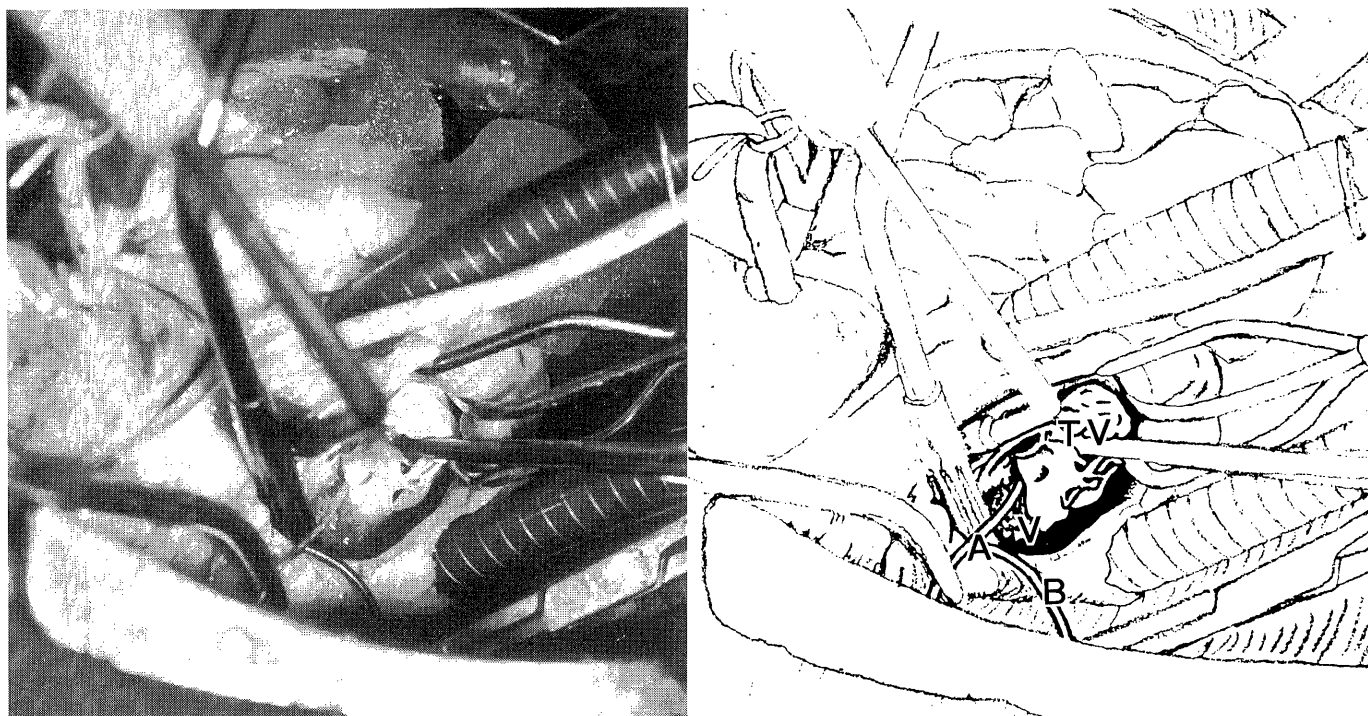
at the site of the generator or electrodes. The patient was transferred to our institution for treatment of a wound in the right anterior chest wall. Seventeen surgical scars could be seen on the anterior chest skin. The generator in the subcutaneous pocket at the anterior chest wall was removed, and a new generator (Intermedics S.A. NOVA 3. 282-07) was implanted in the left chest cavity with a myocardial electrode (Lifeline Myocardial Model 439-07) via left thoracotomy. Three transvenous leads were retained in the veins, one of the proximal ends of the electrode was in the right atrium and two were in the right ventricle. The wound in the front of the chest was well healed and fever had disappeared, when the patient was discharged on February 9, 1994. The patient was again admitted to our institute on July 4, 1994 for an opening in



**Fig. 1** Chest X-ray film demonstrated one atrial and two ventricular endocardial leads. The distal end of one lead floated in the SVC.

### Address Correspondence :

Dr. Kusaba, Division of Emergency Medicine,  
Nagasaki University Hospital, 1-7-1 Sakamoto, Nagasaki  
852-8501, Japan



**Fig. 2** One of the endocardial leads (A) fixed in the endocardium beneath the papillary muscle of the tricuspid valve (TV). Vegetation (V) was seen at the edge of the tricuspid valve where the lead was attached. Another lead was seen in the atrium (B). A and B, Electric lead. TV, Tricuspid valve. V, Vegetation.

the left anterior chest wall where one of the three leads was retained. Moreover, distal end of another lead had become detached and dropped from the fixation site into the superior vena cava (SVC) (Fig. 1). A fragment of the lead in SVC sometimes wandered into the right atrium and right ventricle causing arrhythmias. Body temperature ranged from 36.2°C to 38.5°C, C-reactive protein was positive, but there was no leucocytosis observed. Repeated cultures of blood and the wound secretions were all negative. Laboratory findings were as follows: hemoglobin 11.2 g/dl, white blood cell counts 6,300, C-reactive protein 3.30 (normal range < 0.31), Immunoglobulins were: IgG 3,055 (1,014-2,047), IgA 563 (133-443) and IgM 430 (58-245). CD4/CD8 3.7 (0.5-2.3).

### Surgical procedures

Through median sternotomy, aortic cannulation was made for arterial blood flow, followed by venous cannulation into the SVC and the inferior vena cava (IVC). CPB with mild hypothermia (32°C) was started. A tourniquet around the SVC was tightened quickly to prevent thrombi from flowing into the pulmonary artery. IVC tape was also tightened. The aorta was not cross-clamped initially, and the right ventricle was entered by atriotomy. Three leads were recognized in the cardiac cavity. One was removed from the appendage of the right atrium. Two other leads were seen in the right ventricle.

One was easily removed by simple pulling. The remaining one was tightly fixed to the right ventricular myocardium by tough encapsulating fibrous tissue, and the middle portion was attached to the septal leaflet of the tricuspid valve. Vegetation was seen at the edge of the tricuspid valve where the lead was attached, which was carefully removed. After these procedures, cardiac arrest was induced by aortic cross-clamping and infusion of normograde cold cardioplegia. The right ventricle was partially inverted, and the muscle was excised sharply along with fibrous tissues around the lead (Fig. 2). Weaning from CPB was easy, and the postoperative course was uneventful. Postoperatively, intravenous Piperacillin was administered for two weeks, followed by oral Cefdinir for two more weeks. The cultures of the tips of the leads were bacteriologically negative. Pathologic examination of the excised cardiac tissue around the electrode revealed slight lymphocyte infiltration and interstitial fibrosis, while subcutaneous tissue around the lead showed foreign body granuloma and abscess. Wound healing of the left anterior chest wall required more than three weeks. Body temperature normalized and postoperative laboratory findings were as follows: hemoglobin 12.4 g/dl, white blood cell count 4,400, C-reactive protein 1.1. Immunoglobulins were: IgG 3,040 IgA 542 and IgM 262. The patient was discharged on November 20, 1994 without any symptoms. When we saw him again on December 20, 1994, he remained asymptomatic.

## Discussion

Various techniques of removing retained endocardial pacemaker leads have been reported. They include continuous traction method<sup>2)</sup>, extraction with special tools<sup>3)</sup> and open heart surgery under CPB<sup>4,5,6)</sup> as well as other methods by which the electrodes are extracted from the surface of the ventricle without CPB<sup>7)</sup> or an inflow occlusion technique without CPB<sup>1,8)</sup>. Open heart surgery under CPB was preformed in this case. Various complications due to traction on leads have been reported including breakage of the retained lead<sup>8)</sup>, tearing of the subclavian vein, rupture of the tricuspid valve and rupture of the ventricular wall<sup>9)</sup>. Because these complications were fatal, all removal techniques without CPB should be avoided after one attempt at such technique has failed. Open heart surgery with CPB is the method of choice because of its safety in such difficult cases. Careful management should be required even under CPB, because mortalities were reported due to perforation of the ventricle or rupture of the subclavian vein<sup>1)</sup>.

Our current indication for CPB to remove a retained electrode are as follows: (1) Chronic inflammation sustained over a long period: The leads might be tightly fixed to the myocardium and should be removed under direct vision. (2) Broken proximal end floating in the SVC: There is a risk of thrombus formation and pulmonary embolism. Brodman et al<sup>11)</sup> showed that microscopic cracks in the external surface of the lead occur with bacterial colonization. From this perspective, bacterial infection could be confirmed based on his past history. Although fever persisted, white blood cell was normal and the cultures of the blood and wound secretion were all negative without antibiotics administration. The infection was not proven postoperatively. The pacemaker in the left chest cavity and myocardial lead are retained in the body postoperatively, but absolutely isolating it from the blood flow reduces the chance of infection.

Kikushima et al<sup>10)</sup> reported a case of pacemaker implantation with immunological reaction to a foreign body, in spite of proving no immunological abnormalities on the laboratory data. The reaction to foreign substances in our case was not proven by immunological examinations of the resected materials. But the inflammation was persistent and a foreign substance reaction would still be suspected postoperatively.

In summary, a case of removal of retained leads of cardiac pacemaker under CPB is reported. In selected circumstances this technique is considered to be safe and preferable to other techniques currently available.

## References

- 1) Brodman R, Frame R, Andrews C: Removal of infected transvenous leads requiring cardiopulmonary bypass or inflow occlusion. *J Thorac Cardiovasc Surg* 103: 649-54, 1992
- 2) Wallace HW, Sherfat M, Blakemore WS: The stubborn pacemaker catheter. *Surgery* 68: 914-915, 1970
- 3) Byrd CL, Schwarz SJ, Hedin N: Intravascular techniques for extraction of permanent pacemaker leads. *J Thorac Cardiovasc Surg* 101: 989-997, 1991
- 4) Yarnoz MD, Attai LA, Furman S: Infection of pacemaker electrode and removal with cardiopulmonary bypass. *J Thorac Cardiovasc Surg* 68: 43-46, 1974
- 5) Jarvinen A, Harjula A, Verkkala K: Intrathoracic surgery for retained endocardial electrodes. *Thorac Cardiovasc Surgeon* 34: 94-97, 1985
- 6) Ikeda K.: Retention of tined electrodes complicated by infection-A case report of its removal with total cardiopulmonary bypass. *Kyoubu Geka (Jpn J Thorac Surg)* 41: 838-840, 1988
- 7) Dubernet J, Irarrazaval MJ, Lema G: Surgical removal of entrapped endocardial leads without using extracorporeal circulation. *PACE* 8: 175-180, 1985
- 8) Aldrete V, Miller GE: Removal of infected transvenous pacemakers. *J Thorac Cardiovasc Surg* 107: 1164-1165, 1994
- 9) Garcia-jimenez A, Botana CM, Alba B: Myocardial rupture after pulling out a tined atrial electrode with continuous traction. *PACE* 15: 5-7, 1992
- 10) Kikushima S, Takei N, Kurano K: A case of pacemaker implantation with immunological foreign reaction. *Sinzou Pacing (Cardiac Pacing)* 4: 66-69, 1988