

— Case Report —

Fatal Asthma with Rhabdomyolysis Induced by Hair Dye

Chizu FUKUSHIMA¹⁾, Terufumi SHIMODA¹⁾, Hiroto MATSUSE¹⁾, Nobuko MATSUO¹⁾, Atsuko TAKAO¹⁾, Yasushi OBASE¹⁾, Shigeru KOHNO¹⁾, Sadahiro ASAI²⁾

1) Second Department of Internal Medicine, Nagasaki University School of Medicine

2) Department of Internal Medicine, Sasebo City General Hospital

Hair dyes have been reported to cause exacerbation of asthma in hairdressers through occupational exposure. We report a 54-year-old housewife who developed a fatal asthma attack following the use of a hair dye at home. She was admitted semiconscious with multiple organ failure. Laboratory findings were indicative of rhabdomyolysis. Skin prick and interdermal tests with hair dyes were performed. Hair dyes can be nonspecific stimuli that cause an asthma attack. But in our case, we cannot deny the possibility that the attack resulted from antigen-antibody reaction by the hair dye. We should warn that hair dyes can cause an asthma attack not only through occupational exposure but also through occasional domestic use.

Key words : fatal asthma, hair dyes, rhabdomyolysis

Introduction

Hair dyes are known to cause dermatitis in certain individuals^{1,2)}. However, asthmatic attacks induced by hair dyes have rarely been reported, and most of them occurred following occupational exposure³⁻⁶⁾. We describe here a patient who developed acute an exacerbation of asthma after domestic use of a hair dye. The clinical course was complicated by the development of rhabdomyolysis which led to death.

Case Report

A 54-year-old housewife was admitted to our hospital because of impairment of consciousness. She had been followed up at the outpatient clinic because of a moderately severe bronchial asthma of the atopic type and systemic hypertension. The onset of asthma was at 29 years of age. She was under treatment with theophylline (400 mg twice a day), BDI (800 μ g 4 times a day), salbut-

amol sulfate inhaler (used when required) for bronchial asthma, and a slow release preparation of nifedipine for hypertension. Her pulmonary function in a stable state was as follows : VC 2.39L, FEV₁₀ 1.26L, PEF 4.61L/sec. The past history revealed that the patient developed a minor attack of asthma while dying her hair on December 2, 1992. The attack was associated with skin rashes on the forearms and erythema on the scalp. In 1993, the patient experienced two minor attacks of asthma while dying her hair. In the latter two instances, the acute exacerbation of asthma was treated effectively by inhalation of a β_2 adrenergic agonist. On August 5, 1993, the patient developed an upper respiratory infection. Two days later, she started wheezing in the morning while using a hair dye in the bathroom and became unconscious within few minutes. She could not reach her medication when the asthmatic attack occurred. The same hair dye was used by the patient in all episodes of asthma attacks. History provided by family members indicated that she had taken her medication that morning as usual. Cardiopulmonary arrest occurred while she was being transported in an ambulance, but the patient was successfully resuscitated by a local physician.

On admission, consciousness was determined to be of level 3, according to the Glasgow Coma Scale. Blood pressure was 190/100 mmHg, with heart rate of 130 beats/min. and irregular breathing pattern. The pupils were constricted, but no anisocoria was noted. Heart and breathing sounds were normal. The patient was not edematous, and the abdomen was soft. Neurological examination revealed that the deep tendon reflexes were slightly attenuated. Although pathological reflexes were not elicited, the patient showed involuntary movements.

The results of laboratory examination revealed elevation of the hepatic, pancreatic, and renal enzymes, as well as increased blood levels of CPK, uric acid, and blood glucose. Urinalysis revealed microhematuria (Table 1). The skin tests for allergen were performed 5 years before admission to the hospital (Table 2). The chest roentgenogram obtained on admission was normal. Since the patient was known to be hypertensive, a differential diagnosis of an acute cerebrovascular accident was also considered, but

Address Correspondence :

Dr. Chizu Fukushima, Second Department of Internal Medicine, Nagasaki University School of Medicine, 1-7-1 Sakamoto, Nagasaki 852-8501, Japan

Table 1. Laboratory finding on admission

Hamatology	Biochemistry	Serology	Urinalysis	Blood Gases	
RBC429x10 ⁴ /mm ³	T-Bil 0.5 mg/dl	Amyl 4380 IU/l	CRP 3.62 mg/dl	appearance yellow	pH 7.370
WBC16700/mm ³	AST 246 IU/l	BUN 61 mg/dl	protein (-)	glucose (-)	PaO ₂ 123.2 mmHg
Plt 12.1x10 ⁴ /mm ³	ALT 33 IU/l	Cr 6.1 mg/dl	occult blood (+++)		PaCO ₂ 49.3 mmHg
	ALP 214 IU/l	U.A. 14.7 mg/dl			HCO ₃ 28.1 mEq/l
	LDH 1266 IU/l	B.S. 268 mg/dl			(O ₂ l nasal)
	CPK 12500 IU/l				

AST : aspartate aminotransferase ALT : alanine aminotransferase U.A.: uric acid B.S.: blood sugar

Table 2. Allergen tests of the patient

IgE IU/ml	IgE-RAST	Positive intradermal tests out of 41 performed
290	candida class 2	house dust, mites, silk
	house dust class 5	buckwheat, tatami, candida
	mites class 5	buckwheat flour

These tests occurred 5 years prior to admission. Positive results are noted above.

the results of a brain CT scan disclosed no abnormal findings.

The patient was treated with mechanical ventilation, and an arterial line was prepared. Steroids, theophylline and cephalosporin were administered on admission. Serum theophylline levels were maintained within 15 μg/ml. The clinical course of the patient is shown in Figure 1. The body temperature fluctuated between 35° and 40°C. Macrohematuria was noted on the night of admission,

after which the urinary output became markedly reduced. Progressive elevation of BUN and creatinine was noted. Because of the deteriorating renal function, the hemofiltration was instituted on a daily basis. However, the renal function further deteriorated, and the hepatic, pancreatic, and renal enzymes were also elevated, indicating the development of multiple organ failure. LDH and CPK were markedly elevated. Among the LDH isoenzymes, LDH5 was elevated, MM CPK isoenzyme was 98% and the

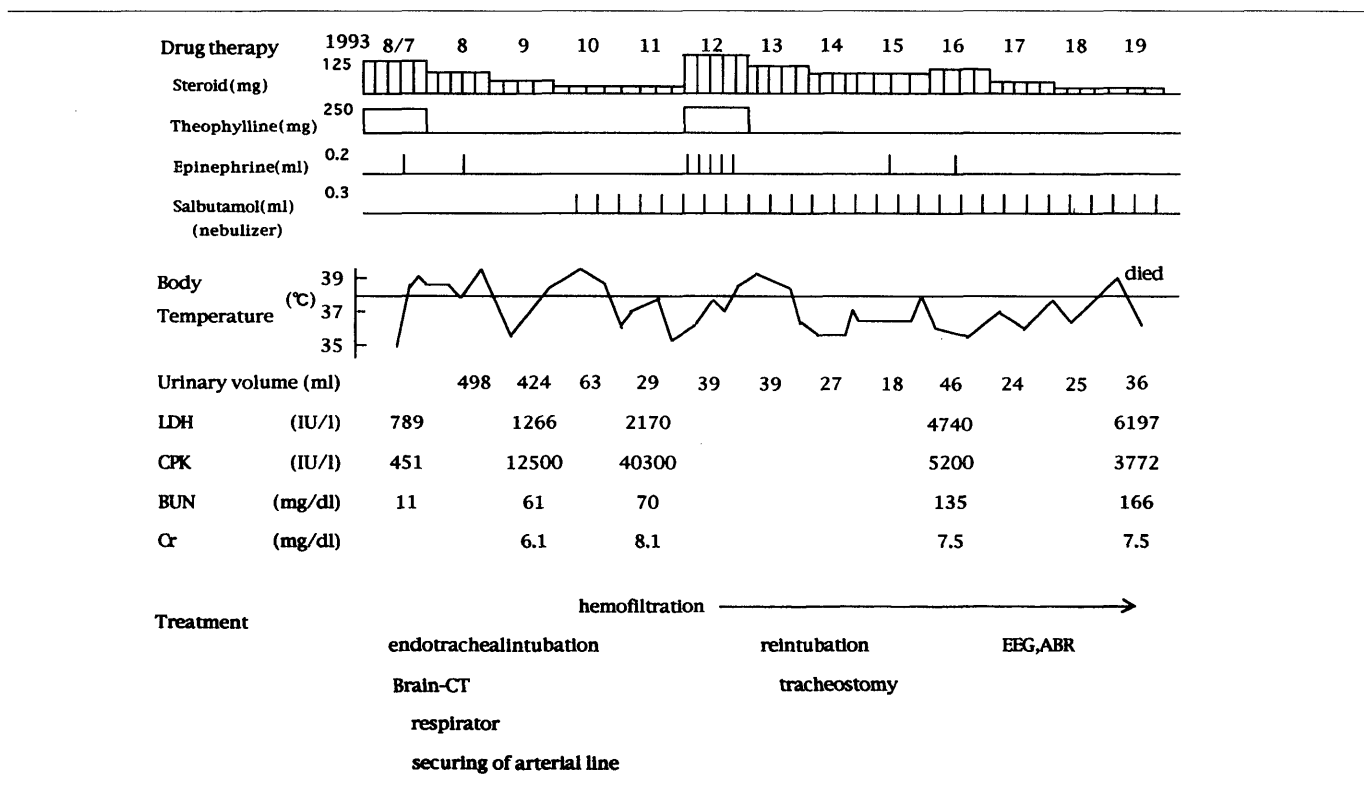


Figure 1. Clinical course of the present case

Table 3. Ingredients of the hair dye used by our patient

Color	Oxidizing compound		
oxidizing color	paraphenylendiamine	oxidizing agent	hydrogen peroxide (5.8%)
	methaphenylene hydrochloride	base	cetanol etc.
	meta-aminophenol	anionic surface active agent	polyoxyethylene ularyl ether sulfates etc.
	resorcin etc.		
alkaline agents	monoethanolamine	hair protective agent	reducedlanolin
cationic surface active agent	cetyltrimethylammonium chloride		
hair softener	distearyl dimethyl ammoniumchloride		
moistener	propylene glycol etc.		
metallic mounting medium	dedtate		
anti-oxidizing agent	thioglycolicacid		
stablizer (bactericide, preservatives)	benzoate		

Table 4. The results of skin prick and intradermal tests involving hair dyes

Agntigen	Skin Prick Test		Intradermal Test	
	Patient	Patient	Healthy Asult	Patient with Bronchial Asthma
1 Color	(-)	(-)	$\frac{7 \times 5}{12 \times 10}$	(-)
2 Oxidizing compound	(-)	(-)	$\frac{10 \times 7}{25 \times 18}$	$\frac{7 \times 5}{7 \times 5}$
3 Color+ Oxidizing compound	(-)	(-)	$\frac{6 \times 5}{20 \times 18}$	$\frac{7 \times 6}{7 \times 6}$
4 Serum		(-)	(-)	(-)
5 Serum+Color		(-)	$\frac{5 \times 5}{10 \times 8}$	(-)
6 Serum+ Oxidizing compound		$\frac{10 \times 7}{13 \times 10}$	$\frac{7 \times 4}{20 \times 20}$	(-)
7 Serum+Color+ Oxidizing compound		$\frac{4 \times 3}{6 \times 4}$	$\frac{9 \times 8}{12 \times 10}$	$\frac{4 \times 3}{4 \times 3}$

$\frac{\text{wheal(mm)}}{\text{flare(mm)}}$ (-) : negative

myoglobin increased to over 500 ng/ml. Serum calcium was reduced to 5.7 mg/dl. These laboratory findings suggested a diagnosis of rhabdomyolysis. Tracheotomy was performed 5 days after admission. Hypotension, recurrent wheezing and increased airway pressure developed and was followed by cessation of spontaneous ventilation. The administration of epinephrine, salbutamol sulfate, steroids, and theophylline preparations resulted in a transient improvement of the respiratory status. However, renal function continued to deteriorate, with progressive elevation of serum potassium concentration. The patient died on August 19. A postmortem examination was not done.

Allergy tests

The hair dye preparation used by the patient consisted of color and oxidation compounds (Table 3). The two components were to be mixed before use. The intracutaneous and skin prick tests were performed 8 days after admission. One milliliter of the color and oxidation components as well as a sample of their mixture were each dissolved in 3 ml of physiological saline. Results of the skin tests were read 15 minutes after the application of antigenic substances. Wheal-and-flare reactions were noted after application of each component of the dye as well as after

application of the patient serum. The latter was performed since the hair dye can act as a hapten. Furthermore, the wheal-and-flare reactions developed after performing the same tests in a group of patients with asthma and healthy adults, but no relationship was found between the application of the antigenic substance (oxidation) and the cutaneous reaction (Table 4).

Discussion

The clinical course in our patient consisted of a fatal asthma attack following the use of a hair dye and was complicated by rhabdomyolysis.

Cutaneous reactions, such as dermatitis and urticaria, caused by dyes are widely known. However, only a few reports of bronchial asthma have been reported following the use of dyes³⁻⁸⁾. In those reports, acute exacerbation of asthma was provoked following inhalation of the vapor of hair dye mixtures. The subjects were all professional hairdressers who had been continuously exposed to hair dyes for long periods in their work environment. In contrast, our patient was a housewife who only used the hair dye once every few months. In addition to the fatal episode, she had also experienced minor exacerbation of asthma after the use of the hair dye between 1992 and 1993. Wheal-and-flares accompanied these minor asthma attacks. The antedate evidence and history of illness provided by the family members suggested that the present wheezing episode was also due to the use of the same hair dye. The exact time elapsed between its use and the onset of fatal asthma attack could not, however, be determined.

Volatile antigenic substances are components of hair dyes. These substances probably entered the airways and triggered an asthma attack in our patient. Asthma attacks due to persulfate^{3,4)}, henna⁵⁾, reactive dye (black B, GR, orange 3R)^{6,7)}, and carmine⁸⁾ have been reported. These causative agents do not only produce local cutaneous reactions, but also cause generalized urticaria, rhinitis, bronchial asthma, and syncope. As shown in Table 3, the sulfates, benzoate, and various dye substances were ingredients of the hair dye used by our patient. One or more of these ingredients may have contributed to the development of asthma attack.

Various mechanisms, including allergic or nonspecific stimulation, have been proposed by different investigators to explain the pathogenesis of the asthma attacks⁶⁻⁸⁾. The results of patch and intradermal tests in these reports also vary among investigators^{3-5,6,8)}. We used some antigenic samples in our intradermal tests. Of them, only those containing a combination of oxidizing compound and patient serum caused positive wheal-and-flare reactions. When tested alone, the oxidizing compound produced negative results. Based on this observation, we speculate that oxidation compound served as a hapten in the

development of allergic reactions in our patient, although it was a borderline reaction. However, the other asthma patients and healthy adults showed positive wheal-and-flare reactions to the oxidizing compound. Steroid treatment may have influenced the results of the test in our patient. Therefore, no conclusion could be made with regard to the role of oxidizing compound in the development of asthma attacks. In many cases, asthma attacks were due to nonspecific stimulation by hair dyes. But in our patient, it is possible that the acute exacerbation of asthma was due to antigen-antibody reaction by oxidizing compound.

A review of the literature revealed that specific IgE antibodies were detected in a portion of the reported cases^{6,8)}. This indicates that asthmatic attacks were due to antigen-antibody reactions in at least a few of the reported patients. Laboratory tests other than intradermal tests had not been performed in our case because the patient died relatively soon after the onset of the attack. Parsons et al⁹⁾ reported that persulfate may directly enhance the release of histamine. We believe that further clinical experience is necessary to elucidate the mechanisms provoking such asthma attacks. Unlike the previous minor asthma attacks, the present episode of wheezing and dyspnea proved to be fatal. This may have been due to a greater hypersensitivity of the airways, caused by the upper respiratory tract infection a few days before the asthma attack.

Rhabdomyolysis is most likely to occur following traumatic episodes, although the condition has also been reported to occur after heavy exercise, fever, convulsions and administration of certain drugs¹⁰⁾. Rhabdomyolysis has also been reported in a few patients with asthma¹¹⁻¹³⁾. The causative agents in those cases included steroids, theophylline preparations, and β adrenergic agonists. Although urinary myoglobin was not measured in our patient, the marked increase in the severity of hematuria, CPK, LDH, BUN, creatinine, and blood myoglobin, as well as a reduced serum calcium strongly suggested rhabdomyolysis. Since abnormal laboratory values were already present on admission, it is probable that rhabdomyolysis occurred as a result of the asthma attack or the associated upper respiratory infection. Because of the risk of the extreme fluctuations in blood pressure from institution of hemodialysis, we selected treatment by hemofiltration starting on the third day of admission. The effect of this mode of therapy was, however, less than satisfactory probably due to the recurrent wheezing and influence of administered drugs.

Our patient had previously experienced several episodes of asthma attacks after the use of the same hair dye. She was constantly cautioned by her family physician regarding the detrimental effects of hair dyes on asthma, but she refused the advice. The previous asthma attacks were successfully controlled by the administration of β 2

adrenergic agonists. Because of this, both the patient and we may have underestimated the real danger of hair dyes. The present case provides a clear message with regard to the fundamental principles of treatment for asthma. These principles consist of avoidance of factors that may induce an asthma attack, and the importance of education and instruction of patients with regard to the nature of asthma. We should warn that hair dyes can cause an asthma attack not only through occupational exposure but also through occasional domestic use.

References

- 1) Calnan CD, Shuster S: Reactions to ammonium persulfate. *Arch Dermatol* 88 : 812-15, 1963
- 2) Rook A, Wilkinson D, Ebling F : *Textbook of Dermatology*, Edition 2. Philadelphia : FA Davis Company, 1968, p.1418.
- 3) Blainey AD, Ollier S, Cundell D, Smith RE, Davies RJ : Occupational asthma in a hairdressing salon. *Thorax* 41 : 42-50, 1986
- 4) Fisher AA : The Persulfates : A Triple Threat. *Cutis* June : 520-25, 1985
- 5) Starr JC, Yunginger J, Brahser GW : Immediate type 1 asthmatic response to henna following occupational exposure in hairdressers. *Annals of Allergy* 48 : 98-9, 1982
- 6) Park HS, Lee MK, Kim BO, et al : Clinical and immunologic evaluations of reactive dye-exposed workers. *J Allergy Clin Immunol* 87 : 639-49, 1991
- 7) A Wass U, Nilsson R, Nordlinder R, Belin L : An optimized assay of specific IgE antibodies to reactive dyes and studies of immunologic responses in exposed workers. *J Allergy Clin Immunol* 85 : 642-8, 1990
- 8) Quirce S, Cuevas M, Olaguibel JM, Tabar AI : Occupational asthma and immunologic responses induced by inhaled carmine among employees at a factory making natural dyes. *J Allergy Clin Immunol* 93 : 44-52, 1994
- 9) Parsons JF, Goodwin BJF, Safford RJ : Studies on the action of histamine release by persulfates. *Food Cosmet Toxicol* 17 : 129-35, 1979
- 10) Gabow PA, Kaehny WD, Kelleher SP : The spectrum of rhabdomyolysis. *Medicine* 61 : 141-52, 1982
- 11) Barrett SA, Mourani S, Villareal CA, Gonzales JM, Zimmerman JL : Rhabdomyolysis associated with status asthmaticus. *Crit Care Med* 21 : 151-3, 1993
- 12) Chugh KS, Singhal PC, Khatri GK : Rhabdomyolysis and renal failure following status asthmaticus. *Chest* 73 : 879-80, 1978
- 13) Williams TJ, O'hehir RE, Czarny D, Horne M, Bowes G : Acute myopathy in severe acute asthma treated with intravenously administered corticosteroids. *Am Rev Respir Dis* 137 : 460-3, 1988