

## Local Recurrence in the Pectoralis Major Muscle Following Modified Radical Mastectomy for Breast Cancer

Hiroyoshi AYABE, Shinsuke HARA, Noriaki ITOYANAGI, Tadayuki OKA,  
Takeshi NAGAYASU, Shinji AKAMINE, Takaro TAKAHASHI, Tohru NAKAGOE

First Department of Surgery, Nagasaki University School of Medicine

Local recurrence in the pectoralis muscle after modified radical mastectomy for breast cancer is rare. We encountered a 53-year-old woman who developed a small nodule on her right antero-lateral chest wall after modified radical mastectomy. Excision biopsy of the mass lesion was performed, and pathological examination revealed a local recurrence in the pectoralis major muscle. Resection of the pectoralis major and minor muscles, subclavicular lymph nodes dissection and postoperative radiation therapy were performed. After operation, no local recurrence appeared, but the patient died of multiple liver and bone metastases two and a half years later.

---

**Key words :** breast cancer, modified radical mastectomy, local recurrence, pectoralis muscle

### Introduction

At present, modified radical mastectomy preserving the pectoralis muscles is most frequently performed for patients with operable breast cancer<sup>1-3</sup>. Local recurrence after modified radical mastectomy has been reported at levels ranging from 3.5% to 18.1%, depending on the tumor size and presence of metastatic lymph nodes<sup>3-5</sup>. The rate of local recurrence has been increasing in patients with large primary tumors and positive metastatic axillary lymph nodes<sup>6</sup>. Local recurrences are frequent in the skin, subcutaneous tissue or lymph nodes. However, local recurrence in the pectoralis muscle is rare. We present a case with solitary local recurrence in the pectoralis major muscle after modified radical mastectomy.

### Case Report

The patient was a 53-year-old woman. She was admitted to our hospital with an axillary mass. Physical examination revealed a hard mass, 2 x 1.5 cm, in the right axillary fossa. There was no right breast mass or cervical lymph node swelling. Excisional biopsy of the axillary mass lesion revealed a metastatic adenocarcinoma. Mammo-

graphy showed multiple microcalcifications in the upper-lateral quadrant of the patient's right breast. The mammographic findings confirmed that the lesion was an infiltrating carcinoma of the breast. The patient's general condition was good, and no blood-borne metastases in the lung, bone, or liver were found. Modified radical mastectomy preserving the major and minor pectoralis muscles was performed. The patient's postoperative course was uneventful. Microscopic examination revealed an invasive ductal carcinoma (papillo-tubular type) and axillary node metastasis (n1a 4/5, n1b 2/5). She received two courses of chemo-endocrine therapy consisting of 100 mg Cyclophosphamide, 500 mg 5-Fluorouracil, 30 mg Adriamycin and 20 mg Tamoxifen.

Six months later, a small nodule, 3 x 3 mm in size, was palpated near the lateral border of the major pectoralis muscle in her right antero-lateral chest wall. The nodule was elastic hard, had a smooth surface, a clear border and was slightly fixed to the base. An excision biopsy was performed under local anesthesia. The mass was in the major pectoralis muscle and was excised with partial resection of this muscle (Fig. 1). The histological features of the mass were similar to that of the previously resected breast cancer, and it was diagnosed as metastatic breast cancer (Fig. 2). There was no lymph node structure in the mass. No other metastatic lesions were found, so total removal of the major and minor pectoralis muscles and subclavicular lymph nodes dissection were performed. Histo-pathological examinations of the resected specimens showed no remnant carcinoma in the pectoralis muscles or dissected lymph nodes. The patient received endocrine therapy with 20 mg/day Tamoxifen and postoperative radiation in the right anterior chest wall and was discharged. Two years and 6 months after the second operation, she died of multiple liver and bone metastases. Postmortem examination revealed no local recurrence on the right chest wall.

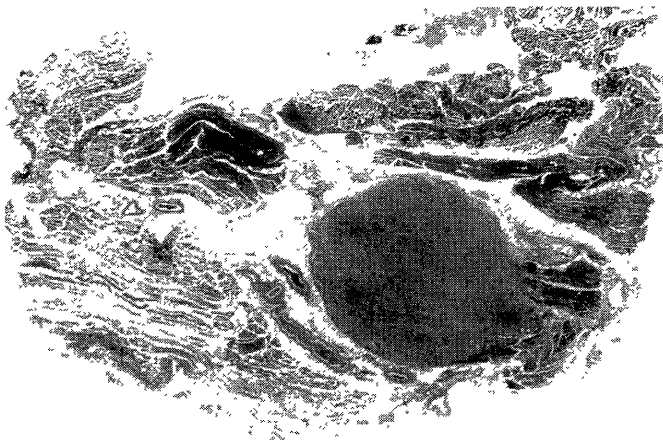


Fig. 1 Histopathological picture of the specimen resected by excisional biopsy shows the recurrent tumor in the pectoralis muscle. The metastatic tumor was solitary and partially invaded the muscle (H & E stain, x 12.5).

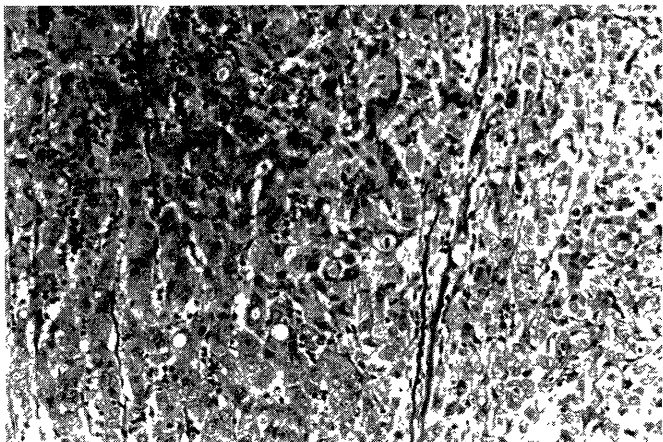


Fig. 2 Histopathological picture of the specimen shows invasive ductal carcinoma (H & E stain, x 200).

## Discussion

The sites of local recurrence after muscle-preserving mastectomy are the intradermal layer, the subcutaneous layer, intra-muscular or inter-muscular regions, and the axillary, subclavicular or parasternal lymph nodes<sup>9</sup>. Causes of chest wall local recurrence after modified radical mastectomy for breast cancer are 1) incomplete excision of breast cancer, 2) implantation at operation of emboli dislodged from cut vessels or lymphatics or contaminated instruments after cutting through, 3) retrograde dissemination, and 4) a micro-cancerous focus in small lymphatic channels in the pectoralis muscles<sup>3,7</sup>.

It is quite rare that cancerous lesions are found in the resected pectoralis muscles after standard radical mastectomy. In addition, the pectoral fascia is relatively free of lymphatic channels and so is an unlikely route for the spread of cancers<sup>10</sup>. As a result of these findings, Patey

and Dyson<sup>10</sup> devised an operative procedure leaving the pectoralis major muscle intact, but removing the breast and axillary nodes.

Local recurrence in the pectoralis muscles after modified mastectomy for breast cancer is also rare. The incidence of intramuscular recurrence after modified radical mastectomy was from 0.7% to 1.2% in the reported series<sup>3,7-9</sup>. Kodama et al<sup>9</sup> reported 16 cases of local recurrence in the pectoralis muscles among 1,408 cases of modified radical mastectomy for breast cancer. Causes of local recurrence in the pectoralis muscle following modified radical mastectomy are 1) interstitial spread where isolated tumor cells have followed perivascular or perineural spaces or have passed along the fascial septa to lodge in the muscles, or 2) systemic disseminations<sup>9</sup>. Our case had a solitary recurrent tumor, suggesting remaining cancer after surgery, but the possibility of features of systemic metastasis cannot be ruled out because of the later development of liver and bone metastasis. The recurrent tumors were within the pectoralis muscles and tended to be lateral to the midclavicular line. Most cases of recurrence in the pectoralis muscle appeared within 3 years of surgery, but a case with local intramuscular recurrence 13 years after mastectomy has been reported<sup>9</sup>. Treatment of patients with intra-muscular recurrence has usually involved wide resection of the pectoralis muscle, the subcutaneous tissue, and the skin or complete resection of the pectoralis muscles with or without radiotherapy, depending on the extent of recurrent tumors and axillary or subclavicular lymph node metastasis. Two-thirds of the cases with solitary recurrence in the pectoralis muscle after operation had a good prognosis<sup>9</sup>. However, the prognosis for the patients with axillary lymph node metastasis at primary mastectomy or with a short interval between mastectomy and appearance of local recurrence was poor<sup>7</sup>. For the latter cases, systemic chemo-endocrine therapy should normally be given, because other metastatic lesions in distant organs have appeared in many cases.

In view of our experiences and those of others, for breast cancer with apparent metastatic axillary lymph nodes, post-operative radiation therapy after modified radical mastectomy or standard radical mastectomy removing the major and minor pectoralis muscles is the best course of action.

## References

- 1) Nemoto T, Vana J, Bedwani RN, et al : Management and survival of female breast cancer: results of a national survey by the American College of Surgeons. *Cancer* 45 : 2917-2924, 1980
- 2) Japanese Breast Cancer Society. Types of operation for breast cancer: results of a national survey by Japanese Breast Cancer Society. *Reports II* : 340-345, 1992 (Japanese)
- 3) Kodama H. Modified radical mastectomy (Kodama's operation) — results of 1,408 cases. *J Clin Surg* 49 : 49-54, 1994 (Japanese).
- 4) Nakamura Y, Watanabe H, Hino S, et al : Limited surgery for breast

cancer : its indication and recurrence. J Jpn Soc Clin Surg 43 : 731-734, 1982 (Japanese)

- 5) Baker RR, Albert CW, Montage JN, et al : A comparison of modified radical mastectomy to radical mastectomy in the treatment of operable breast cancer. Ann Surg 189 : 553-559, 1979
- 6) Maddox WA, Carpenter JT Jr, Laws HL, et al : A randomized prospective trial of radical (Halsted) mastectomy versus modified radical mastectomy in 311 breast cancer patients. Ann Surg 198 : 207-212, 1983
- 7) Ishida H, Tatsuta M, Kawasaki T, et al : Two cases of solitary metastasis to the pectoralis major muscle following modified radical mastectomy. Jpn J Breast Cancer 12 : 403-407, 1997 (Japanese)
- 8) Takahashi I, Hayashi k : Clinical study for recurrence after limited surgery for breast cancer. Surg Therapy 62 : 409-416, 1990 (Japanese)
- 9) Scanlon EF : Local recurrence in the pectoralis muscles following modified radical mastectomy for carcinoma. J Surg Oncol 30 : 149-151, 1985
- 10) Patey DH, Dyson WH : The prognosis of carcinoma of the breast in relation to the type of operation performed. Br J Cancer 2 : 7-13, 1948