

Primary Malignant Lymphomas Arising from the Ileum and the Ampulla of Vater: Report of a Case

Shigetoshi MATSUO¹⁾, Takuo SHINOZAKI¹⁾, Hitoshi OHKUBO¹⁾, Satoshi YAMAGUCHI¹⁾, Masaki YAMAKAWA²⁾, Mamiko SAITOH²⁾, Takashi KANEMATSU³⁾

1) Department of Surgery, Nagasaki Prefectural Shimabara Onsen Hospital, 7895 Shimokawajiri, Shimabara 855, Japan

2) Department of Internal Medicine, Nagasaki Prefectural Shimabara Onsen Hospital, 7895 Shimokawajiri, Shimabara 855, Japan

3) Second Department of Surgery, Nagasaki University School of Medicine, 1-7-1 Sakamoto, Nagasaki 852, Japan

A 71-year-old man was admitted with complaints of right lower quadrant pain and abdominal fullness. Barium enema and computed tomography (CT) scan demonstrated a tumor in the terminal ileum. There was no enlargement of superficial lymph nodes. Colonofiberscopy revealed a narrowing of the terminal ileum and biopsy specimens showed evidence of B-cell lymphoma. Laparotomy was performed in view of the small bowel obstruction. An elastic firm tumor, measuring 5.2 by 4.5 cm, was found in the terminal ileum, and the regional mesenteric nodes were enlarged. Ileo-cecal resection with dissection of lymph nodes was performed. The resected specimen revealed a diffuse, B-cell lymphoma with IgM heavy-chain and kappa light-chain restrictions. The patient developed obstructive jaundice 2 weeks after surgery, and CT scan demonstrated tumor in the ampullary region of the duodenum. Endoscopic examination showed an ulcerated tumor in the ampulla of Vater and biopsy specimen again showed B-cell lymphoma. Chemotherapy with cyclophosphamide, prednisolone, adriamycin and vincristine was effective and complete remission was achieved. To our knowledge, this is the first case of simultaneous occurrence of malignant lymphomas in the ileum and the ampulla of Vater.

Key words ; malignant lymphoma, ileum, ampulla of Vater

Introduction

It can be difficult to distinguish primary gut lymphoma from secondary lymphoma accompanying advanced disease. Dawson et al¹⁾ proposed intestinal lymphoma as the primary lesion in cases in which ; 1) there is no palpable enlargement of superficial lymph nodes and no visible mediastinal lymph nodes ; 2) the total and differential white blood cell counts are within normal limits ; 3) bowel involvement is predominant with nodal involvement confined to the regional nodes ; and 4) there is no hepatic or splenic involvement. Primary malignant lymphoma of the alimentary tract is found most commonly in the stomach. The frequency of small bowel lymphoma is

second among lymphomas of the gastrointestinal tract²⁻⁴⁾. Primary malignant lymphoma of the ampulla of Vater is extremely rare⁵⁾, although lymphomatous compression of the biliary tree has been reported in 1.2% to 5% of cases of non-Hodgkin's lymphoma as a terminal event in high-grade and late-stage disease⁶⁻⁹⁾.

We report herein a rare case of primary lymphoma arising simultaneously from the ileum and the ampulla of Vater and presenting with both small bowel obstruction and obstructive jaundice. Complete remission was achieved after surgical resection of the ileal lymphoma followed by combination chemotherapy.

Case report

A 71-year-old man was admitted to Nagasaki Prefectural Shimabara Onsen Hospital on July 9, 1994 after an episode of nausea, abdominal fullness and right lower quadrant pain of 2 month' duration. On physical examination, mild tenderness and guarding were observed in the right lower quadrant. Bowel sounds were slightly increased. Neither an abdominal tumor nor superficial lymph nodes were palpable. The complete blood count showed that white blood cells were 7800/mm³ without abnormality, red blood cells 382×10⁴/mm³ and hemoglobin level 10.8 g/ml. Except for an elevation of C-reactive protein at 23.4 mg/dl (normal range ; 0-1.2), the blood chemistry and electrolytes were normal. Barium enema revealed a narrowing of a 5-cm section of the terminal ileum (Fig. 1). A computed tomography (CT) scan demonstrated thickening of the wall of the terminal ileum and enlarged mesenteric lymph nodes (Fig. 2). A colonofiberscopy showed stenosis of the terminal ileum. Biopsy specimens showed evidence of diffuse proliferation of abnormal mononuclear cells without staining for mucin. Immunohistochemically, these cells showed positive staining for B lymphocytes by the avidin-biotin complex method. The findings were consistent with diagnosis of B-cell lymphoma.

Since the patient had small bowel obstruction, he was considered a candidate for surgery and underwent an operation on July 21, 1994. No abnormal findings were noted in the liver or spleen at surgery. An elastic firm mass, measuring 5.2 by 4.5 cm, was found in the terminal ileum. The regional mesenteric lymph nodes were enlarged. There were no multiple lesions at sites other than the small intestine. Ileo-cecal resection with dissection of lymph nodes was performed. Histological study showed a diffuse, medium-sized, B-cell lymphoma with restrictions of the IgM heavy-chain and kappa light-chain (Fig. 3).

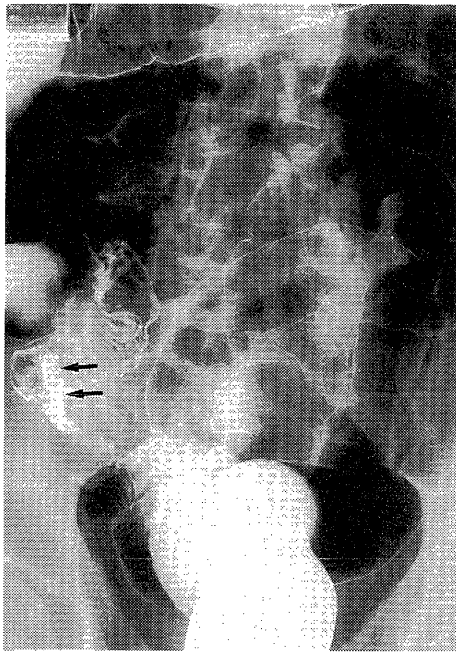


Fig. 1 Barium enema reveals narrowing of the terminal ileum (arrows).

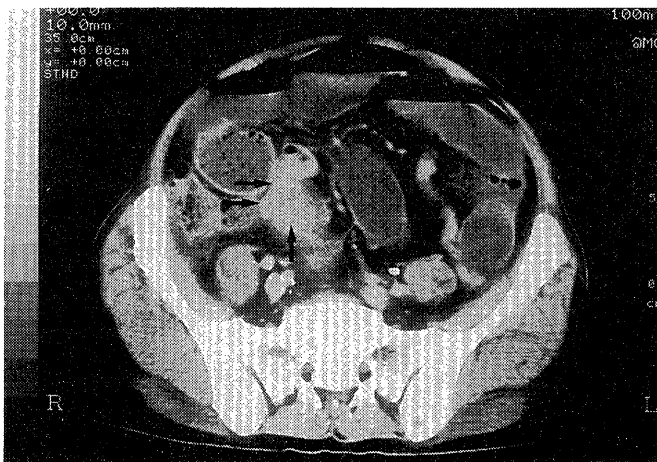
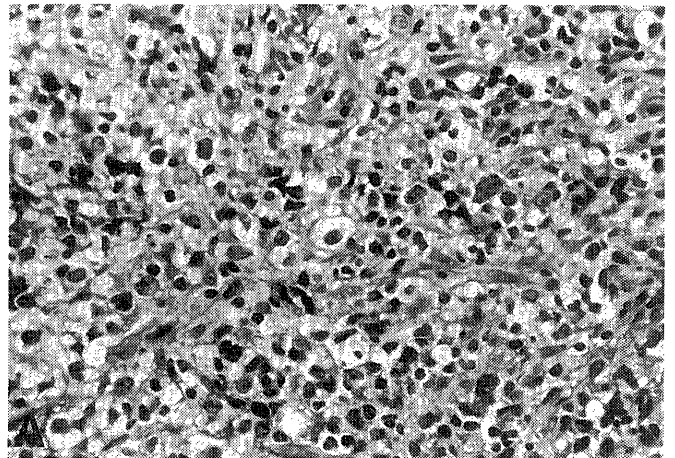
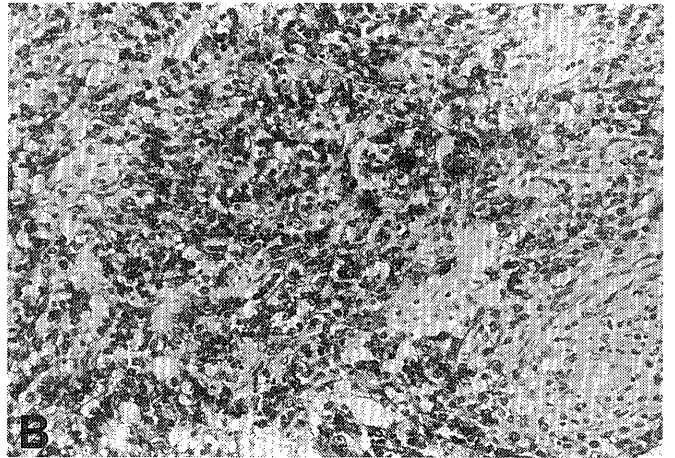


Fig. 2 A CT scan demonstrates thickening of the wall of the terminal ileum (arrows). Note the dilatation of the small bowel.



A



B

Fig. 3 Resected specimens of the ileal tumor are diagnosed as B-cell malignant lymphoma.

A : H. E. stain(x400 original magnification),

B : Immunohistochemical staining for B cell (anti-B lymphocyte antibody ; L26, DAKO, x200 original magnification).

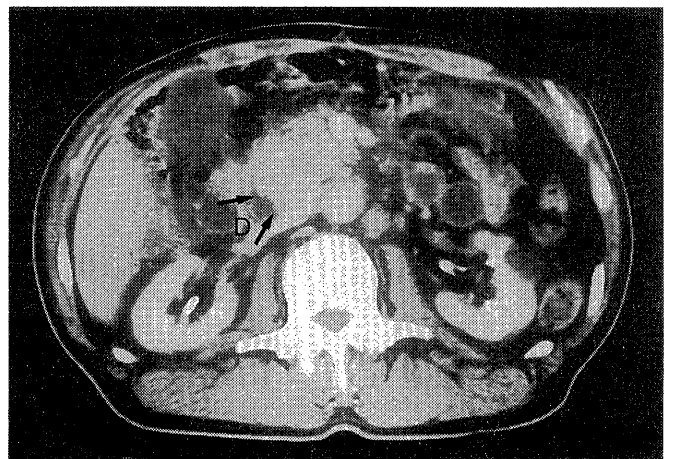


Fig. 4 CT scan demonstrates a tumor of the ampullary region (arrows). D : second portion of the duodenum.

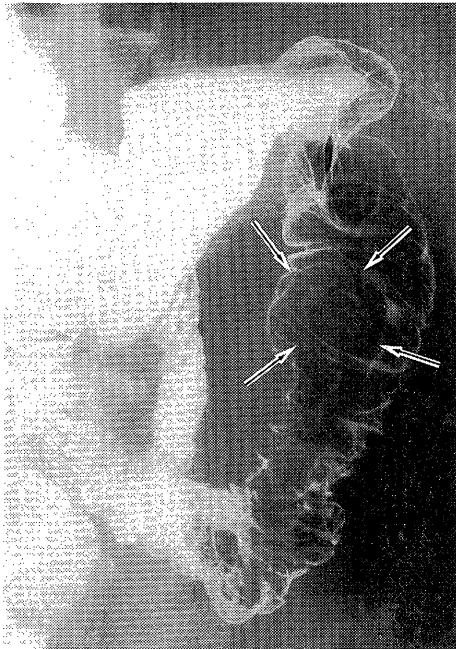


Fig. 5 Hypotonic duodenography reveals a well-defined tumor in the second portion (arrows).

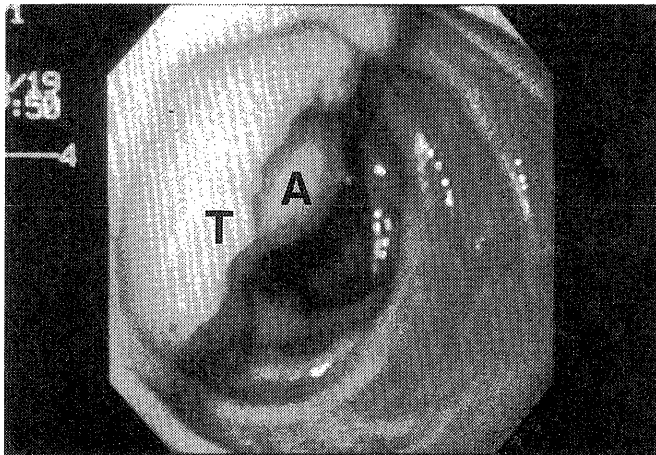
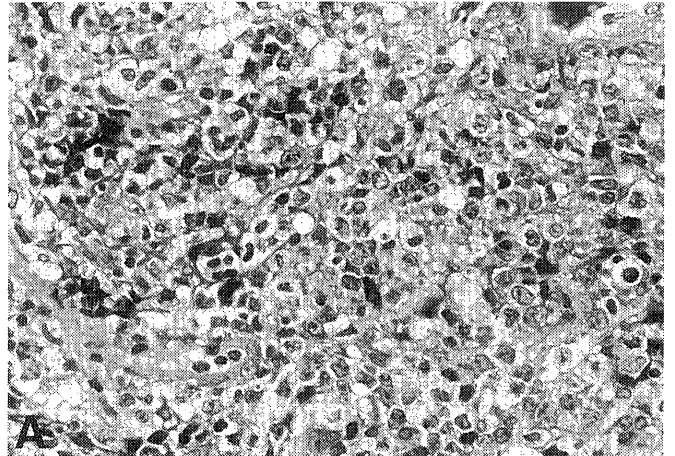



Fig. 6 Endoscopy reveals an ulcerated tumor (T) in the second portion of the duodenum. The ampulla of Vater (A) was swollen and was located in the center of the tumor.

On the 14 th postoperative day (POD), the patient was found to have jaundice and the laboratory data were as follows: total bilirubin 6.7 mg/dl (0.2-1.0), direct bilirubin 4.8 mg/dl (0-0.5), alkaline phosphatase 1.254 U/ml (0.088-0.275), GOT 0.151 U/ml (0.008-0.040) and GPT 0.130 U/ml (0.005-0.035). CT scan demonstrated a tumor in the ampullary region of the duodenum (Fig. 4). Hypotonic duodenography and endoscopic examination showed an ulcerated tumor around the ampulla of Vater (Fig. 5 and 6). The biopsy specimens showed a B-cell lymphoma identical to the ileal tumor (Fig. 7). Chemotherapy with cyclophosphamide 560 mg, prednisolone 60 mg orally for 2



A



B

Fig. 7 Biopsy specimens from the duodenal tumor show a B cell malignant lymphoma identical to the ileal tumor.
A: H. E. stain (x400 original magnification).
B: Immunohistochemical staining for B cell (anti-B lymphocyte antibody; L26, DAKO, x200 original magnification).

days, and intravenous administration of adriamycin 60 mg was started 35 days after surgery. The tumor of the ampulla of Vater decreased in size after initial chemotherapy. As a result, intravenous administration of vincristine was added to the chemotherapeutic schedule and complete remission was achieved after one cycle. The patient is doing well at this writing without recurrence, 20 months after operation.

Discussion

Although they are more commonly single than multiple^{1,3,10}, gastrointestinal lymphomas with two or more tumors occur more often in the small intestine¹¹ than in the stomach¹². In our previous report¹³, malignant lymphomas accounted for 9 of 33 malignant small bowel neo-

plasms. Among these, seven lymphomas were located in the ileum and the remainder were in the jejunum, but neither multiple nor ampullary lesions were observed in our series.

Barium enema is helpful for the detection of tumors in the terminal ileum. A careful investigation of the terminal ileum is necessary, because the majority of small intestinal malignant lymphomas are found in the terminal ileum^{10,14}. The typical radiological features are long, dilated aperistaltic (aneurysmal) segments, nodular filling defects, mucosal ulceration, strictures, perforation, and enteroenteric fistulas¹⁵. A CT evaluation is also helpful, and CT features such as large, annular, aneurysmally ulcerated mass together with large lymphadenopathy are characteristic¹⁶. Patients with malignant lymphomas in the small intestine most commonly complain of nausea, vomiting and abdominal pain suggesting intestinal obstruction or the sudden onset of perforation necessitating surgical intervention^{1,2}. The definite diagnosis of small bowel lymphoma is difficult preoperatively, except for lesions in the duodenum or terminal ileum where endoscopic biopsy can be done¹⁷⁻¹⁹.

Tumors of the ampulla of Vater have traditionally been excluded from those of the gastrointestinal tract and are defined as neoplasms of the pancreato-biliary region. In ampullary lesions, it is sometimes difficult to determine the exact origin of the tumor. In the present patient, it was necessary to make a differential diagnosis as to whether the tumor arose from the ampulla of Vater or the head of the pancreas²⁰⁻²³. In the present case, the tumor was diagnosed as a malignant lymphoma of the ampulla of Vater on the basis of the findings of hypotonic duodenography, CT scanning, endoscopic examination and final biopsy. In the first reported case of primary lymphoma of the ampulla of Vater, the histogenesis of the lymphoma suggested a relationship with mucosa-associated lymphoid tissue (MALT), which was first described in the gastrointestinal tract as a low-grade extranodal lymphoma²⁴. However, no centrocyte-like cells or lymphoepithelial lesions were present in our case.

The majority of patients with primary lymphomas of the small intestine are treated surgically, and surgical resection was also mandatory for the treatment of perforation or obstruction of the small bowel^{1,2,4,25}. However, the management of patients with primary lymphomas of the ampulla of Vater has not been established. Whipple's procedure was conducted in the first reported case of primary non-Hodgkin's lymphoma of the ampulla of Vater⁵. Our patient, however, underwent chemotherapy without surgical treatment for the lymphoma in the ampulla of Vater. In the management of patients with pancreatic lymphoma, it is also controversial as to whether patients should be treated with Whipple's procedure, biliary-enteric bypass, chemotherapy or radiotherapy^{6,8,20-23,26}. Chemotherapy was recommended for the

management of primary lymphoma of the ampulla of Vater in the present case, because lymphomas are generally chemosensitive and radiosensitive, and because Whipple's procedure was too invasive considering the short interval after operation. In the past, patients were usually treated with combination chemotherapy, such as MACOP-B (methotrexate, adriamycin, cyclophosphamide, vincristine, prednisolone, bleomycin), CAMEL (cyclophosphamide, adriamycin, VP-16, methotrexate, leucovorin rescue) or CHOP (cyclophosphamide, adriamycin, vincristine, prednisolone), and the initial therapy was launched with non-hepatotoxic agents such as cyclophosphamide or prednisolone for a patient with obstructive jaundice⁹.

In conclusion, we treated a patient with primary malignant lymphomas arising simultaneously from the terminal ileum and the ampulla of Vater. The former was surgically resected while the latter was treated successfully with chemotherapy.

References

- 1) Dawson, I. M. P., Cornes, J. S. and Morson, B. C.; Primary malignant lymphoid tumors of intestinal tract. Report of 37 cases with a study of factors influencing prognosis. *Br. J. Surg.* 49: 80-89, 1961.
- 2) Naqvi, M. S., Burrows, L. and Kark, A. E.; Lymphoma of the gastrointestinal tract. *Ann. Surg.* 170: 221-231, 1969.
- 3) Lewin, K. J., Ranchod, M. and Dorfman, R. F.; Lymphoma of the gastrointestinal tract. *Cancer* 42: 693-707, 1978.
- 4) Contreary, K., Nance, F. C. and Becker, W. F.; Primary lymphoma of the gastrointestinal tract. *Ann. Surg.* 191: 593-598, 1980.
- 5) Pawade, J., Lee, C. S., Ellis, D. W., Vellar, I. D. A. and Rode, J.; Primary malignant lymphoma of the ampulla of Vater. *Cancer* 73: 2083-2086, 1994.
- 6) Boddie, A. W., Eisenberg, B. L., Mullins, J. D. and Schlichtemeier, A. L.; The diagnosis and treatment of obstructive jaundice secondary malignant lymphoma: a problem in multidisciplinary management. *J. Surg. Oncol.* 14: 111-113, 1980.
- 7) Birrer, M. J. and Young, R. C.; Differential diagnosis of jaundice in lymphoma patients. *Semin. Liver Dis.* 7: 269-277, 1987.
- 8) Webb, T. H., Lillimoe, K. D., Pitt, H. A., Jones, R. J. and Cameron, J. L.; Pancreatic lymphoma. Is surgery mandatory for diagnosis or treatment? *Ann. Surg.* 209: 25-30, 1989.
- 9) Young, I. F., Roberts-Thompson, I. C. and Sullivan, J. R.; Histiocytic lymphoma presenting with extrahepatic biliary obstruction: a report of three cases. *Aust. NZ. J. Surg.* 54: 181-183, 1981.
- 10) Faulkner, J. W. and Dockerty, M. B.; Lymphosarcoma of the small intestine. *Surg. Gynecol. Obstet.* 95: 76-84, 1952.
- 11) Berg, J. W.; Primary lymphoma of the human gastrointestinal tract. *Natl. Cancer Inst. Mono.* 32: 211-220, 1969.
- 12) Burgess, J. N., Dockerty, M. B. and ReMine, W. H.; Sarcomatous lesions of stomach. *Ann. Surg.* 173: 758-766, 1971.
- 13) Matsuo, S., Eto, T., Tsunoda, T., Kanematsu, T. and Shinozaki, T.; Small bowel tumors: an analysis of tumor-like lesions, benign and malignant neoplasms. *Eur. J. Surg. Oncol.* 20: 47-51, 1994.
- 14) Fu, Y. S. and Perizin, K. H.; Lymphosarcoma of the small intestine: A clinicopathologic study. *Cancer* 29: 645-659, 1972.
- 15) Cupps, R. E., Hodgson, J. R., Dockerty, M. B. and Adson, M. A.; Primary lymphoma in the small intestine. *Radiology* 92: 1355-1362, 1969.
- 16) Dudiak, K. M., Johnson, C. D. and Stephence, D. H.; Primary tumors of the small intestine: CT evaluation. *A. J. R.* 152: 995-998, 1989.
- 17) Kawai, K., Toda, M. and Misahi, F.; Present status of enteroscopy. *Acta. Endosc.* 12: 283-293, 1982.
- 18) Shinya, H. and McSherry, C.; Endoscopy of the small bowel. *Surg.*

- Clin. North. Am. 62 : 821-824, 1982.
- 19) Barakat, M, H.; Endoscopic features of primary small bowel lymphoma. *Gut* 23 : 36-41, 1982.
 - 20) Stasi, M. D., Cavanna, L., Fornari, F., Civardi, G., Sboli, G., Rossi, S., Buscarini, E., Giacani, M. and Buscarioni, L.; Obstructive jaundice secondary to non-Hodgkin's lymphoma: usefulness of ultrasound-guided fine-needle aspiration biopsy (UG-FNAB). *Eur. J. Haematol.* 44 : 265-266, 1990.
 - 21) Nakashiro, H., Tokunaga, O., Watanabe, T., Ishibashi, K. and Kuwaki, T.; Localized lymphoid hyperplasia (pseudolymphoma) of the pancreas presenting with obstructive jaundice. *Hum. Pathol.* 22 : 724-726, 1991.
 - 22) Kelly, S. B., Price, P. and Williamson, R. C.; Non-Hodgkin's lymphoma presenting with jaundice and hypercalcaemia. *Clin. Oncol.* 5 : 122-123, 1993.
 - 23) Joly, I., David, A., Payan, M. J., Sahel, J. and Sarles, H.; A case of primary non-Hodgkin's lymphoma of the pancreas. *Pancreas* 7 : 118-120, 1992.
 - 24) Isaacson, P. G. and Wright, D. H.; Malignant lymphoma of mucosa-associated lymphoid tissue. *Cancer* 52 : 1410-1416, 1983.
 - 25) Cooper, B. T. and Read, A. E.; Small intestinal lymphoma. *World J. Surg.* 9 : 930-937, 1985.
 - 26) Hart, M. J., White, T. T., Brown, P. C. and Frensz, P. C.; Potentially curable masses in the pancreas. *Am. J. Surg.* 154 : 134-136, 1987.