

# Inhibitory effect of spleen X-ray irradiation on dextran sulfate sodium-induced colitis in the mouse

Yoshihiko UME, Kazuya MAKIYAMA, Masahiro SENJU

Second Department of Internal Medicine, Nagasaki University School of Medicine, Nagasaki, Japan

Dextran sulfate sodium (DSS) solution was orally administered to mice to experimentally induce colitis, and the effects of X-ray irradiation of the spleen on healing or prolongation of inflammation was investigated. Peripheral, splenic and thymic T lymphocyte subsets were also analyzed to assess the underlying morbid conditions. Colitis with inflammatory changes consisting mainly of hemorrhagic erosions at the distal large intestine was induced by the administration of a 2% DSS solution for 14 consecutive days. The DSS-induced colitis was inhibited by pre-irradiation of the spleen with 20 Gy prior to the development of DSS-induced colitis. Healing of inflamed lesion was accelerated by irradiation with 20 Gy during the induction of colitis with DSS. The proportion of peripheral Thy-1<sup>+</sup> and L3T4<sup>+</sup> cells was higher while the proportion of splenic L3T4<sup>+</sup> cells was significantly lower compared with the control group during the preparation of DSS-induced colitis. At 2 and 7 days after pre-irradiation, peripheral and splenic Thy-1<sup>+</sup> and L3T4<sup>+</sup> cells increased and thymic Lyt-2<sup>+</sup> · L3T4<sup>+</sup> cells increased, whereas thymic Lyt-2<sup>+</sup> · L3T4<sup>+</sup> cell decreased. Our results suggest that the effect of splenic irradiation on DSS-induced colitis is due to a stimulation of T cell function, and activation of the immune system.

**Key words:** DSS-induced colitis, splenic irradiation, ulcerative colitis

## Introduction

Several reports have described experimental animal models of colitis for investigating the etiology of inflammatory bowel disease. Since Marcus & Watt<sup>1)</sup> reported carrageenan-induced colitis in 1969, various experimental models of colitis have been investigated, including dinitrochlorobenzene (DNCB) colitis,<sup>2)</sup> 2, 4, 6-trinitrobenzenesulfonic acid (TNBS) colitis,<sup>3)</sup> Interleukin-10-deficient mice,<sup>4)</sup> and T-cell receptor mutant mice.<sup>5)</sup> Dextran sulfate sodium (DSS) colitis was reported originally by Ohkusa<sup>6)</sup> in 1985. This form of colitis is characterized by melena, mucobloody stool and diarrhea as the initial symptoms, and is often associated with inflammation the mucosa, in the form of pancolitis. There are no lesions in the small intestine in DSS colitis.

The spleen is closely related to the immune system, and several studies have demonstrated that X-ray irradiation suppresses systemic immunity, causing atrophy of the thymus and spleen, and a reduction in leukocyte and bone marrow cell count. In the present study, we investigated the effect of spleen X-ray irradiation on DSS-induced colitis, by examining the colon histologically after a period of spleen irradiation. Thy-1, L3T4, and Lyt-2 positive cells in peripheral blood, spleen and thymus were also analyzed to evaluate the reaction of the immune system to irradiation.

## Materials and methods

**I. Animal model of DSS colitis.** Male BALB/C mice (20-25 g) were used in the present study, and were maintained with Oriental solid pellets MF during the experimental period. Colitis was induced by oral feeding of a 2% solution of high molecular dextran sulfate sodium (DSS; molecular weight, 54,000; Meito Sangyo Co.) provided ad libitum for 14 consecutive days.

**II. X-ray irradiation of the spleen.** Mice were anesthetized with pentobarbital and immobilized in the prone position. All areas, except the spleen, were covered with lead plates. X-ray irradiation was performed using the following setting of the X-ray system, 200 Kv; 15 mA; Filter 0.5 mm Al+0.5 mm Cu; 20 Gy (EXS-300 model, Toshiba Co.). The animals were divided into two groups based on the time of irradiation. Each group consisted of 5 mice. The pre-irradiation group consisted of animals in which the spleen was irradiated with 20 Gy prior to the development of experimental colitis. This was followed by feeding the animal 2% DSS solution, ad libitum, for 14 consecutive days. On the other hand, the post-irradiation group consisted of animals fed 2% DSS solution, ad libitum, for 14 consecutive days to induce colitis, followed by spleen irradiation with 20 Gy. No DSS solution was given after irradiation. The control group was also provided with DSS solution for 14 consecutive days but irradiation was not performed.

**III. Macroscopical and histological examination of DSS colitis.** Pre-irradiated animals were sacrificed 2, 7 and 14 days after administration of 2% DSS solution, while those in the post-irradiation group were sacrificed 2, 7 and 14 days after irradiation, by exsanguination. The control group was sacrificed 2, 7 and 14 days after administration of DSS. In each animal, the colon was excised immediately and semi-fixed in 10% formalin solution. The entire colon was first inspected macroscopically, then examined with a dissecting microscope. The area extending from the anus to 3.5 cm distal to the oral cavity, was stained with 0.2% methylene blue, and dissecting micrographs were taken. The total lesion area detected on the micrographs was determined using a digitizer (WT-4400SE, WACOM). Histological assessment was also performed following staining with hematoxylin-eosin.

**IV. Analysis of T lymphocyte subsets.** T lymphocytes, isolated from the peripheral blood, spleen and thymus, were assessed in the three groups at each collection time period by two-color analysis using FACScan (Becton Dickinson Immunocytometry System, U.S.A.) with monoclonal antibodies L3T4, Thy-1 and Lyt-2 (Becton Dickinson, U.S.A.). Peripheral blood samples were collected by severing the subclavian artery following anesthesia with ether. To isolate spleen and thymus lymphocytes, each organ was initially excised, and the connective tissue adhering to the sample removed. The specimen was washed with HANK's solution (GIBCO, U.S.A.), and thinly sliced with tweezers. Cells suspended in HANK's solution were filtered through a nylon mesh, and lymphocytes were isolated by Ficoll-Paque (Pharmacia, Sweden) specific gravity centrifugation. The cell sediment was resuspended in HANK's solution until analysis.

**V. Statistical analysis.** Data are expressed as mean  $\pm$  SD, and differences in the area of lesions were assessed between the three groups using the paired Student's *t*-test. Changes in T lymphocyte subsets were determined by analysis of variance, while T lymphocyte subsets at each phase between the irradiation and nonirradiation groups were compared using the paired Student's *t*-test. A difference with  $p < 0.05$  was considered statistically significant.

## Results

### I. DSS-induced colitis (control group)

**1) Macroscopic, dissecting microscopic and pathological features.** Melena and diarrhea appeared 5-7 days after the administration of 2% DSS solution until the end of the experiment. Macroscopically, the colonic mucosa was still almost normal 2 days after administration of DSS, but it became slightly edematous on day 7 with sporadic

erosions. There was a tendency for these features to be frequently observed in the distal colon. The colonic mucosa was markedly edematous 14 days after administration of DSS, associated with wide-spread hemorrhagic erosions extending from the rectum to the sigmoid colon.

Microscopic examination with methylene blue staining revealed several dendriform erosions extending from the rectum to the sigmoid colon on day 2 after administration of DSS, together with fragmentation of small segments of the colon around the erosions. Seven days after administration of DSS, the number and size of mucosal erosions increased, and the fragmentation became marked. These erosions became confluent 14 days after administration of DSS, and the mucosa surrounding the erosion became markedly irregular. These erosions were mainly distributed in the distal colon (Fig. 1). The main histopathological features included mucosal erosions and infiltration of inflammatory cells, such as lymphocytes and plasma cells, that gradually increased with time. Crypt abscesses were also observed in some cases. The inflammation was superficial, in all lesions, with no pathological findings beneath the tunica muscularis. There were no abnormal findings in the esophagus, stomach and small intestines.

**2) Measurement of the total area of colonic lesions.** The total area of abnormal mucosa (erosion area), as revealed by dissecting microscope with methylene blue staining, increased progressively with time from  $0.48 \pm 0.33$  mm<sup>2</sup> on day 2 after administration of DSS to  $2.41 \pm 1.28$  and  $32.7 \pm 9.2$  mm<sup>2</sup>, 7 and 14 days after administration, respectively (Fig. 3).

## II. Effect of splenic irradiation on colitis

### 1. Pre-irradiation group (Irradiation prior to the development of colitis)

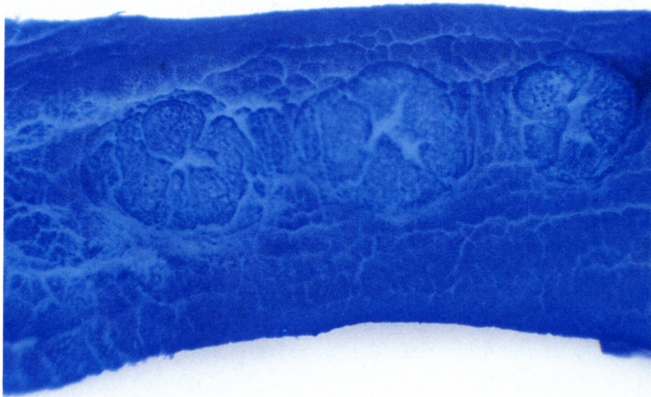
Bloody stool and diarrhea appeared 5-7 days after the start of administration of 2% DSS solution until the final day of the experiment. The severity of symptoms was slightly less than that of the control group.

*a) Macroscopic and microscopic features.* Two days after DSS administration, the mucosa surrounding the erosion was normal, with the exception of some spotty and linear erosions. Although only a small number of linear erosions, calluses and verrucae were present 7 days after administration, the mucosa around these lesions was relatively well maintained (Figs. 2a and b). The mucosa became edematous and irregular 14 days after administration of DSS, and diffuse erosions were sporadically observed.


*b) Determination of the total area of colonic lesions.* The total area of abnormal mucosa was  $0.43 \pm 0.21$ ,  $0.52 \pm 0.31$  and  $24.5 \pm 6.7$  mm<sup>2</sup> on day 2, 7 and 14, respectively, demonstrating a gradual increase with time. The pro-



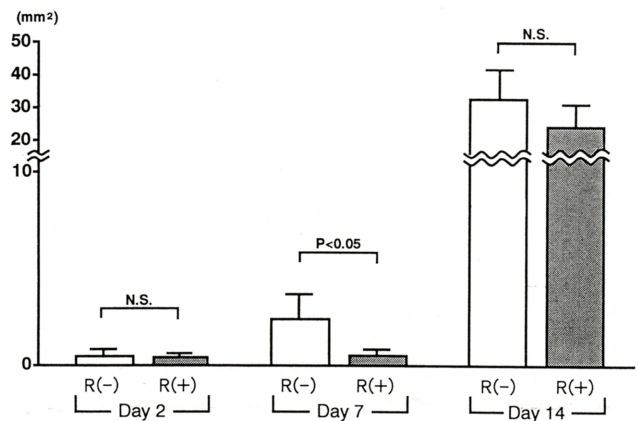
**Figure 1.** Dissecting micrograph of DSS-induced colitis (control group) 14 days after administration of 2% DSS solution



**Figure 2a.** Dissecting micrograph of control group 7 days after administration of 2% DSS solution

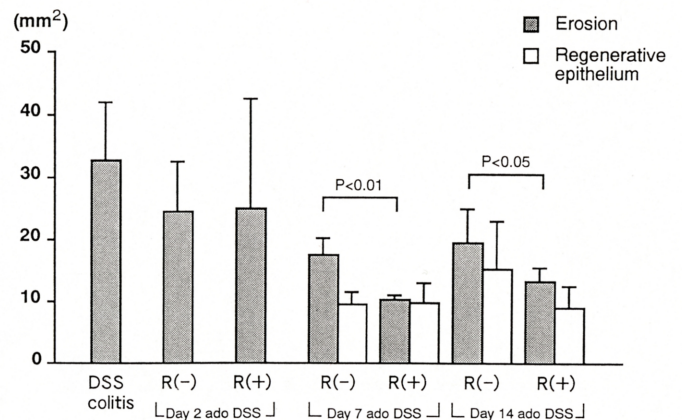


**Figure 2b.** Dissecting micrograph of pre-irradiation group 7 days after administration of 2% DSS solution



**Fig. 3.** Change with time of erosive area of DSS colitis- Comparison between pre-irradiation group and control group

R (-) : non-irradiation R (+) : non-irradiation



**Fig. 4.** Change with time of erosive area of DSS colitis- Comparison between post-irradiation group and control group

DSS colitis : Colitis two weeks after administration of DSS

R (-) : non-irradiation R (+) : irradiation  
ado DSS : after discontinuation of DSS

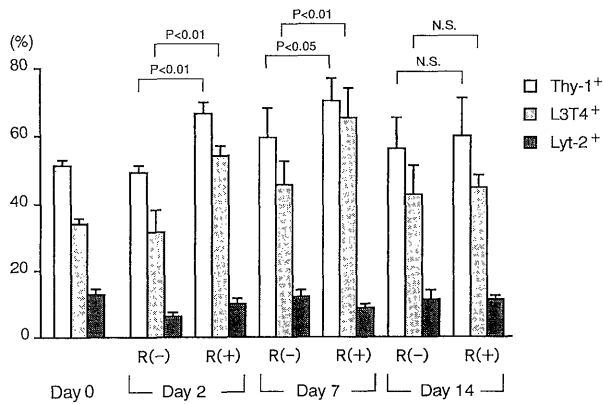
protective role of X-ray irradiation on colitis was distinctly observed on day 7 after irradiation, compared with the control. However, the effect of irradiation became negligible on day 14 (Fig. 3).

## 2. Post-irradiation group (Irradiation after development of colitis)

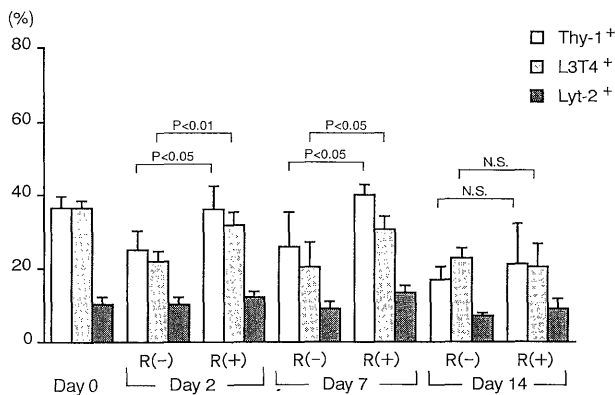
Diarrhea and melena disappeared and stool became normal starting from 5-7 days after discontinuation of DSS.

*a) Macroscopic and microscopic features.* Two days after discontinuing DSS, the intestinal tract was still edematous with diffuse erosions. The mucosa surrounding these erosions was irregular. There was no epithelial regeneration, and no difference in any parameter when

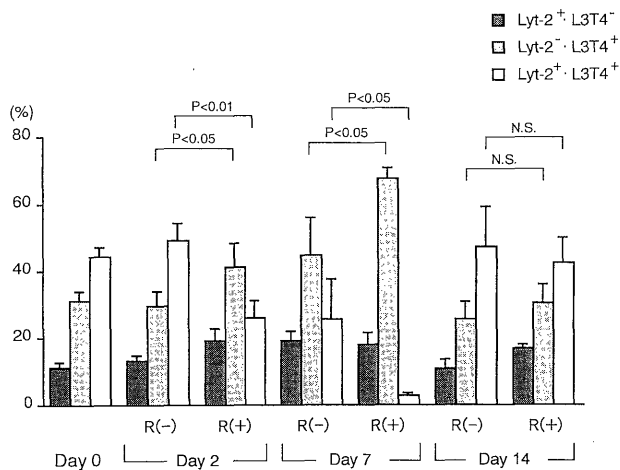




**Fig. 5.** Pre-irradiation group-Change of T-lymphocyte subsets in peripheral blood  
R (-) : non-irradiation R (+) : irradiation



**Fig. 6.** Pre-irradiation group-Change of T-lymphocyte subsets in spleen  
R (-) : non-irradiation R (+) : irradiation



**Fig. 7.** Pre-irradiation group-Change of T-lymphocyte subsets in thymus  
R (-) : non-irradiation R (+) : irradiation

compared with the control group at this time interval. Seven days after discontinuation of DSS, the diffuse erosions formed regenerated epithelia around them, which tended to regress, as observed in the control group. However, the trend was more marked in the irradiation group, while the mucosa around the lesions was still irregular in the control group. Mucosal irregularity improved 14 days after discontinuation of DSS, compared with that observed 7 days after discontinuation, but erosions and epithelial regeneration were still unchanged. However, both the eroded surface and regenerated epithelial areas tended to regress in this group (Fig. 4).

*b) Determination of total area of colonic lesions.* Since regenerated epithelium was observed on the margin of erosion when the administration of DSS was discontinued, the area of regeneration was determined separately from that of the erosion. The total area of erosion after discontinuation of DSS was  $25.1 \pm 17.1$ ,  $10.3 \pm 0.8$  and  $13.3 \pm 2.1$  mm<sup>2</sup>, 2, 7 and 14 days after discontinuation of DSS, respectively. Epithelial regeneration appeared 7 days after DSS discontinuation, and areas were  $9.7 \pm 3.3$  and  $8.9 \pm 3.7$  mm<sup>2</sup>, 7 and 14 days after withdrawal of DSS, respectively. There was no difference in the regression of erosion between control and irradiation groups, 2 days after discontinuation. However, 7 and 14 days after discontinuation, regression had proceeded further in both groups. The regression was more evident in the irradiation group compared with the control ( $p < 0.01$  at 7 days,  $p < 0.05$  at 14 days after discontinuation). Epithelial regeneration appeared 7 days after discontinuation in both groups, but there was no difference between the groups or between 7 and 14 days after discontinuation (Fig. 4).

### III. Changes in T lymphocyte subsets

#### 1. Peripheral blood

The proportion of peripheral blood Thy-1<sup>+</sup> (Pan-T) and L3T4<sup>+</sup> (helper T) cells was significantly higher in the pre-irradiation group compared with the control group 7 days after the administration of DSS (Thy-1<sup>+</sup> :  $p < 0.01$ , L3T4<sup>+</sup> :  $p < 0.01$ ). Thy-1<sup>+</sup> cells continued to increase 14 days after administration of DSS, but the proportion of L3T4<sup>+</sup> cells in pre-irradiation and control groups was similar. Lyt-2<sup>+</sup> (suppressor T) cells did not change during the administration of DSS (Fig. 5).

Thy-1<sup>+</sup> and L3T4<sup>+</sup> cells increased 2-7 days after administration of DSS, and slightly decreased at 14 days in the pre-irradiation group. Lyt-2<sup>+</sup> cells were unchanged. The proportion of Thy-1<sup>+</sup> and L3T4<sup>+</sup> cells was significantly higher in the pre-irradiation group compared with the control, 2 and 7 days after administration (Thy-1<sup>+</sup> :  $p < 0.01$ , 0.05, L3T4<sup>+</sup> :  $p < 0.01$ , 0.01) (Fig. 5)

#### 2. Spleen

The proportion of splenic Thy-1<sup>+</sup> and L3T4<sup>+</sup> cells

gradually decreased compared with the control group from 2 days after administration of DSS. Lyt-2<sup>+</sup> cells were unchanged during DSS administration (Fig. 6). Thy-1<sup>+</sup> and L3T4<sup>+</sup> cells were unchanged, 2 and 7 days after administration, but reduced significantly 14 days after administration of DSS. At 2 and 7 days after administration, the proportion of Thy-1<sup>+</sup> and L3T4<sup>+</sup> cells was significantly higher than the control group (Thy-1<sup>+</sup>:  $p < 0.05$ , 0.05, L3T4<sup>+</sup>:  $p < 0.01$ , 0.05), but there was no significant difference between these groups 14 days after administration (Fig. 6).

### 3. Thymus

Thymic Lyt-2<sup>-</sup>•L3T4<sup>+</sup> cells increased and Lyt-2<sup>+</sup>•L3T4<sup>+</sup> cells decreased, 2-7 days after administration of DSS, but Lyt-2<sup>+</sup>•L3T4<sup>-</sup> cells were unchanged (Fig. 7). On the other hand, Lyt-2<sup>-</sup>•L3T4<sup>+</sup> cells increased and Lyt-2<sup>+</sup>•L3T4<sup>+</sup> cells decreased, 2-7 days after administration of DSS. Lyt-2<sup>+</sup>•L3T4<sup>-</sup> cells were unchanged. The proportion of Lyt-2<sup>-</sup>•L3T4<sup>+</sup> cells was significantly higher compared with the control group, 2 and 7 days after administration of DSS ( $p < 0.05$ , 0.05), while the proportion of Lyt-2<sup>+</sup>•L3T4<sup>+</sup> cells was significantly lower than that of the control group ( $p < 0.01$ , 0.05) (Fig. 7)

## Discussion

The role of cytokines (IL-1,<sup>7</sup> IL-2,<sup>8</sup>, IL-6,<sup>9</sup> IL-8<sup>10</sup>) INF,<sup>11</sup> TNF,<sup>12</sup> ECP<sup>13</sup>) and abnormalities in arachidonic acid metabolic systems (LTB<sub>4</sub>, 5-HETE, PGE<sub>2</sub><sup>14</sup>) in ulcerative colitis have been clarified recently through the analysis of local immunocompetent cells.

The first report on DSS-induced colitis was by Ohkusa,<sup>6</sup> who administered DSS orally to hamsters to induce inflammatory lesions, such as ulcers in the cecum, colon and rectum. According to this investigator, the histological findings include marked edema, inflammatory cellular infiltration and crypt abscesses, i.e., findings resembling those of human ulcerative colitis. However, the lesions develop from the cecum to the anus and are induced only by drug administration. DSS colitis is different from ulcerative colitis in humans only in this regard.

The mechanism of onset of DSS colitis involves a direct damage of the colonic mucosa by DSS itself. Marcus & Watt<sup>15</sup> postulated that a potent negative electronic state prevents the defense mechanism of the colonic mucosa to protect itself against ulcer formation because sulfate polysaccharide bodies are present on the surface of the colonic mucosa with several other anions. A change in intestinal flora is also considered to be involved in the onset of ulcerative colitis. Ohkusa<sup>6</sup> investigated changes in intestinal flora in the hamster model of DSS-induced colitis and suggested that increased Bacteroidaceae was involved in colitis formation. Other factors involved in the

initiation of ulcerative colitis include cytokines secretion and damage of the colonic mucosa by free radicals.<sup>16</sup>

Studies examining the control of DSS-induced colitis have used immunosuppressors, e.g., cyclosporin<sup>16</sup> and FK 506.<sup>15</sup> In the present study, we attempted experimental control of colitis by splenic X-ray irradiation. To our understanding, this is the first report of the use of such technique in this model. Although there have been no reports on irradiation of the spleen alone, total lymphoid irradiation has been used as a treatment for another autoimmune disease, chronic rheumatoid arthritis.<sup>17</sup> This therapy markedly decreases the number of lymphocytes in the blood and increases the CD8/CD4 ratio (due to a decrease in CD4<sup>+</sup> cell count), and results in pokeweed mitogen-induced immunoglobulin secretion of suppressor cells.<sup>18, 19</sup> Such immune state is considered to lead to a remission of chronic rheumatoid arthritis. In animal experiments using the same procedure, other reports have demonstrated that long-term immunosuppressive effects are related to the expression of antigen-nonspecific suppressor T-cells.<sup>20, 21</sup> Based on these studies, we predicted an effective role for splenic irradiation in DSS-induced colitis.

Evaluation of the macroscopic features and the areas of erosion in the present study indicate that these areas significantly regressed 7 days after the administration of DSS regardless of the time of irradiation, i.e., before or after administration of DSS for induction of colitis. Our results demonstrated an inhibitory effect of irradiation on the onset of colitis as well as acceleration of the healing process. However, there was almost no difference in the inhibitory effect or acceleration of healing 14 days after administration of DSS, between the irradiation and control group. This is probably due to a diminished effective dose of radiation with time. Based on our results, changes in peripheral, splenic and thymic pan-T cells, suppressor T cells, and helper T cells, the mechanisms protecting against colitis are considered to be as follows. Thy-1<sup>+</sup> and L3T4<sup>+</sup> cells started to decrease 2 days after administration of DSS. On the other hand, peripheral and splenic Thy-1<sup>+</sup> and L3T4<sup>+</sup> cells started to increase following irradiation, thymic Lyt-2<sup>-</sup>•L3T4<sup>+</sup> cells increased markedly, whereas thymic Lyt-2<sup>+</sup>•L3T4<sup>+</sup> cells decreased. These changes became marked 2-7 days after administration. Thus, lymphocytes, consisting mainly of L3T4<sup>+</sup> cells, with higher radiosensitivity are probably disrupted and diminished in the spleen at an extremely early stage, providing a feedback to the thymus and resulting in a marked acceleration of Lyt-2<sup>+</sup>•L3T4<sup>+</sup> cells differentiation to Lyt-2<sup>-</sup>•L3T4<sup>+</sup> cells in the thymus. This leads to a release of several cells into the peripheral blood.

The analysis of local lymphocytes in the colonic mucosa during the active stage in patients with ulcerative colitis demonstrates a high proportion of CD4<sup>+</sup>, CD20<sup>+</sup> and activated T cells, and a low proportion of CD8<sup>+</sup> cells.<sup>22, 23</sup> In addition, macrophages are usually activated, while the

cytokine network is stimulated<sup>10,20</sup>) The healing effect of splenic irradiation on DSS-induced colitis is, however, considered to be due to a stimulation of T cell function, which tends to secondarily decrease, and to activate the immune system. These processes suggest that DSS-induced colitis is distinctly different from ulcerative colitis in terms of morbidity, although DSS-induced colitis histopathologically resembles ulcerative colitis. However, X-ray irradiation is believed to exert its action at a small dose, unlike the high dose needed for the immune system<sup>25</sup>). The application of irradiation as a treatment for ulcerative colitis requires further studies to examine the dose, frequency of X-ray irradiation in relation to the severity of the disease.

### Acknowledgements

The author thank Professor Khohei Hara, Second Department of Internal Medicine, Nagasaki University School of Medicine, for carefully reading the manuscript. We also express sincere gratitude to Professor Yutaka Okumura, Mr. Tatsuya Shimasaki for performing X-ray irradiation.

### References

- 1) Marcus R, Watt J: Seaweeds and ulcerative colitis in laboratory animals. *Lancet*. 2: 489 (1969)
- 2) Rabin BS, Rogers SJ: A cell-mediated immune model of inflammatory bowel disease in the rabbit. *Gastroenterology*. 75: 29 (1978)
- 3) Morris GP, Beck PL, Herridge MS, Depew WT, Szewczuk MR, Wallace JL: Hapten-induced model of chronic inflammation and ulceration in the rat colon. *Gastroenterology*. 96: 795 (1989)
- 4) Kühn R, Löffler J, Rennik D, Raiejewsky K, Müller W: Interleukin-10-deficient mice develop chronic enterocolitis. *Cell*. 75: 263 (1993)
- 5) Mombaerts R, Mizoguchi E, Grusby MJ, Glimcher LH, Bhan AK, Tonegawa S: Spontaneous development of inflammatory bowel disease in T cell receptor mutant mice. *Cell*. 75: 275 (1993)
- 6) Ohkusa T: Production of experimental ulcerative colitis in hamsters by sulfate sodium and change in intestinal microflora. *Jpn. J. Gastroenterol.* 82: 1327 (1985) (Japanese)
- 7) Ligumsky M, Simon PL, Karmeli F, Rachmilewitz D: Role of IL-1 in inflammatory bowel disease. Enhanced production during active disease. *Gut*. 31: 686 (1990)
- 8) Mahida YR, Gallagher A, Kurlak L, Hawley EJ: Plasma and tissue interleukin 2 receptor levels in inflammatory bowel disease. *Clin. Exp. Immunol.* 82: 75 (1990)
- 9) Hyams JS, Fitzgerald JE, Treem WR, Wyzga N, Kreutzer DL: Relationship of functional and antigenic interleukin 6 to disease activity in inflammatory bowel disease. *Gastroenterology*. 104: 1285 (1993)
- 10) Sartor RB: Cytokines in intestinal inflammation: Pathophysiological and clinical considerations. *Gastroenterology*. 106: 533 (1994)
- 11) Breez E, Braegger CP, Corriran CJ, Walker-Smith JA, Macdonald TT: Interleukin-2 and interferon- $\gamma$ -secreting T cells in normal and disease human intestinal mucosa. *Immunology*. 78: 127 (1993)
- 12) Breese EJ, Michie CA, Nicholls SW, Murch SH, Williams CB, Domizio P, Walker-Smith JA, Macdonald TT: Tumor necrosis factor  $\alpha$ -producing cells in the intestinal mucosa of children with inflammatory bowel disease. *Gastroenterology*. 106: 1455 (1994)
- 13) Yamasaki K, Makiyama K, Murata I, Itsuno M, Senju M, Hara K: Evaluation of serum eosinophil cationic protein (ECP) level in patient with ulcerative colitis. *Gastroenterol. Jpn.* 26: 232 (1991)
- 14) Lauristen K, Laursen LS, Bukhave K, Rask-Madsen J: In vivo profiles of eicosanoids in ulcerative colitis, Crohn's colitis and Clostridium difficile colitis. *Gastroenterology*. 95: 11 (1988)
- 15) Takizawa H: Immunological study of experimental colitis induced by dextran sulfate sodium in rats. -Immunocompetent cells in colonic mucosa. *Niigata. Med. J.* 106: 949-59 (1992) (Japanese)
- 16) Shim H, Murthy S, Cooper H, Ibrahim S: Intracolonic (IC) cyclosporin (CSP) accelerate healing of experimental colitis induced by dextran sulfate (DSS) in the mouse (abstr). *Gastroenterology*. 100: A 168 (1991)
- 17) Trentham DE, Belli TA, Anderson RJ, Buckley JA, Goetzl EJ, David JR, Austen KF: Clinical and immunologic effect of fractionated total lymphoid irradiation in refractory rheumatoid arthritis. *N. Engl. J. Med.* 305: 976 (1981)
- 18) Kotzin BL, Kansas GS, Engleman EG, Hoppe RT, Kaplan HS, Strober S: Change in T-cell subsets in patient with rheumatoid arthritis treated with total lymphoid irradiation. *Clin. Immunol. Immunopathol.* 27: 250 (1983)
- 19) Kotzin BL, Strober S, Engleman EG, Calin A, Hoppe RT, Kansas GS, Terrell CP, Kaplan HS: Treatment of intractable rheumatoid arthritis with total lymphoid irradiation. *N. Engl. J. Med.* 305: 969 (1981)
- 20) Slavin S, Strober S, Fucks Z, Kaplan HS: Induction of specific tissue transplantation tolerance using fractionated total lymphoid irradiation in adult mice: long-term survival of allogeneic bone marrow and skin graft. *J. Exp. Med.* 34 (1977)
- 21) King DP, Strober S, Kaplan HS: Suppression of the mixed leukocyte response and of graft-vs-host disease by spleen cells following total lymphoid irradiation (TLI). *J. Immunol.* 126: 1140 (1981)
- 22) Senju M, Wu KC, Machida YR, Jewell DP: Coexpression of CD4 and CD8 on peripheral blood T cells and lamina propria T cells in inflammatory bowel disease by two colour immunofluorescence and flow cytometric analysis. *Gut*. 32: 918 (1991)
- 23) Senju M, Wu KC, Machida YR, Jewell DP: Two-colour immunofluorescence and flowcytometric analysis of Lamina propria lymphocyte subsets in ulcerative colitis and Crohn's disease. *Dig. Dis. Sci.* 36: 1453 (1991)
- 24) Schreiber S, MacDermott RP, Raedler A, Pinnau R, Bertovich MJ, Nash GS: Increased activation of isolated intestinal lamina propria mononuclear cells in inflammatory bowel disease. *Gastroenterology*. 101: 1020 (1991)
- 25) Bagasra O, Tabor D: Irradiation and cyclophosphamide-induced alterations in syrian hamster T-cell population activity. *J. Leuko. Biol.* 39: 183 (1986)