

The Echogenic Patterns of the Pancreatic Parenchyma in the Endoscopic Ultrasonography

Shoji HONDA, Toshio FUJIOKA, Kanzoh FUJIYAMA, Toshihiro KUBOTA, Kazunari MURAKAMI, Hideo TERAU, and Masaru NASU

The Second Department of Internal Medicine, Oita Medical University

Using the pancreas of the Japanese Macaque and human pancreas from autopsy cases, the echogenic patterns of the pancreatic parenchyma obtained by the ultrasonic endoscopy were compared with the histological findings. The parenchyma of the normal pancreas was observed as an echogenic pattern with homogeneous accumulation of small granular echoes. Such granular echoes are suggested to represent pancreatic acini on comparison with the tissue structure. This was confirmed by widening the pancreatic interstitium by infusing physiological saline into the main pancreatic duct. Such granular echoes became indistinct in the pancreas from autopsy cases due to autolysis. In the experimental pancreatic lesion produced by local injection of 1% deoxycholic acid into the pancreas of Japanese Macaque, hemorrhage and fibrosis were noted 1 week later and fibrosis appears after 2 to 3 weeks. Hemorrhagic lesions were appeared as an area of high echogenicity, and fibrosis was appeared as an area of low echogenicity, with irregularity of the granular structure seen in the normal tissue.

Introduction

Endoscopic retrograde cholangio-pancreatography (ERCP), ultrasound (US) or computed tomography (CT) were most common imaging diagnostic method for pancreas. ERCP is an excellent method for imaging the pancreatic duct, but cannot image the parenchymal finding. US is influenced by abdominal tissues or bowel gas and CT cannot image finely the pancreatic parenchyma. Endoscopic ultrasonography (EUS) can image pancreatic parenchyma clearly, fully and finely without influence from abdominal tissue or bowel gas, using higher sonographic frequencies. Though several reports on the pancreas are available, no one has ever evaluated the echogenic pattern of the normal pancreatic parenchyma from a histological viewpoint. We have therefore used the pancreas of Japanese Macaque and human pancreas obtained at autopsy to make a comparison between EUS findings of the pancreatic parenchyma and histological findings in order to correlate the echogenic pattern of the normal pancreatic parenchyma with the pancreatic tissue. Using Japanese Macaque,

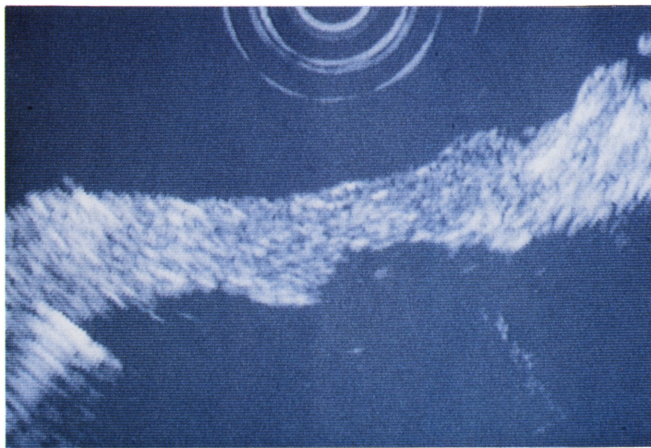
furthermore, pancreatic damage was produced experimentally for comparison between EUS findings and histological findings, in order to clarify the changes occurring in the normal echogenic patterns on the development of pancreatic damage.

Materials and Methods

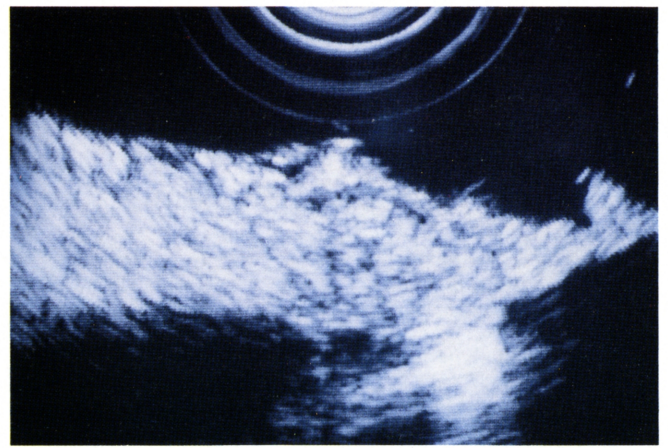
The instrument used in this study was a radial type ultrasonic endoscope GF-UM2 (Olympus Co. Ltd., Tokyo) with 7.5 MHz transducer EU-M2 (Aloka Co. Ltd., Tokyo, Japan).

Five Japanese Macaque were used. One normal pancreas, one normal pancreas infused with physiological saline in the pancreatic tube, and 3 pancreases with experimentally produced damage were used. Normal pancreas was removed together with spleen and duodenum immediately after sacrifice. After a quick EUS observation in a waterbath, it was fixed in formalin. The pancreatic specimen infused with physiological saline was prepared by removing the normal pancreas as described above, and studied, followed by an infusion of 10 ml physiological saline into the pancreatic duct from the duodenal papilla. The organ was again studied under EUS in a waterbath and fixed in formalin. The injured pancreas was prepared by a local injection of 1% sodium deoxycholate into the pancreatic parenchyma during ketaral-induced anesthesia in a Japanese Macaque and the incision was closed. The animal was sacrificed 1 week, 2 weeks and 3 weeks later to remove the pancreas. After the pancreases were observed by EUS, it was fixed quickly in formalin. Histological sections were stained by HE, Azan-Mallory and silver impregnation method. This study was performed according to The Helsinki Declaration.

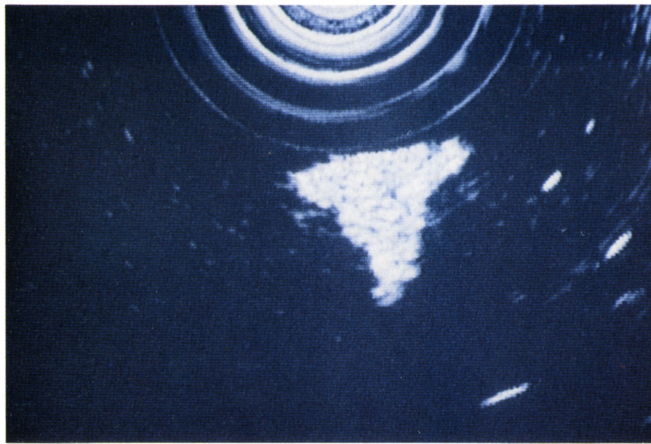
The pancreas with normal appearance obtained at autopsy was studied quickly in a waterbath under EUS, after removal together with spleen and descending loop of the duodenum. It was then fixed in formalin and the sections were stained by HE. Three cases were thus studied, after more than 4 hours after death.



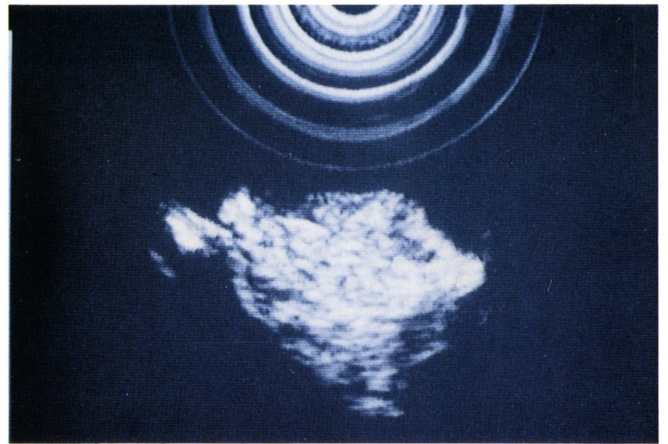
(a)



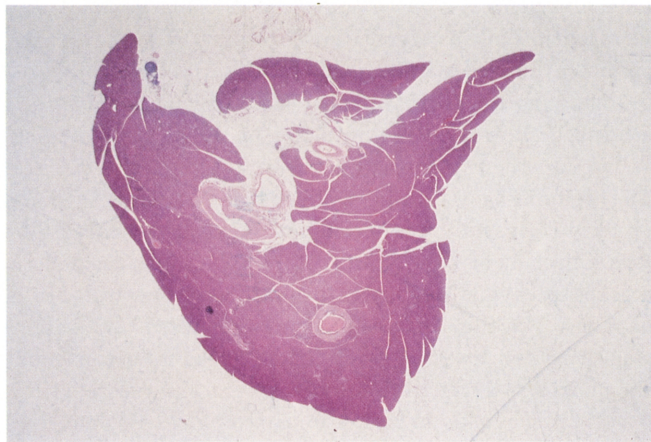
(a)



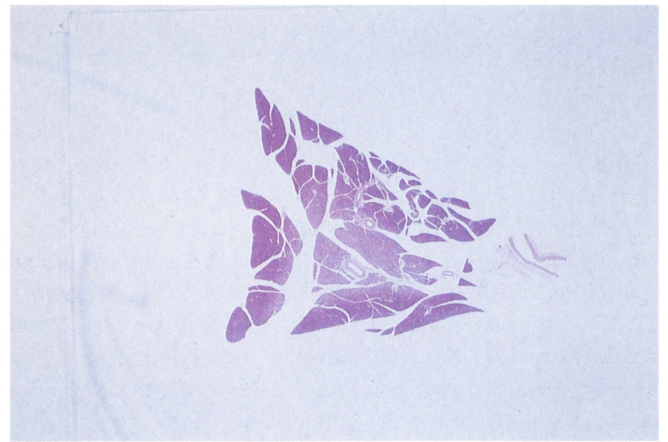
(b)



(b)



(c)



(c)

Figure 1. Endoscopic ultrasonogram of the normal pancreas of Japanese Macaque. A homogenous echo gathering of grain echos measuring 1-2 mm was observed, and these grain echos appeared to represent the pancreatic lobulus. (a) A longitudinal finding. (b) A cross finding. (c) Hematoxylin-eosin stain of cross section.

Figure 2. Endoscopic ultrasonogram of the pancreas of Japanese Macaque, instillation of saline into the main pancreatic duct. The interstitium was extended and grain echos imaged in Fig. 1 were imaged more clearly. (a) A longitudinal finding. (b) A cross finding. (c) Hematoxylin-eosin stain of cross section.

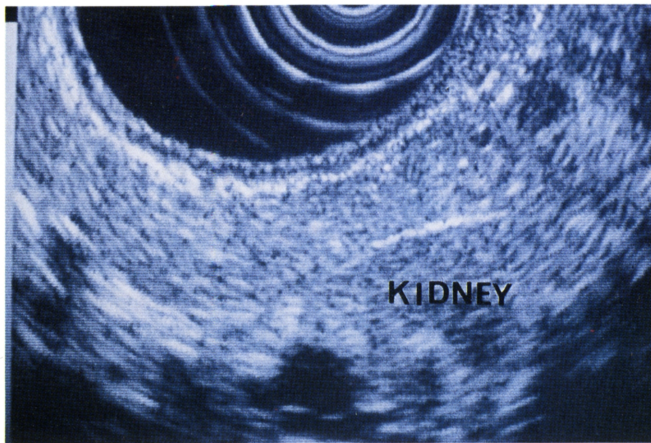
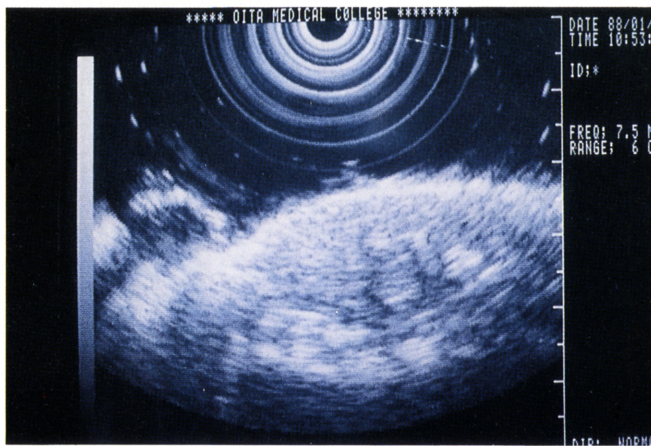
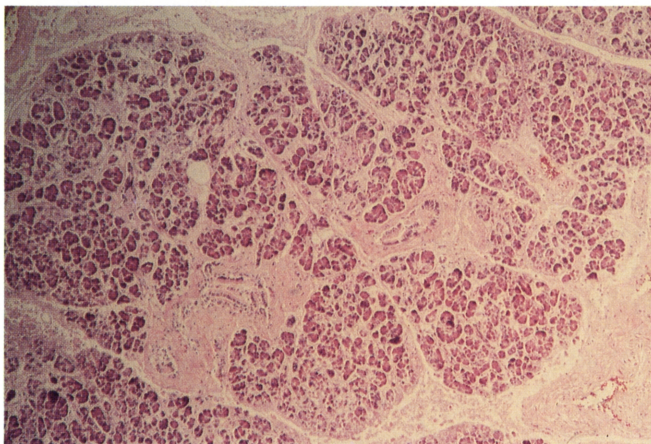


Figure 3. Endoscopic ultrasonographic findings of pancreas in clinical examination of the healthy 17 year old male. The findings of the same as Fig. 1 were showed.



(a)



(b)

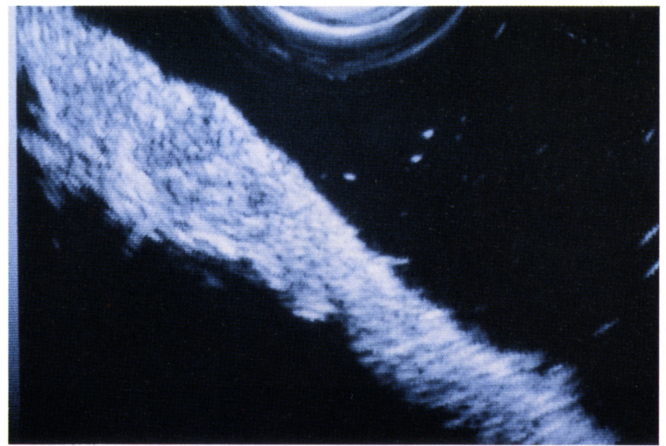
Figure 4. Endoscopic ultrasonogram (a) and photomicrograph of Hematoxylin-and-eosin stained section (b) of the human pancreas obtained at autopsy. The normal grain echo pattern was unclear (a), and it was suggested that this phenomenon was caused by autolysis (b).

Results

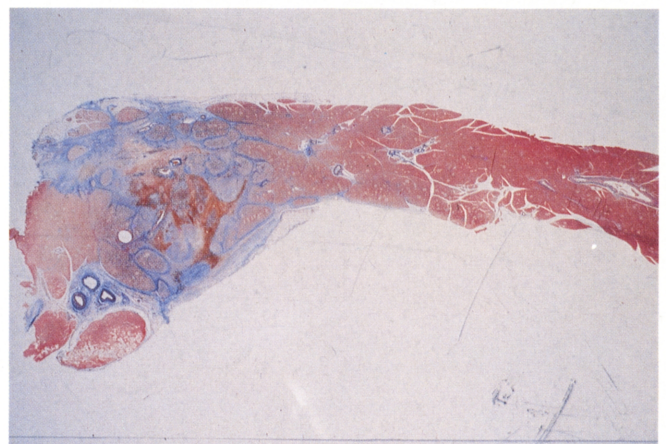
The echo pattern of the normal pancreatic parenchyma of Japanese Macaque was studied by EUS. A homogeneous echo gathering of grain echoes measuring 1-2 mm was revealed, and these grain echoes appeared to represent the pancreatic lobulus (Figure 1a, b, c). It became clearer upon instillation of saline into the main pancreatic duct, extending the interstitium (Figure 2a, b, c). The normal echo pattern of the human pancreas in a clinical examination using EUS resulted in similar findings (Figure 3).

In three human pancreases obtained at autopsy, the normal grain echo pattern was unclear due to autolysis (Figure 4a, b).

At 1 week after the preparation of pancreatic injury, the

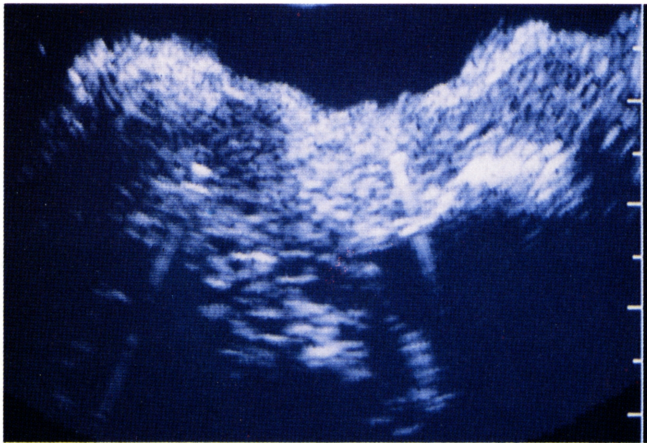


(a)

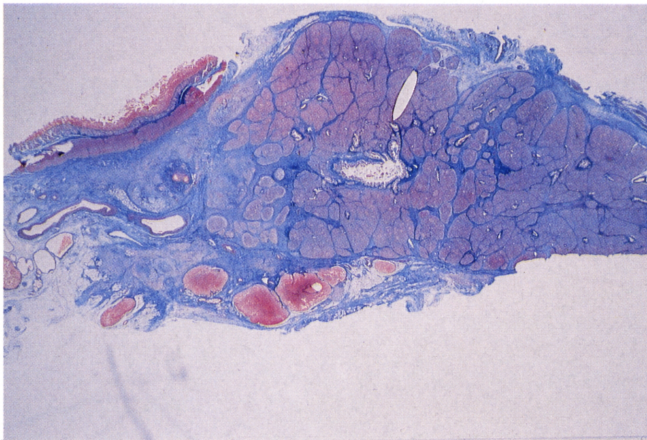


(b)

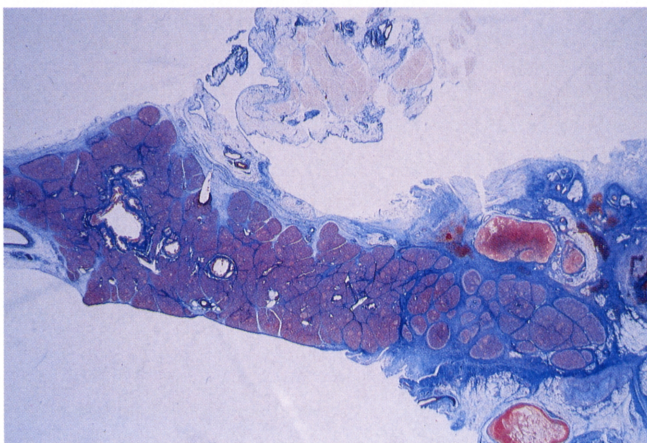
Figure 5. Endoscopic ultrasonogram (a) and loupe-graph of Azan-Mallory staining (b) of the pancreas of Japanese Macaque at 1 week after the preparation of pancreatic injury. The hemorrhagic lesion was depicted as high echogenicity, and fibrosis was imaged as low echogenicity.



(a)



(b)



(c)

Figure 6. Endoscopic ultrasonogram (a) and loupe-graph of Azan-Mallory staining of the pancreatic head (b) and tail (c) of Japanese Macaque at 2 weeks after the preparation of pancreatic injury. Only fibrosis was noted in the head and tail, and in EUS, a low echogenic area surrounding granular echoes is noted.

center of the region with injury appeared hemorrhagic, surrounded by fibrosis. Under EUS, the hemorrhagic lesion was depicted as a high echogenicity, surrounded by an area with lower echogenicity than the normal region. Within this area of low echogenicity, granular echoes with normal echogenicity are noted (Figure 5a, b).

Low echogenicity represents fibrosis and granular echoes within this area, normal tissues surrounded by the fibrotic zone. After 2 or 3 weeks, only fibrosis was noted and no hemorrhage was seen. In EUS, a low echogenic area surrounding granular echoes is noted (Figure 6a, b, c).

DISCUSSION

EUS diagnosis for the pancreatic diseases is useful in carcinoma, chronic pancreatitis, pancreatic cyst and other pancreatic diseases¹⁾⁻⁷⁾. Since EUS make it possible to observe the pancreas through the gastric and duodenal wall from a very short distance, even the observation in vivo may achieve findings comparable to those obtained on observation of the removed organ in a waterbath. An echogram of the normal human pancreas is shown in Fig. 3, with almost homogenous arrangement of small granular echoes. Under a hypothesis that the arrangement of such echogenic granules becomes irregular in diseases of the pancreas, this study was conducted.

Fine granular echoes in the normal pancreas probably represent the acinar structure of the pancreas. In order to test this hypothesis, physiological saline was infused from the main pancreatic duct to enlarge the interstitium. The size of the fine granular echoes did not change, with appearance of a wide low echogenic zone between these granular echoes. The pancreas was swollen as a whole. The low echogenic area thus appears to represent the interstitium and the granular echoes as the acini surrounded by the interstitium. Though no reports are yet available on the ultrasonic endoscopy on acute pancreatitis, a wide low echoic zone is assumed to appear between each granular structure in acute edematous pancreatitis as described above. In the pancreas from autopsy cases, these granular echoes became indistinct, probably due to the autolysis of the pancreatic acini, again suggesting the relationship between the granular structure in the echogram and pancreatic acini.

Experimental pancreatic lesions were then produced in Japanese Macaque to study the echogram of the lesion. One week after the local injection of sodium deoxycholate into the pancreatic parenchyma, hemorrhage and fibrosis was noted, and only fibrosis remains after 2, 3 and 4 weeks. In the echographic findings, the hemorrhagic foci are depicted as a high echogenic area and the fibrotic portion as a low echogenic area. Among the low echoic regions, granular structures with normal echogenicity were noted, representing normal tissues surrounded by

fibers. According to Kaufman et al., EUS findings in chronic pancreatitis include cystic changes, calcification, pseudocyst, atrophic pancreas and mixed echogenicity⁸⁾. Since fibrosis is expressed as a low echogenicity, the presence of low echogenic area surrounding the granular echogenic structures, especially the changes of the echogenic patterns of normal granular structure should be evaluated in detail in order to make the diagnosis of relatively early stage of chronic pancreatitis possible.

References

- 1) Fukuda M, Nakano Y, Saito K, et al: Endoscopic ultrasonography in the diagnosis of pancreatic carcinoma. The use of liquid filled stomach method. Scand J Gastroenterol 19 (suppl 94) : 65-76 (1984).
- 2) Yasuda K, Mukai H, Fujimoto S, et al: The diagnosis of pancreatic cancer by endoscopic ultrasonography. Gastrointest Endosc 34 : 1-8 (1998).
- 3) Boyce GA, Sivak MV: Endoscopic ultrasonography in the diagnosis of pancreatic tumors. Gastrointest Endosc 36 : S28-S32 (1990).
- 4) Lees WR: Endoscopic ultrasonography of chronic pancreatitis and pancreatic pseudocysts. Scand J Gastroenterol 21 (suppl 123) : 123-129 (1986).
- 5) Lin JT, Wang JT, Wang TH: The diagnostic value of endoscopic ultrasonography in pancreatic disorders. J Formosan Med Assoc 88 : 483-487 (1989).
- 6) Jones SN, Lees WR and Frost RA: Diagnosis and grading of chronic pancreatitis by morphological criteria derived by ultrasound and pancreatography. Clinical Radiology 39 : 43-48 (1988).
- 7) Honda S, Fujioka T, Fujiyama K, et al: Acquired fatty replacement of the body and tail of the pancreas diagnosed by endoscopic ultrasonography. - A case report -. Dig. Endosc 5 : 251-256 (1993).
- 8) Kaufman AR, Sivak MV: Endoscopic ultrasonography in the differential diagnosis of pancreatic disease. Gastrointest Endosc 35 : 214-219 (1989).