

Experimental-Induced Colitis in Rats by Ethanolic Solution of Trinitrobenzene Sulfonic Acid and Ethanol Alone : A Comparative Study

Walter ZEA-IRIARTE M. D., Kazuya MAKIYAMA M. D., Minoru ITSUNO M. D., Yoshihiko UMENE M. D., Kohei HARA M. D.

The Second Department of Internal Medicine, Nagasaki University School of Medicine

Epidemiological data suggest an increase in both developed and undeveloped countries of inflammatory bowel disease. Furthermore, its etiology and pathophysiology remain unknown. Appropriated animal models are needed. We have studied a rat model of hapten-induced chronic colitis. In Wistar rats, intracolonic instillation of 20 mg or 42 mg of the hapten trinitrobenzene sulfonic acid in 30 % and 40 % ethanol proved to induce chronic colitis after 14 to 21 days of administration, in dose-dependent fashion when compared with ethanol alone that induced only acute colitis after three days of administration. This chronic colitis shares some characteristics with inflammatory bowel disease in humans, specially with Crohn's disease, such as transmural inflammation, development of strictures, ulcerations and infiltration of inflammatory cells throughout the colonic wall. These features make this model suitable for further studies of intestinal inflammation.

Introduction

Data obtained from epidemiological studies suggest an increase in both developed and undeveloped countries of chronic inflammatory bowel disease (IBD), namely, ulcerative colitis and Crohn's disease^{1,2)}. Despite extensive research on IBD, their etiology and pathogenesis are still not known. The ideal animal model is also unknown. However, important insight into the nature of human disease may be understood from the study of experimental-induced colitis in animals. Recently, a novel rat model of experimental colitis by intracolonic administration of the hapten, trinitrobenzene sulfonic acid (TNBS) in the presence of a mucosal barrier breaker as ethanol, has been developed by Morris *et al*³⁾. Macroscopically, the lesions induced by this 50 % ethanolic solution of 30 mg of TNBS include erosions, ulcerations and cobblestone-like appearance lesions of the colonic mucosa where the solution is placed. The lesions persist for at least eight weeks. Transmural inflammation and the development of colon strictures have also been noticed. Microscopically, the inflammatory response includes mucosal and submucosal

infiltration of inflammatory cells and granulomas, as well³⁾.

The chronic inflammation induced by this hapten shares some histological and morphological characteristics with that in humans, particularly, Crohn's disease^{3,4)}. On the other hand, ethanol is very caustic and a potent proinflammatory solvent alone⁵⁾. Furthermore, TNBS itself has shown to be toxic for enterocytes in studies *in vitro*⁶⁾. On the basis of these, it is very important to clarify the role that the chemicals, TNBS and ethanol, play individually and used together in different concentrations inducing colitis in this model.

The objective of this investigation was, first, to set up a rat model of colitis, for further studies of IBD in our laboratory; and second, to study the colonic damage caused by different concentrations of TNBS in ethanol and ethanol alone.

Materials and Methods

Animals

Eleven to twelve-week-old male Wistar rats (Charles River, Japan) weighing 226-387 g were used. The animals were housed in rack-mounted wire cages with a maximum of five animals per cage. The rats were placed in a room with a constant temperature of 21-23°C and 12 hours light/dark cycle and, acclimated for at least one week before the experiment. Standard laboratory pelleted formula was provided. The animals were fasted 48 hours before start the experiment with access to tap water *ad libitum*.

Induction of Colitis

A total of 135 rats was randomized into five major groups, as follows : 1) group I (n = 30) 30 % v/v ethanol alone, 2) group II (n = 30) 40 % v/v ethanol alone, 3) group III (n = 30) 30 % ethanol with 20 mg of TNBS, 4) group IV (n = 30) 40 % ethanol with 42 mg of TNBS and,

5) group V (n = 15) 0.9 % saline solution alone, as control group. The five groups were further subdivided into three subgroups each one that corresponded to the three observation periods : three, fourteen and twenty-one days. As for groups I through IV, every subgroup consisted of 10 rats but for group V only five rats were allocated in each subgroup.

The animals were weighed (initial body weight) and lightly anesthetized with intraperitoneal (ip) injection of 30 mg/kg of pentobarbital sodium. Colitis was induced by intracolonic administration of 0.35 ml of 30 % or 40 % v/v ethanol alone or combined with 20 mg (20 mg/0.35 ml) or 42 mg (42 mg/0.35 ml) of TNBS, respectively. Before the solutions were administered, a colonoscopies were performed using a Olympus-BF type 2J bronchofiberscope (Olympus Co., Japen) to make sure that at least a segment of 6 cm long from the anus was stool-free. The colonic instillations of the solutions were performed by 1-ml syringe to a Swan-Ganz catheter inserted into the colon as the tip was placed in about 6 cm proximal to the anus. After the catheter was placed properly, its tip-balloon was inflated with 2.5 ml of air and 0.35 ml of solution was instilled. One centimeter of air was injected to flush the catheter and it remained placed there for about two minutes, keeping the rat at 45° (head up) position to avoid dispersion of the solution deep into the colon. Finally, the catheter was withdrawn and the rats were kept in their cages until they were sacrificed three, fourteen and twenty-one days later.

Assessment of Colonic Damage

The animals were weighed (final body weight) and sacrificed by intraperitoneal injection of pentobarbital overdose. Laparotomies were performed and the entire colons were removed. The colons were opened by longitudinal incision, weighed, measured, pinned out on a cork block and, assigned a code number. After these procedures were completed, the specimens were examined in a blind fashion and any visible damage was scored on 0 (normal) to 5 (most severe) grade scale (Table 1), as previously described⁹. This procedure was carried out using a stereomicroscope (Olympus Co., Japan) and 25 % methylene blue solution when necessary to detect ulcer scars. Inflammation was defined as regions of bowel wall thickening and hyperemia and when an ulcer was accompanied of these characteristics it was considered "active" in contrast to ulcer scar (healed ulcer). After scoring was done, the specimens were fixed in 10 % formalin for 24 hours. After fixation, at least three tissue samples were excised from each colon, embedded in paraffin and processed routinely. When no grossly visible inflammation was present, the samples were taken from two, four, six and eight centimeters proximal to the anus. One of the samples was taken from the affected region when ulceration or inflammation was detected. Microscopic sections were examined after hematoxylin eosin (H & E) staining in a blind fashion. Histological assessment was performed by light microscopy and the damage was scored on 0 (normal) to 5 (most severe) grade scale, as previously described⁹ with some modifications (Table 2). Either macroscopically or microscopically, acute stage was considered at three days and chronic stage after 14 to 21 days of observation.

Table 1

Criteria for Macroscopical Assessment of Colonic Damage
Score 0 : Normal colonic tissue
Score 1 : Localized hyperemia, but no ulcer or scar
Score 2 : Linear ulcer or ulcer scar with no significant inflammation
Score 3 : Linear ulcer or ulcer scar with inflammation at one site
Score 4 : Two or more sites of ulceration and / or inflammation and ulceration
Score 5 : Two or more sites of ulceration and inflammation or one major site of inflammation and ulceration extending ≥ 1 cm along the length of the colon.

Table 2

Criteria for Microscopical Assessment of Colonic Damage
Score 0 : Normal colonic tissue
Score 1 : Focal ulceration (<1 cm) limited to the mucosa with or without inflammation
Score 2 : Focal or extensive ulceration (≥ 1 cm) limited to the submucosa with mild to moderate inflammation
Score 3 : Focal or extensive ulceration limited to the muscularis propria with moderate inflammation
Score 4 : Focal (<1 cm) ulceration limited to the serosa from moderate to severe inflammation
Score 5 : Extensive (≥ 1 cm) transmural ulceration with perforation or severe inflammation

TABLE 3
Effects of Different Concentrations of TNBS, Ethanol and 0.9 % Saline Solution
on Body Weight, Colon and Bowel Movements of Rats of Groups I to V

GROUP	DAY	IN-BW	FI-BW	MAC-SC	MIC-SC	CL/BW	STOOL CHARACTERISTICS		
							N	D	C
I	3	300± 8	314±16	3.9±1.4	2.9±1.1	0.059±0.004	0.0±0.0	2.8±0.4	0.2±0.4
	14	311±12	385±10	1.7±0.8	1.2±0.4	0.048±0.014	3.4±1.3	9.1±1.2	1.5±1.0
	21	306±31	381±31	1.7±0.8	1.3±0.5	0.055±0.006	6.2±1.7	11.1±0.9	3.9±0.9
II	3	364±12	368±21	3.6±1.1	2.9±1.1	0.053±0.002	0.0±0.0	3.0±0.0	0.0±0.0
	14	345±13	407±18	3.0±1.0	1.7±0.8	0.052±0.002	4.7±1.1	7.9±1.5	1.4±1.3
	21	299± 9	394±12	2.8±0.8	2.0±0.7	0.052±0.001	9.2±1.6	8.5±1.6	2.5±1.6
III	3	312± 6	342±11	3.8±1.3	3.2±1.0	0.057±0.005	0.0±0.0	3.0±0.0	0.0±0.0
	14	279± 8	329±12	3.0±1.2	2.3±1.2	0.060±0.005	1.7±2.4	11.3±2.7	1.0±1.7
	21	289±34	378±18	3.1±0.7	2.3±0.5	0.050±0.005	8.1±1.7	11.9±1.0	1.2±1.3
IV	3	305±31	308±21	4.0±1.1	3.8±1.0	0.011±0.002	0.0±0.0	3.0±0.0	0.0±0.0
	14	354±13	415±17	4.6±0.5	4.3±0.7	0.009±0.001	0.0±0.0	13.8±0.8	7.0±0.8
	21	308±27	391±27	4.7±0.5	3.9±1.0	0.011±0.002	3.9±2.0	14.5±1.6	2.6±1.5
V	3	358± 7	401± 9	0.0±0.0	0.0±0.0	0.054±0.001	3.0±0.0	0.0±0.0	0.0±0.0
	14	361±12	452±13	0.0±0.0	0.0±0.0	0.050±0.001	14.0±0.0	0.0±0.0	0.0±0.0
	21	355± 7	463± 6	0.0±0.0	0.0±0.0	0.048±0.001	21.0±0.0	0.0±0.0	0.0±0.0

IN BW : initial body weight (g) ; FI-BW : final body weight (g) ; MAC-SC : macroscopical damage score ; MIC-SC : microscopical damage score ; CL/BW : colon length/body weight index (cm/g) ; N : normal ; D : diarrhea ; C : constipation.

Statistical Methods

All observations are expressed as mean ± SD. Comparisons of parametric data were performed using Student's t-test for unpaired observations and Mann-Whitney U-test for nonparametric data. With any these analyses, an associated probability (p value) of $\leq 5\%$ was considered as statistically significant.

Results

There was significant ($p \leq 0.05$) and positive correlation between macroscopical and microscopical damage score in all groups and were the best predictors of colonic damage. The colon length/final body weight (CL/BW) index was less sensitive but useful criterion to assess colonic damage (shortening of the colon), mainly in the acute stage (Table 3). Weight loss was observed during the first week (data not shown), but gradually the animals gained weight to reach a normal status by the second to third week of the experiment. Granulomas were not found and, cobblestone-like lesions were unclear and scarcely found at the ethanol and TNBS concentrations used in this experiment.

Time-Course Study

Groups I and II

There was tendency to score higher in group II (40 % ethanol alone) that in group I (30 % ethanol alone) concerning macroscopical and microscopical damage score, however, there was no statistic significance ($p > 0.05$) ; same trend was found regarding to the CL/BW index and intestinal movement disturbances (Table 3). These features were observed during the three observation periods. Macroscopically, in acute stage, all rats of both groups showed active ulcers (Table 4), hemorrhage, inflammation and bowel wall thickening around the ulcers (Fig 7). No active ulcer or inflammation was detected in both groups in the chronic stage, but ulcer scars were often observed (Table 4). Microscopically, vasocongestion, hemorrhage and necrosis were found. Infiltration of inflammatory cells, particularly neutrophils and lymphocytes, into the mucosa layer through muscularis propria or serosa according to the severity of the damage (ulcer depth or extension of inflammation) were observed (Fig 8 and Fig 13 for comparison with histologically normal rat colon). Fibrosis, mainly in the submucosa, but no granulomas, was found in the chronic stage (Table 4).

Table 4

Time-Course Distribution of Active Ulcers and Ulcer Scars in the Rat Colons Treated With Different Concentrations of TNBS in Ethanol and Ethanol Alone in the Groups I to IV

GROUP	DAY	ACTIVE ULCER (%)	ULCER SCAR (%)
I	3	10 (100)	0 (0)
	14	0 (0)	10 (100)
	21	0 (0)	10 (100)
II	3	10 (100)	0 (0)
	14	0 (0)	10 (100)
	21	0 (0)	10 (100)
III	3	10 (100)	0 (0)
	14	6 (60)	4 (40)
	21	5 (50)	5 (50)
IV	3	10 (100)	0 (0)
	14	9 (90)	1 (10)
	21	8 (80)	2 (20)

There was clear tendency of the ulcers to remain active in the chronic stage (after 14 to 21 days) when the ethanolic solution contained TNBS in dose-dependent fashion. The higher the concentrations of TNBS and ethanol, the more number of ulcers remaining active (see text).

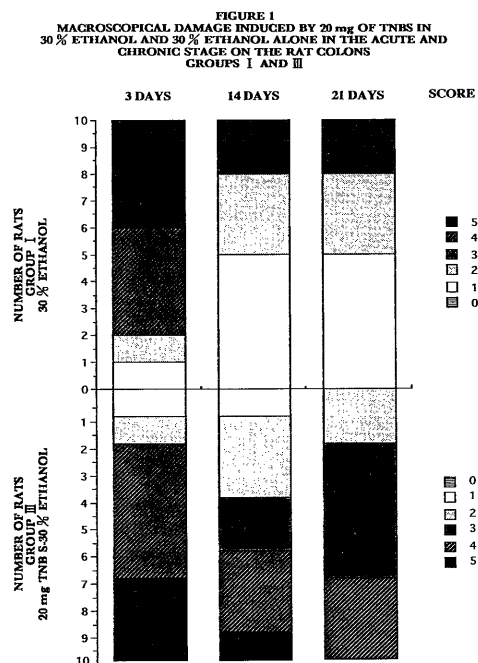


Fig. 1 Upper panel: Group I. Lower panel: Group III. There was significant difference ($p \leq 0.05$) between the macroscopical damage in the group I and group III in the chronic stage (after 14 to 21 days), but not in the acute stage (after 3 days, $p > 0.05$). The damage was more severe in the group III.

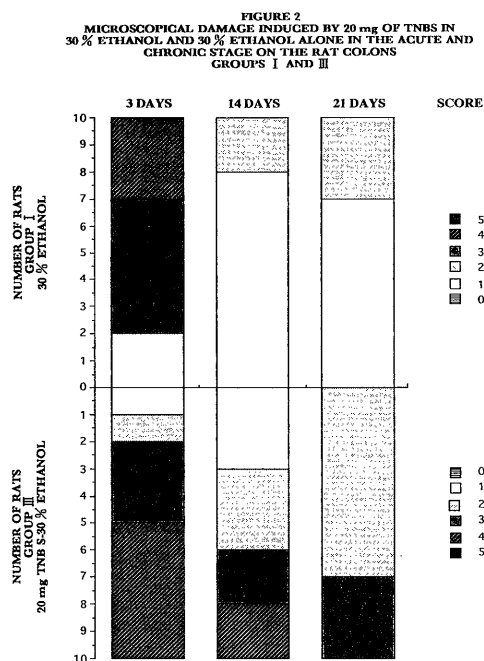


Fig. 2 Upper panel: Group I. Lower panel: Group III. There was significant difference ($p < 0.05$) between the microscopical damage in the group I and group III in the chronic stage (after 14 to 21 days), but not in the acute stage (after 3 days, $p > 0.05$). The damage was more severe in the group III.

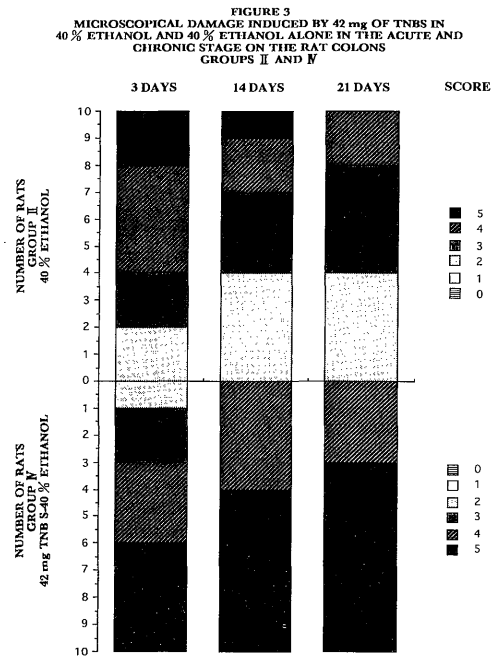


Fig. 3. Upper panel : Group II . Lower panel : Group IV . There was significant difference ($p > 0.05$) between the macroscopical damage in the group II and group IV in the chronic stage (after 14 to 21 days), but not in the acute stage ($p > 0.05$). The damage was more severe in the group IV.

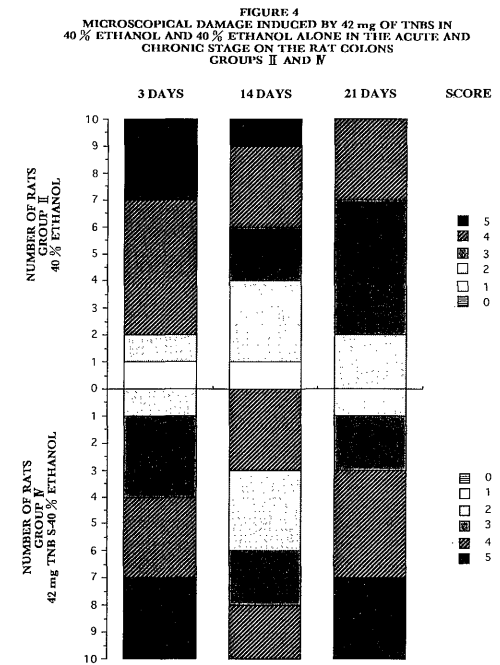


Fig. 4. Upper panel : Group II . Lower panel : Group IV . There was significant difference ($p \leq 0.05$) between the microscopical damage in the group II and IV in the chronic stage (after 14 to 21 days), but not in the acute stage ($p > 0.05$). The damage was more severe in the group IV.

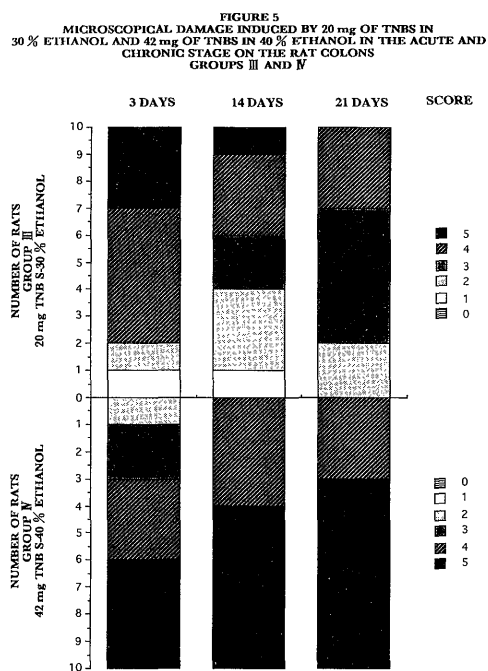


Fig. 5. Upper panel : Group III . Lower panel : Group IV . There was significant difference ($p \leq 0.05$) between the macroscopical damage in the group III and IV in the chronic stage (after 14 to 21 days), but not in the acute stage ($p > 0.05$). The damage was more severe in the group IV.

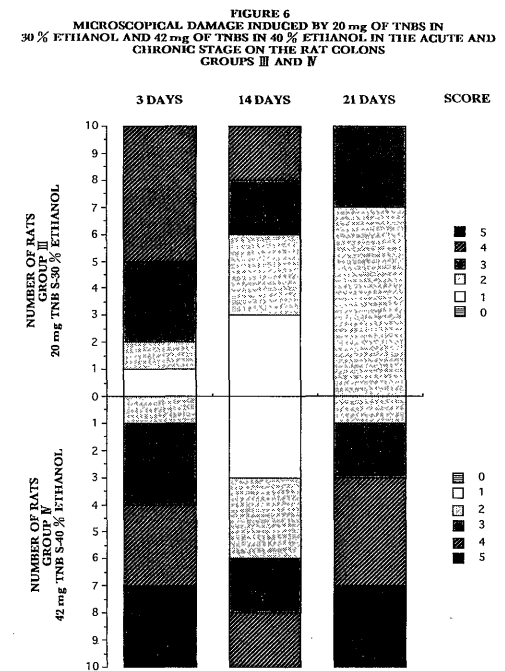


Fig. 6. Upper panel : Group III . Lower panel : Group IV . There was significant difference ($p \leq 0.05$) between the microscopical damage in the group III and IV in the chronic stage (after 14 to 21 days), but not in the acute stage ($p > 0.05$). The damage was more severe in the group IV.

Groups I and III

All the animals that received 20 mg of TNBS in 30 % ethanol (group III) developed areas of grossly visible bowel wall thickening, inflammation and ulcers (Fig 9a and Fig 9b). Such ulcers (active ulcers) were covered by a whitish or yellowish pseudomembrane. These ulcers persisted for 14 to 21 days (Table 4). The macroscopical and microscopical damage scores (Fig 1 and Fig 2) and CL/BW index were higher ($p \leq 0.05$) in the group III than group I in chronic stage but not in the acute (Table 3). Microscopically, the group III showed features that were almost same as those of the group I (and group II, as well) in the acute stage but different to those of the chronic stage ($p \leq 0.05$) (Table 3). In the chronic stage,

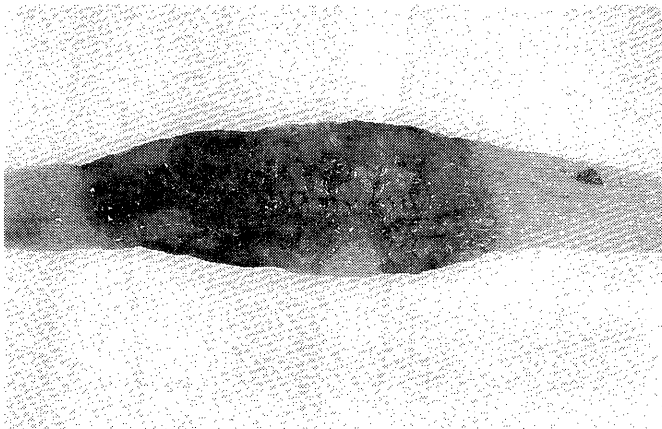


Fig. 7 Huge colonic ulcer (score 5) covered by necrotic tissue and hemorrhagic areas induced by 40 % ethanol (group II) in the acute stage (after 3 days).




Fig. 8 Microscopical damage induced by 40 % ethanol (group II) in the acute stage (after 3 days). There is complete destruction of the mucosa and muscularis mucosa (score 2). The ulcer, limited to the sub-mucosa, is covered by necrotic tissue (arrowhead). The inflammatory cell infiltration is composed, mainly, of neutrophils and lymphocytes. (H&E staining, original magnification x25).

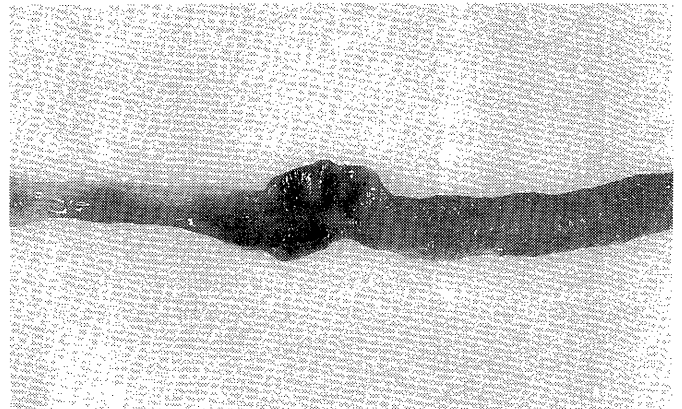


Fig. 9a Chronic ulceration (after 14 days, score 5) induced by 20 mg of TNBS in 30 % ethanol (group III). Notice the gross visible thickening of the bowel wall and active inflammation.

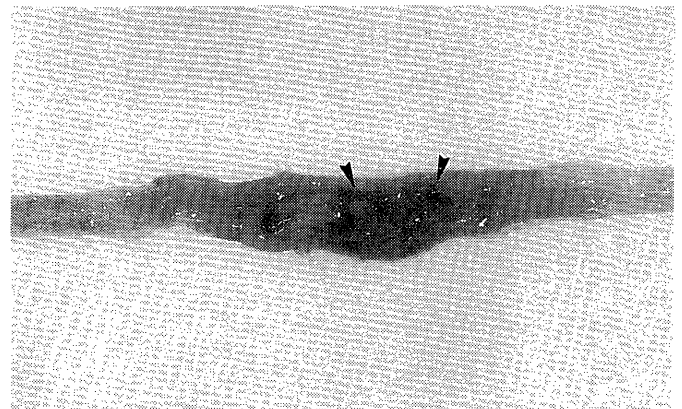


Fig. 9b Linear ulcer scar (score 3) induced by 30 % ethanol alone (group I) in the chronic stage (after 14 days). Notice the linear ulcer scar (arrowheads).

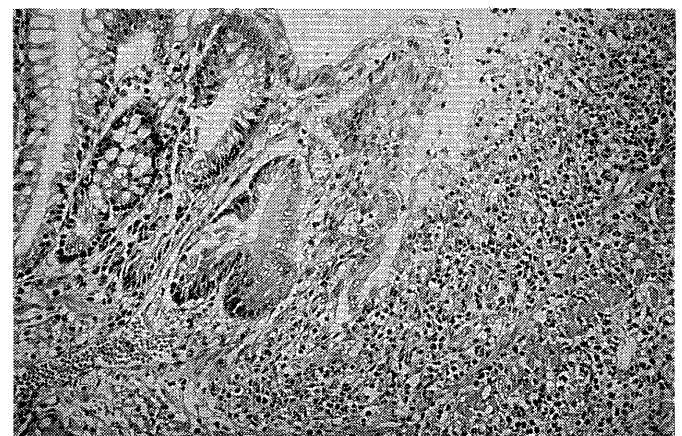


Fig. 10 Microscopical damage (score 3) induced by 20 mg of TNBS in 30 % ethanol in chronic stage (after 14 days). On the right side, notice that the mucosa was completely disrupted and the inflammatory cell infiltration was composed, mainly, of lymphocytes and eosinophils with scarce neutrophils. (H&E staining, original magnification x50).

the inflammatory cell infiltration was composed, mainly by neutrophils, lymphocytes and eosinophils (Fig 10). Fibrosis was slightly more common in the group I. There was clear tendency to show more bowel movement disturbances (diarrhea and/or constipation) in the chronic stage in the rats of the group III (Table 3).

Groups II and IV

The rats that were challenged to 42 mg of TNBS in 40 % ethanol (group IV) developed ulcers surrounded by inflammation and bowel wall thickness. Macroscopically, these lesions persisted after 14 to 21 days of administration of the ethanol and TNBS solutions (Table 4). In the acute stage, there was no difference between the colonic damage

of the groups II and IV ($p > 0.05$) but higher microscopical damage score ($p \leq 0.05$) (Fig 3 and Fig 4) was recorded in the chronic stage (Fig 11a and Fig 11b). Microscopically, in the acute stage both groups II and IV showed same features, inflammation, ulceration and necrosis. In contrast, in the chronic stage fibrosis was common in the groups II but in the group IV inflammation and ulcers, surrounded by inflammatory cells, were frequently found (Fig 11c and Fig 11d).

Groups III and IV

The characteristics of the ulcers and their distribution pattern in the colon were similar in both groups. However, concerning to the severity of the damage (Fig 5 and 6),




Fig. 11a Linear ulcer scar (score 2) induced by 40 % ethanol alone (group II) in the chronic stage (after 14 days). The linear ulcer scar encircles a portion of normal mucosa (arrowheads).




Fig. 11b Chronic active ulceration (score 5) induced by 42 mg of TNBS in 40 % ethanol (group IV) in the chronic stage (after 14 days).

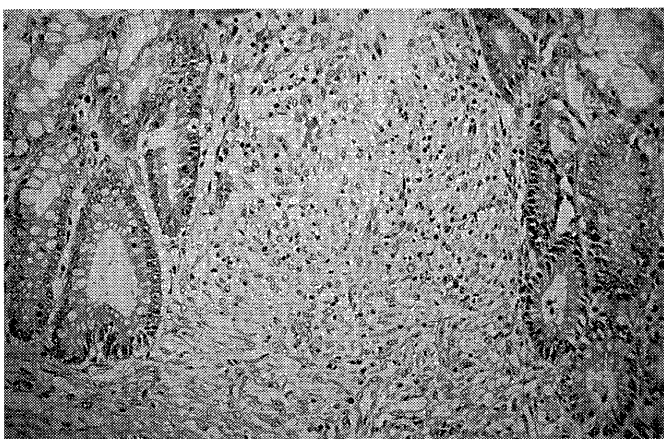


Fig. 11c Microscopical damage (score 2) induced by 40 % ethanol alone in the chronic stage (after 14 days). Notice the ulcer scar in the remaining mucosa and the presence of fibrous tissue, fibroblasts and lymphocytes. (H&E staining, original magnification x50).

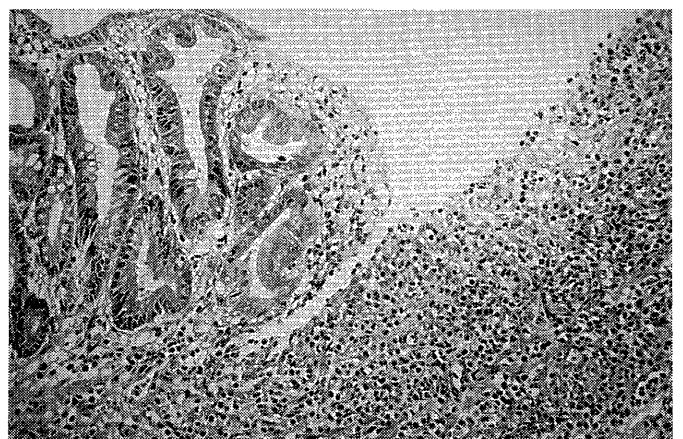


Fig. 11d Microscopical damage (score 5) induced by 42 mg of TNBS in 40 % ethanol in the chronic stage (after 14 days). Notice the abundant lymphocytes, eosinophils and, the scarce neutrophils and fibroblasts. On the left side, the remaining glands are deformed and depleted of goblet cells. (H&E staining, original magnification x50).

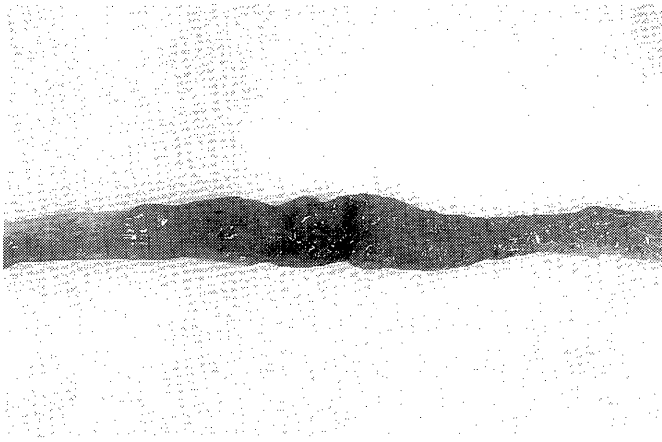


Fig. 12a Chronic active ulceration (score 4) induced by 20 mg of TNBS in 30 % ethanol (group III) in the chronic stage (after 21 days).

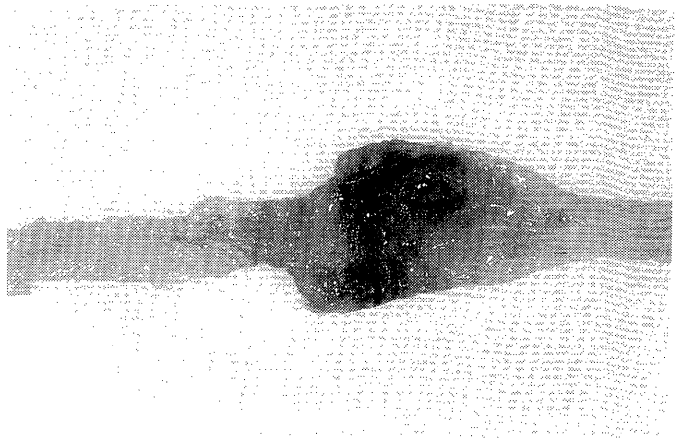


Fig. 12b Chronic active ulceration (score 5) induced by 42 mg of TNBS in 40 % ethanol (group IV). Notice the extensive damage induced by these concentrations of ethanol and TNBS remaining for 21 days.

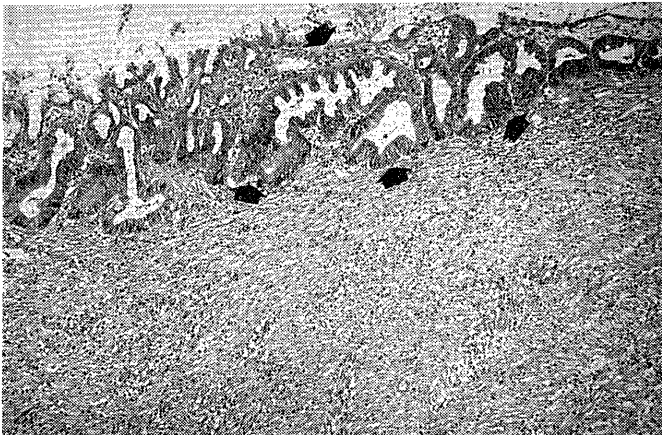

Fig. 12c Microscopical damage (score 2) induced by 20 mg of TNBS in 30 % ethanol in the chronic stage (after 21 days). The remaining glands are deformed with depletion of goblet cells (arrows). In the submucosa, there are fibrous tissue accompanied by lymphocytes and eosinophils (H&E staining, original magnification x25).




Fig. 12d Microscopical damage (score 3) induced by 42 mg of TNBS in 40 % ethanol in the chronic stage (after 21 days). The remaining glands are deformed with depletion of goblet cells (arrowhead) and the mucosa layer has been substituted by fibrous tissue accompanied by abundant lymphocytes, eosinophils, fibroblasts and scarce neutrophils. (H&E staining, original magnification x25).

either macroscopically or histopathologically, the group IV scored higher ($p \leq 0.05$) than the group III (Fig 12a and Fig 12b) and the other groups as well. In other words, the higher the concentrations of TNBS and ethanol, the more severe the damage scored. Clinically, the rats of the group IV showed more bowel movement disturbances (diarrhea) than those of the group III ($p \leq 0.05$) (Table 3). No rats died due to colitis and, strictures and perforations were rare. Microscopically, in the acute and chronic stage there was difference between both groups concerning to the composition of the inflammatory cell infiltration, but its severity was related with the ethanol and TNBS concentrations in dose-dependent fashion. In the chronic stage the

inflammatory cell infiltration was composed, mainly, of lymphocytes, eosinophils, fibroblasts and neutrophils, although the last ones in less amount. In contrast, in the acute stage neutrophils and lymphocytes were predominant (Fig 12c and Fig 12d). Eosinophils were scarcely present.

Group V

Intraluminal administration of 0.9 % saline solution did not induce either macroscopically or histopathologically detectable damage (Fig 13). It was a clear-cut ($p \leq 0.05$) between the control group V and the other groups (Table

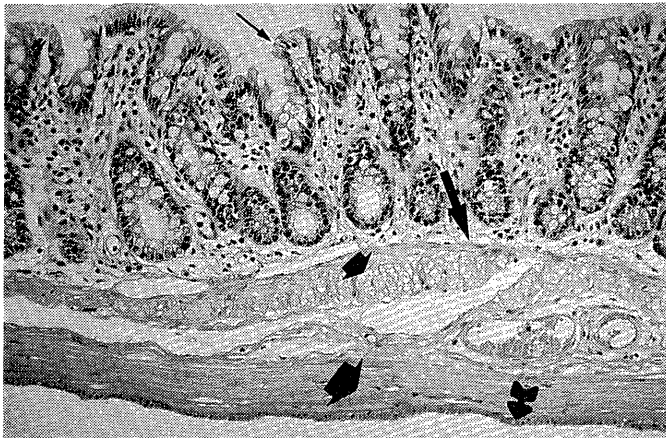


Fig. 13 Normal rat colon. Normal glands composed, mainly, of absorptive and goblet cells. Notice in the lamina propria, the normal presence of scarce inflammatory cells, mainly lymphocytes. Five layers are clearly showed (from the top to the bottom): mucosa (small arrow), muscularis mucosa (large arrow), submucosa (small-solid arrow), muscularis propria (large-solid arrow) and serosa (tailed arrow). (H&E staining, original magnification x50).

3) concerning to the bowel movement disturbances (diarrhea and constipation). As expected, all rats of the group V had normal bowel movements.

Discussion

Intracolonic instillation of TNBS dissolved in ethanol induced acute and chronic inflammation and ulceration of the colon where this solution was placed. These results are in agreement with those of Morris *et al*³⁰ and other authors^{1,4,5,7-9}. The severity of the colonic damage was dose-dependent. In the acute stage, it seems that ethanol plays the most important role inducing inflammation and/or ulceration, because neither inflammation nor ulceration was found in the chronic stage when the rats were challenged to the ethanol alone. On the other hand, the chronic inflammation and/or ulceration were only found in the rats challenged to the TNBS in ethanol. In all instances, the higher the concentrations of ethanol and TNBS used, the more severe the colonic injury induced. Previous preliminary studies carried out in our laboratory (unpublished data) demonstrated that the TNBS alone is unable to induce such damage, as reported by others³⁰. These emphasize the requirement of a mucosal breaker (ethanol) to induce the chronic inflammation in this model.

In the acute stage, the rats of all groups showed inflammation, ulceration and hemorrhage. There was no significant difference concerning to the macroscopical and microscopical features among them in this stage.

In the chronic stage, macroscopically, the inflammation and ulceration induced by this hapten in the presence of ethanol were located on the instillation point and around it (about 6 cm from the anus). Histologically, the rats challenged to ethanol alone showed fibrosis and a moderate inflammatory cell infiltration. The inflammatory cells, namely, neutrophils, eosinophils and lymphocytes, were more abundant when the ethanol solution contained the TNBS. Fibrosis, but no granulomas, was also found. Strictures and cobblestone-like lesions were infrequently found at the ethanol and TNBS concentrations used in this experiment. There was a clear tendency of the rats of all groups to have bowel movement disturbances, diarrhea and/or constipation, during the experiment. These were more remarkable among the rats challenged to the TNBS in the presence of ethanol in the chronic stage.

Clinically, IBD is a very problematic entity and its etiology remains obscure. Appropriate experimental models would be most useful in elucidating both their pathogenesis and treatment. At this point, it is appropriate to confront the question of what constitutes an ideal animal model of IBD. The ideal model should be a naturally occurring animal disease that is identical in every aspect to the human disease. This means that the animal disease is induced and maintained by the same primary factors (has the same cause) and secondary factors (has the same pathophysiology), has an equivalent clinical spectrum, and is treatable with therapeutic agents. Furthermore, the ideal model must be a practical study tool, namely, easy accessibility and easy experimental manipulation and, inexpensive as well^{10,11}. The animal model presented herein does not fulfill all these criteria; however, it is attractive one for study chronic colitis. Three highlight features should be mentioned concerning to its usefulness³⁰, as follows: 1) the inflammation and ulceration are induced by a single intraluminal administration, with no requirement for previous sensitization of the animal or for surgery and, the severity and persistence of the damage are very reproducible, 2) because the animal used is the rat, the model is relatively inexpensive and, 3) the inflammation induced by the TNBS in ethanol is long-standing, associated with inflammatory cell infiltration and ulcers that allows to study potential treatments. In addition, histopathologically, this model shares some characteristics with human IBD, particularly Crohn's disease. For example, the inflammation is chronic and transmural and although we did not find granulomas using these TNBS and ethanol concentrations, they have been described by others³⁰. Furthermore, the damaged mucosa may show a "cobblestone" like appearance using higher concentrations of ethanol (50%) as reported by Morris *et al*³⁰.

Finally, it is important to emphasize that this study has some limitations. For instance, we did not study in detail the inflammatory process itself by techniques such as

myeloperoxidase activity^{8, 12)} nor quantified the composition of the inflammatory cell infiltration, such as subset of lymphocytes, mast cells and eosinophils. On the other hand, the animal model itself has its own limitations. For example, the mechanism(s) by which the TNBS in the presence of ethanol damage the rat colon is poorly understood. It is speculated that the mechanism is by macrophage-mediated recognition and lysis of the TNBS-modified autologous cells within the mucosa^{6, 7)}. In the experiment presented herein, the presence of abundant eosinophils infiltrating, mainly, in the mucosa and submucosa of the colon, particularly in the chronic stage, support the theory of immunologic pathways as an important factor concerning to the pathophysiology of the chronic inflammation in this model. On the other hand, Grisham *et al*⁶⁾ have demonstrated that the TNBS alone is metabolized by certain colonic enzymes and substrates to yield both proinflammatory and cytotoxic oxidants that could induce colonic inflammation. In this status quo, the mechanisms by which IBD naturally occur in humans may be different from those in this animal model. Extensive research is going on in our laboratory concerning to experimental models for IBD, however further studies are needed to find out the best one.

In conclusion, 30% or 40% ethanol alone induces, mainly caustic, acute damage to the rat colon; but 20 mg or 42 mg of the TNBS in the presence of either 30% or 40% ethanol causes, probably toxic and/or immunologic-mediated, acute and chronic inflammation and ulceration in a dose-dependent fashion. It makes this model suitable for further studies related to the intestinal inflammation process or during repair.

ACKNOWLEDGMENTS

The authors wish to thank Mr. Yoshihiro Ide and Mr. Toshiyuki Kawata for their excellent technical assistance.

References

- 1) Hoshino H, Sugiyama S, Ohara A, *et al*: Mechanism and prevention of chronic colonic inflammation with trinitrobenzene sulfonic acid in rats. *Clin Exp Pharmacol and physiol* 19: 717-722, 1992.
- 2) Sleisenger MF, Fortran JS: *Gastrointestinal disease: Pathophysiology, Diagnosis, Management*, 4th ed., p. 1435. WB Saunders, Philadelphia 1989.
- 3) Morris GP, Beck PL, Herridge MS, *et al*: Hapten-induced model of chronic inflammation and ulceration in the rat colon. *Gastroenterology* 96: 795-803, 1989.
- 4) Shibata Y, Ashida T, Ayabe T, *et al*: Endoscopic evaluations of experimental colitis in rat induced by a hapten. *Gastroenterol Endosc* 33: 1122-1127, 1991 (In Japanese).
- 5) Wallace JL, Whittle BJR, Boughton-Smith NK: Prostaglandin protection of rat colonic mucosa from damage induced by ethanol. *Dig Dis Sci* 30: 866-876, 1985.
- 6) Grisham MB, Volkmer C, Tso P, *et al*: Metabolism of trinitrobenzene sulfonic acid by the rat colon produces reactive oxygen species. *Gastroenterology* 101: 540-547, 1991.
- 7) Yamada T, Marshall S, Specian RD, *et al*: A comparative analysis of two models of colitis in rats. *Gastroenterology* 102: 1524-1534, 1992.
- 8) Vilaseca J, Salas A, Guarner F, *et al*: Participation of thromboxane and other eicosanoid synthesis in the course of experimental inflammatory colitis. *Gastroenterology* 98: 269-277, 1990.
- 9) Vilaseca J, Salas A, Guarner F, *et al*: Dietary fish oil reduces progression of chronic inflammatory lesions in a rat model of granulomatous colitis. *Gut* 31: 539-544, 1990.
- 10) Strober W: Animal models of inflammatory bowel disease- an overview. *Dig Dis Sci (Supplement)* 30: 3 S-10 S, 1985.
- 11) Kim HS, Berstand A: Experimental colitis in animal models. *Scand J Gastroenterol* 27: 529-537, 1992.
- 12) Krawisz JE, Sharon P, Stenson WF: Quantitative assay for acute intestinal inflammation on based on myeloperoxidase activity. Assessment of inflammation in rat and hamster models. *Gastroenterology* 87: 1344- 1350, 1984.