

Arachis hypogaea (PNA) Lectin Binding Affinity to *Candida Parapsilosis* in Histologic Sections

Masachika SENBA,* and Kiwao WATANABE**

*Department of Pathology, Institute of Tropical Medicine, Nagasaki University

**Department of Internal Medicine, Institute of Tropical Medicine, Nagasaki University

Summary: A battery of 8 peroxidase-labeled lectins was tested on sections of paraffin-embedded human tissues to determine which lectin could be used in the microscopic diagnosis of *Candida parapsilosis*. The peroxidase-labeled lectin histochemistry was more clearly in identifying *Candida parapsilosis* than fluorescein isothiocyanate (FITC)-labeled lectins. One lectin, from *Arachis hypogaea* (PNA) was found to react with *Candida parapsilosis*. Seven lectins, from *Triticum vulgare* (WGA), *Ulex europaeus* (UEA-1), *Ricinus communis* (RCA-120), *Dolichos biflorus* (DAB), *Phaseolus vulgaris* (PHA-E), *Lens culinaris* (LCA), and *Canavalin eniformis* (Con A) did not react stained with *Candida parapsilosis*.

Introduction

Candidiasis is the most widespread and prevalent of the mycotic diseases of man. This is especially true in the infections caused by the endogenous species, *Candida albicans*. Candidiasis is usually caused by *Candida albicans*, and occurs predominantly in patients who require treatment with antibacterial antimicrobial, glucocorticoids, or immunosuppressive drugs. Almost all cases of oropharyngeal, gastrointestinal, vaginal, systemic, and cutaneous candidiasis are caused by *Candida albicans*, although an increasing prevalence of *Candida tropicalis* has been noted in immunocompromised patients. *Candida parapsilosis*, *Candida tropicalis*, and *Candida guilliermondii* have become important causes of endocarditis, pyelonephritis, and disseminated candidiasis in patients with indwelling intravenous catheters, patients undergoing cardiovascular surgery, and drug addicts.

For the purpose of identification of fungi in paraffin-embedded tissue sections, periodic acid Schiff (PAS) method, Grocott's methenamine silver method, calcofluor white method,^{9,10} ultraviolet illumination method,^{2,5,8,11-16} fluorescein isothiocyanate-labeled (FITC-labeled) lectin method,^{6,19} peroxidase-labeled lectin method,^{17,18} and biotin-labeled lectin method¹⁾ have been reported.

In the present study, the authors used 8 different lectins to analyze carbohydrate residues of fungi. In the course of our histochemical studies designed to test the diagnostic

value of lectins. Specifically, we have noticed that *Arachis hypogaea* (PNA) lectin reacted with *Candida parapsilosis*, but other fungi were not reacted.

Materials and Methods

The specimens were obtained from biopsy and autopsy materials at the Nagasaki University Hospital. Confirmation of fungal morphology was provided with periodic acid Schiff (PAS), and Grocott's methenamine silver (GMS). Hematoxylin-eosin, and only eosin stained sections were used for examination using transmitted light fluorescence microscope (Zeiss, Germany). Unfixed materials were cultured for fungal species. Morphologically, fungi were identified by light and fluorescence microscope as *Candida*, *Aspergillus*, *Mucor*, and *Cryptococcus*. These fungal infected paraffin-embedded tissue sections were cut at 4 micron and stained with peroxidase-labeled lectins such as *Triticum vulgare* (WGA), *Ulex europaeus* (UEA-1), *Arachis hypogaea* (PNA), *Ricinus communis* (RCA-120), *Dolichos biflorus* (DAB), *Phaseolus vulgaris* (PHA-E), *Lens culinaris* (LCA), and *Canavalin eniformis* (Con A).

The steps involved in peroxidase-labeled lectins for fungi are the following: (1) Deparaffinize and hydrate to distilled water. (2) Treat with bath phosphate buffer saline (PBS) pH 7.2 for 10 minutes. (3) Treat with peroxidase-labeled lectins for one hour in moisture chamber at room temperature. (4) Treat with bath PBS, 3 changes of 5 minutes each. (5) Wash in distilled water. (6) DAB/H₂O₂ substrate 10 minutes. (7) Wash in distilled water. (8) Perform nuclear stain in hematoxylin. (9) Wash in running water. (10) Dehydrate, clear and mount. The peroxidase-labeled lectins were purchased from Honnen Oil Company, Tokyo, Japan as a solution.

Results

Unfixed materials were cultured and were diagnosed *Can-*

didia albicans and *Candida parapsilosis*. *Candida albicans*, *Candida parapsilosis*, *Aspergillus*, *Mucor*, and *Cryptococcus* were stained with periodic acid Schiff (PAS) (Fig. 1), and Grocott's methenamine silver (GMS) methods. *Candida albicans*, *Aspergillus*, *Mucor*, and *Cryptococcus* have been found to fluorescence in hematoxylin-eosin and/or only eosin stained tissue sections when exposed ultraviolet illumination, however, *Candida parapsilosis* has not been fluorescence. *Candida parapsilosis* was reacted with *Arachis hypogaea* (PNA) (Fig. 2), however, other fungi were not reacted with *Arachis hypogaea* (PNA), *Candida parapsilosis* was not reacted with other 7 peroxidase-labeled lectins. *Candida albicans*, *Aspergillus*, *Mucor*, and *Cryptococcus* were stained with *Richinus communis* (RCA-120), *Lens culinaris* (LCA), *Ulex europaeus* (UEA-1), *Canavalin eniformis* (Con A), and *Triticum vulgare* (WGA). These fungi were negatively stained with *Arachis hypogaea* (PNA), *Phaseolus vulgaris* (PHA-E), and *Dolichos biflorus* (DAB).

Discussion

Lectins are proteins or glycoproteins of non-immune origin that can bind carbohydrate residues in a very specific way. Cellular glycoconjugates consist of carbohydrate-rich molecules, including glycoproteins and glycolipids, that are widely distributed intracellularly, on the cell surface coat, and in the extracellular matrix. Currently lectins conjugated to a visulant are used as histochemical reagents to identify and localize specific carbohydrate residues in normal and abnormal tissues, and from the application of lectins as simple and selective tools for the detection of carbohydrate groups. The cell wall of most fungi contains glycolipids, glycoproteins, lipopolysaccharides, and other complex glycoconjugates. Their specificity in recognizing carbohydrates is higher than obtained with other histochemical methods, thus lectins can be as probes to study glycoconjugate expression in the normal and disease tissues.⁷⁾

In view of the fact that lectin histochemistry has not been widely used in diagnostic pathology. Several investigators reported that fluorescein isothiocyanate (FITC)-labeled lectins could be used for morphologic diagnosis of fungal infection in routinely processed tissue sections.^{6,19)} On the other hand, the author first described that peroxidase-labeled lectins could be used in the microscopic diagnosis of fungi in sections of paraffin embedded human tissues. Some fungi are autofluorescence in paraffin-embedded tissue under ultraviolet illumination, thus, I wonder what part fungal autofluorescence plays in the observed reaction of fungi with fluorescein isothiocyanate (FITC)-labeled lectins in ultraviolet light. On the other hand, peroxidase-labeled lectins could be used to detect glycoconjugate in fungi in sections of paraffin-embedded tissues. Therefore,

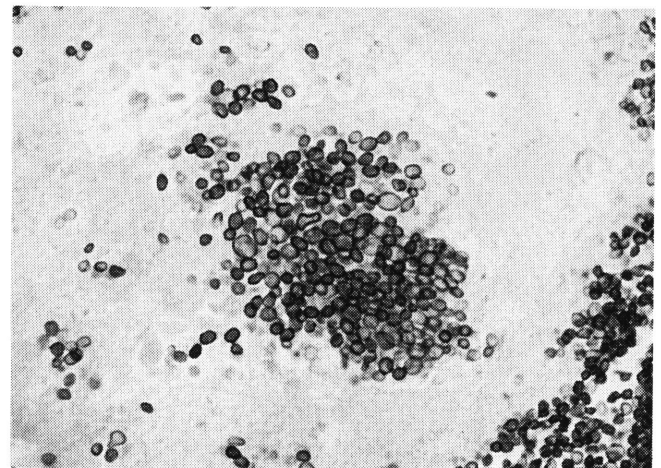


Fig. 1. *Candida parapsilosis* yeast form is observed in the myocardium. Periodic acid Schiff (PAS) stain, $\times 400$.

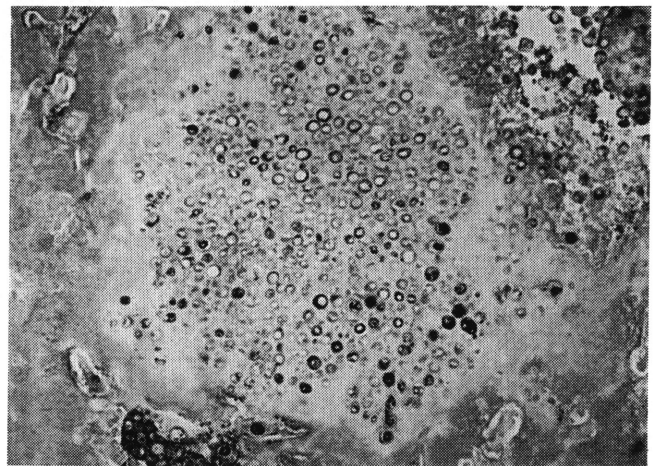


Fig. 2. *Candida parapsilosis* yeast form is reacted with *Archis hypogaea* (PNA). Peroxidase-labeled lectin for *Arachis hypogaea* (PNA) stain, $\times 400$.

we concluded that peroxidase-labeled lectins were more specific than fluorescein isothiocyanate (FITC)-labeled lectins.

All *Candida* elements are stained with periodic acid Schiff (PAS). Grocott's methenamine silver method is also satisfactory for demonstrating *Candida*. If only yeast form of *Candida* are seen, they may be confused with morphologically similar yeast form in tissues. Hyphae of *Candida* may resemble *Aspergillus* and other filamentous fungal in tissues. In such instance, cultures are required for a differential identification to be made. The particular species that in present can be identified by histologic examination. For this reason, culture studies should be done when possible. Moreover, the more virulent species (*Candida albicans* var. *albicans*, *Candida albicans* var. *stellatoidea*, and *Candida tropicalis*) showed both yeast and hyphae forms in tissues. The less virulent, but still pathogenic, species (*Candida parapsilosis*, *Candida gillermondii*, *Candida kru-*

sei, *Candida pseudotropicalis*, *Candida viswanthii*, *Candida zeylanoides*, and *Candida paratropicalis*) showed only yeast form in tissues.

References

- 1) Biavati SB: Lectin histochemistry of fungi in formalin-fixed paraffin-embedded tissue sections. *Arch. Pathol. Lab. Med.*, 114:351, 1990.
- 2) Friedman H, Raick AN: Autofluorescence of South American blastomycosis less sensitive than stain. *Am. J. Clin. Pathol.*, 81:540, 1984.
- 3) Gonzales NF, Brown RW, Bthathan PS: Fluorescence of fungi-not autofluorescence. *Am. J. Clin. Pathol.*, 81:142, 1984.
- 4) Graham AR: Fungal autofluorescence with ultraviolet illumination. *Am. J. Clin. Pathol.*, 79:231-234, 1983.
- 5) Graham AR: The author's reply. *Am. J. Clin. Pathol.*, 81:142-143, 1984.
- 6) Karayannopoulou G, Weiss J, Damjanov I: Detection of fungi in tissue sections by lectin histochemistry. *Arch. Pathol. Lab. Med.*, 112:746-748, 1988.
- 7) Leather A: Lectin histochemistry. In immunohistochemistry: Modern methods and applications. Edited by Polak JK and Noorden SV, 2nd ed, Wright, Bristol, 167-187, 1986.
- 8) Mann JL: Autofluorescence of fungi: An aid to detection in tissue sections. *Am. J. Clin. Pathol.*, 79:587-590, 1983.
- 9) Monheit JE, Cowan DF, Moore DG: Rapid detection of fungi in tissue using calcofluor white and fluorescence microscopy. *Arch. Pathol. Lab. Med.*, 108:616-618, 1984.
- 10) Monheit JE, Brown G, Kott MM, Schmidt WA, Moore DG: Calcofluor white detection of fungi in cytopathology. *Am. J. Clin. Pathol.*, 85:222-225, 1986.
- 11) Pappolla MA: Fungal autofluorescence. *Am. J. Clin. Pathol.*, 81:407, 1984.
- 12) Senba M, Yamashita H: Autofluorescence of *Rhinosporidium seeberi*. *Am. J. Clin. Pathol.*, 83:132, 1985.
- 13) Senba M, Kitano M: A rapid procedure for identification of *Candida* in histologic sections with ultraviolet illumination. *Bull. Ginkyo Coll Med. Sci.*, 12: 7-12, 1988.
- 14) Senba M: Fluorescence of mucormycosis. *Am. J. Clin. Pathol.*, 90:229, 1988.
- 15) Senba M, Kawai K: Autofluorescence of *Tricosporon beigeli*. *Revista Lat-amer. Microbiol.*, 31:131-132, 1989.
- 16) Senba M, Toda T, Toda Y, Hokama S: A reliable differentiation of *Mucor* from *Aspergillus* in tissue sections with ultraviolet illumination. *Acta Med. Nagasaki.*, 34:147-148, 1989.
- 17) Senba M: Lectin histochemistry of fungi. *Arch. Pathol. Lab. Med.*, 113:327-328, 1989.
- 18) Senba M: Detection of fungi in tissue sections using peroxidase-labeled lectins. *Acta Med. Nagasaki.*, 35:74-76, 1990.
- 19) Stoddart RW, Herbertson BM: The use of fluorescein-labeled lectins in the detection and identification of fungi pathogenic for man: A preliminary study. *J. Med. Microbiol.*, 11:315-329, 1978.