

## Clinical Experience with Button battery ingestion in infant

Hozumi SHIMODA, Nobuko KUROSAKI, Atushi SAKAI, Masao TOMITA,  
Osamu SOEDA, Satoru HASHIMOTO, Shigehiko ITO,  
Hiroshi ISHIKAWA, Shimei OH, Takaaki KAWABUCHI,  
Tetsuya SATO, Haruhiko NAKAO, Enju SHIRAIISHI,  
Shinsuke HARA, Taizo FURUKAWA, Ryuichiro SHIBATA

*1st Dept. of Surgery*

*Nagasaki University School of Medicine*

Received for publication, July 18, 1986

Recent expansion of use of button battery has not infrequently given rise to its ingestion in infant, alarming the toxicity.

Expeditious removal has advocated for fear of grave complications based on this accident. The button batteries extracted in this series showed that there was no severe damage to the surfaces and capsules in proportion to the transit time and the time staying in the stomach.

It is highly likely that careful observation by daily roentgenogram is needed for management without immediate surgical intervention even if left to pass the button cells through the gastrointestinal tract.

### INTRODUCTION

Particular attention was centered on the alkaline battery ingestion in infant. There are some reports regarding perforation of the digestive tract secondary to button battery ingestion infant.<sup>1)</sup>

Much has been said that the risks of undue obstruction and perforation due to foreign body ingestion must be weighed and attention to the aspect of the operative indication must be focused in the infant cases.<sup>2)3)</sup>

With recent expansion of the use of alkaline button battery, the authors focused attention on the fact that the chance to manage the infants with button battery ingestion

---

下田 穂積, 黒崎 伸子, 酒井 敦, 富田 正雄, 添田 修, 橋本 哲, 伊藤 重彦,  
石川 啓, 王 志明, 川淵 孝明, 佐藤 哲也, 中尾 治彦, 白石 円樹, 原 信介,  
古川 泰蔵, 柴田隆一郎

is now increasing and chemical agent of alcali in a button battery has so potent a corrosive action against the digestive tract mucosa that it at times tends to result in perforation.

The purpose of the study is to clarify the clinical features of button battery ingestion in infant on the basis of our experience.

PATIENT

Table 1 showed the 3 infants with button battery ingestion experienced in 1st Department of Surgery, Nagasaki University School of Medicine. Age ranged from 8m to 2 years, 1 boy and 2 girls.

The type of the 3 ingested batteries were Toshiba LR44, Sony alcali A 76 and 186 type respectively.

The time before the patients consulted their doctors was between 1 hour, and 3 and half.

**Table 1.** Patient with buttom battery ingestion

case age	sex	battery	duration of consultation	duration of extraction	symptome
8m	F	Toshiba LR44	3 h	8.5h	(-)
1 y	M	Sony A76	3.5h	4.5h	(-)
2 y	F	Sony 186	1 h	18h	(-)

All were asymptomatic and no complaint of vomiting, diarrhea and skin rash. The ingested batteries were surgically removed in 2 and spontaneously excreted in the feces.

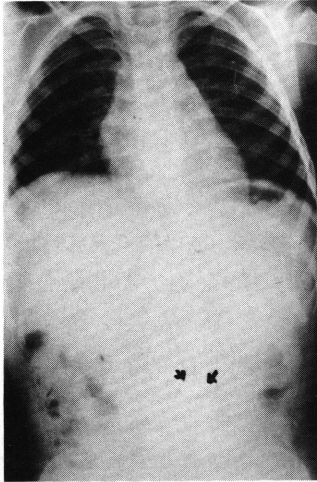
A main reason for surgical intervention was that button batteries in 2 infants were left in the stomach at the time of consultation of our clinic.

In the other case, on admission the foreign body of button battery remained in the small intestine, having already passed through the stomach as shown in Fig. 1. And then, it traveled to the transverse colon at 15 hours after admission as illustrated in Fig. 2 and at 18 hours in help of drugs accelating intestinal peristalsis it was confirmed to have been excreted in the feces.

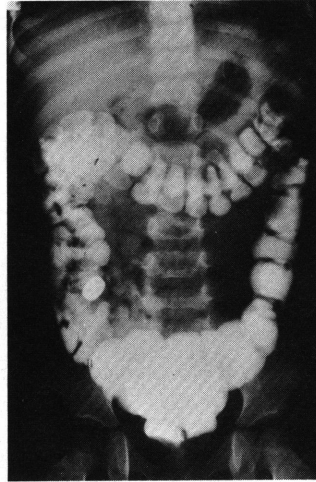
Fig.3 showed the extracted batteries that corrosive alterations were defined on their surfaces. There was no significant difference between the integrity of corrosive changes. A total of the time durations leaving the two batteries in the stomach in two cases were

as long as 8 hours and half, and 4 and half resectively.

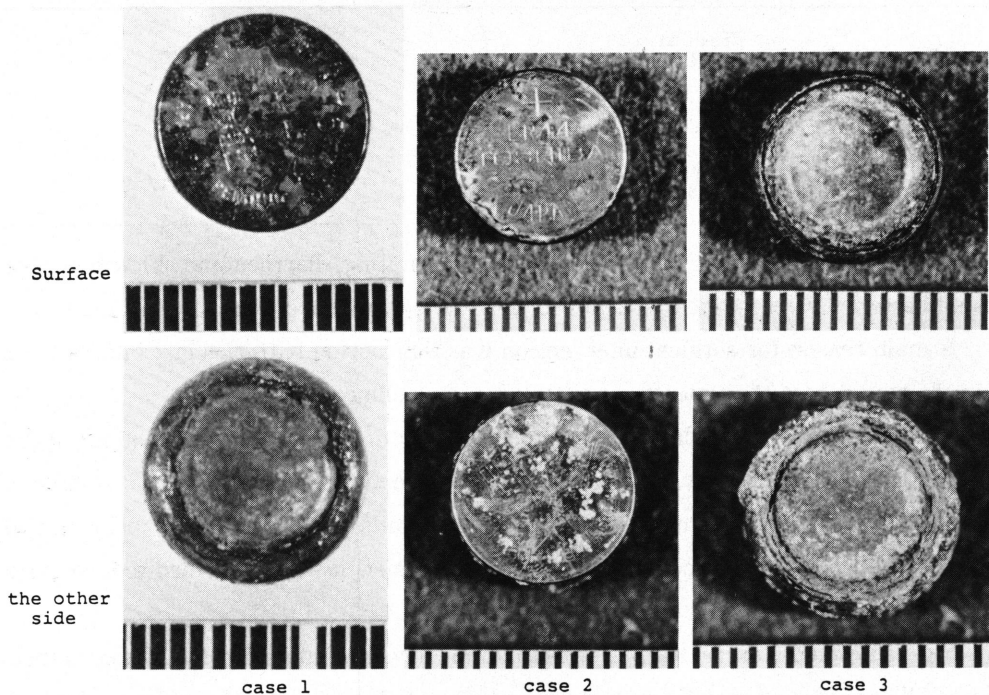
In both, there was no remarkable difference in corrosive changes on gross appearance without any destruction of their capsulae.



**Fig. 1.** Abdominal x-p film, showing a battery in the small intestine (arrow).



**Fig. 2.** Abdominal x-p film revealed that a battery traveled to the descending colon, which was identified by barium enema.



**Fig. 3.** Three batteries were shown on the surface and the other side to identify the integrity of corrosive damage in each case.

## DISCUSSION

It is well known that a large number of foreign body indigestions occur in age 1 to 2 years, followed by age 3 to 5 years. Coin ingestion is main cause of accident of foreign body ingestions.

The usual fortuitous lodgment is the first and third site of physiologic stenosis of the esophagus, pyloric ring, descending portion of the duodenum and cecum. In the 2 cases, the pyloric ring was a barrier to pass through. In the other case, it was spontaneously excreted at 18 hours. In case with esophageal lodgment, attention should be paid to prevent perforation because the esophagus is vulnerable to perforation.<sup>4)</sup> Daily roentgenogram to monitor battery progression was beneficial to manage the patient. It seemed that careful observation at home might be sufficient.

We, however, must be borne in mind that there is the complication regarding a perforated Meckel's diverticulum.<sup>5)</sup> In the two patient who underwent surgical extractions, clinical presumption of alarming alkali poison against gastric mucosa hastened us to remove surgically.

To our knowledge, surgical intervention is necessary for prevention from severe complications if the passage of the battery is not seen within 48 hours.<sup>6)</sup> This consideration is not necessarily appropriate for management of button battery ingestion, assessing accumulated clinical data to date. We should know that there is no correlation between transit time and damage to the battery cells excreted.

Effort must be made to excrete the battery cells from the digestive tract, avoiding surgical intervention as far as possible, for example in help of drugs accelerating intestinal peristalsis. Such is not correct that common consideration to manage battery cell ingestion advocate surgical intervention if the battery does not pass and move in the digestive tract for at least 24 hours. This recommendation is thought of being anecdotal and is not supported as shown by gross appearance of the surfaces of extracted batteries. It is dubious that expeditious removal is recommended in the literature because of destruction of battery cell capsula and corrosive action of chemical agents.

The best way to manage button battery ingestion is to anticipate spontaneous excretion with aid of drugs accelerating intestinal peristalsis without surgically urgent removal.

Great care must be exercised to prevent a complication when much longer lodgment

at the same site occurs.

#### REFERENCES

- 1) Benson CD and Lloyd JR : Foreign bodies in gastrointestinal tract, Pediatric Surgery, Year Book Medical Publishers, p897, 1979.
- 2) Shabino CL : Esophageal perforation secondary to alkaline battery ingestion. JACEP 8 : 360-362,1979.
- 3) Litovitz, TL : Button battery ingestion, a review of 56 cases. JAMA 249 : 2495-2500, 1983.
- 4) Nandi P. Ong. GB : Foreign body in the esophagus : Review of 2394 cases. Br. J. Surg. 65 : 5-9, 1978.
- 5) Willis GA : Perforation of Meckel's diverticulum by an alkaline hearing aid battery. Can. Med. Assoc. J. 126 : 497-498, 1982.
- 6) Easom JM : Risks from swallowing small alkaline batteries. Pediatric Alert 7 : 21-22, 1982.