

Resection of Intrathoracic Esophageal Cancer by Blunt Dissection without Thoracotomy

Yuzo UCHIDA, Kazuhide TOMONARI, Nobuhiko FUJISHIMA,
Tetsuo HADAMA, Okihiko SHIBATA, and Joji SHIRABE

*The Second Department of Surgery,
Oita Medical College, Oita, Japan*

Key words : blunt dissection, esophagus, cancer of the intrathoracic esophagus

Received for publication, June 4, 1986

INTRODUCTION

Resection of the esophagus with dissection of the lymph nodes under thoracotomy and laparotomy are considered as a standard operation for the cancer of the intrathoracic esophagus for reason of its radicality. However, thoracotomy is often avoided in certain cases of the aged patients and of those with cardiac and pulmonary complications, as these may develop complication following surgery. In the past, feeding gastrostomy were performed for such patients.

In our Department, blunt dissection of the esophagus was performed for cancer of the intrathoracic esophagus in four patients, and they have survived for relatively long periods. In this paper, we would like to present clinical and pathological findings of these cases and to discuss the problems of the blunt dissection of the esophagus for cancer of the intrathoracic esophagus.

Table 1. Presentation of the Clinical and Pathological Data in the 4 Patients

Case Age & Sex	(1) 81 , M	(2) 58 , M	(3) 57 ,F	(4) 78 , M
Chief Complaint	dysphagia	dysphagia	sense of stenosis	decrease in body weight
Chest X-ray	emphysema	deviation of the trachea	n.p.	bronchiectasis
E.C.G.	W.N.L.	W.N.L.	flat T-wave	W.N.L.
Respiratory Function	%VC : 98.0 FEV ₁ % : 78.0	%VC : 110.0 FEV ₁ % : 76.0	%VC : 134.0 FEV ₁ % : 77.0	%VC : 121.0 FEV ₁ % : 81.3
Preoperative Diagnosis	Im (5.0cm) superficial, depressed type Biopsy : sq	Iu·Ce(7.0cm) spiral (superficial after radiation), depressed type Biopsy : sq	Im(2.0cm) superficial, elevated type Biopsy : sq	Ei(3.0cm) superficial, elevated type Biopsy : sq
Preoperative Irradiation	-	40 Gy	-	-
Pathology of the Resected Esophagus	ulcerative type 4.5 x 1.5 cm well diff. sq mp,ly _o ,v _o	superficial scar 3.0 x 3.0 cm sq. Ef ₂ R-mp,ly _o ,v _o ,n _o	protruded type 2.5 x 1.3 cm mod. diff. sq sm,ly _o ,v _o	ulcerative type 2.5 x 2.5 cm mod. diff. sq a ₂ ,ly ₁ ,v _o
Postoperative Irradiation, Chemotherapy	-	30 Gy	40 Gy Tegafur	50 Gy
Survival after Surgery	4y. died of recurrence	4y.1month alive	3y.10months alive	1y.2months alive

sq : squamous cell carcinoma
W.N.L. : within normal limit

MATERIALS AND METHODS

Within four years since the opening of the Hospital of Oita Medical College, a total of 70 cases with esophageal cancer were treated in our division, the 2nd Department of Surgery. Resection of the esophagus was performed on 41 cases, and five of them underwent blunt dissection of the esophagus. The locations of tumors in these five cases were as follows; cervical esophagus (Ce): 1, upper intrathoracic esophagus (Iu, Ce): 1, middle intrathoracic esophagus (Im): 2 and lower intrathoracic esophagus (Ei): 1. In this paper, the four cases, in which the tumors located in intrathoracic esophagus (Iu, Im, Ei) were dealt with.

The technique of surgery was as follows; The patients lay supine with the neck extended, and the head turned towards the right. After exploring the abdomen through an upper midline incision, the esophageal hiatus was enlarged anteriorly. The esophagus was dissected by finger inserted through the esophageal hiatus enlarged. The cervical esophagus was approached through an incision along the anterior border of the left sternomastoid muscle and dissected, leaving the intact left recurrent laryngeal nerve attached to the

trachea. The separation was continued downwards by finger to free the upper intrathoracic esophagus, and the lower esophagus in the neck was transected and pulled down towards the abdomen by invaginate technique¹⁾. Esophageal replacement was carried out by a gastric tube which was pulled up through retrosternal or antethoracic route.

Clinical and pathological findings of the esophageal carcinoma were recorded according to the Guidelines for the Clinical and Pathological Studies on Carcinoma of the Esophagus²⁾.

RESULTS

The clinical and pathological findings of these cases, the contents of their treatments and the postoperative course are summarized and shown in Table 1.

The patients, three males and one female, were of the ages, 57, 58, 78 and 81. Three of them complained dysphagia or sense of swallowing abnormality and that of the remaining case was decrease in body weight. Cancer located at the region²⁾ Iu in one case, Im in two and Ei in one. As to the radiological findings, two cases were diagnosed as superficial type, while one as spiral (superficial after radiation) and one as tumorous. Endoscopically, one case was indicated as superficial type, while two as depressed and one as elevated. Furthermore, endoscopic biopsy revealed squamous cell carcinoma in all of the cases. The preoperative examination indicated emphysema in Case 1, flat T-waves in electrocardiogram in Case 3 and bronchiectasis in Case 4, but Case 2 has shown no preoperative complication. While preoperative irradiation was given in Case 2, it was omitted in Case 1 and 4 because of their ages, and in Case 3 whose cancer was of superficial type (Fig. 1). In the initial radiological examination of Case 2, rightward deviation of the trachea was found, indicating a mediastinal tumor. The shadow defect of spiral type 7cm in length (Fig. 2-a) which was seen before irradiation disappeared after 40 Gy of irradiation, and the esophageal wall became smooth without deviation of the trachea in esophagogram (Fig. 2-b). Preoperative chemotherapy was not employed in any case.

On surgery, the intrathoracic esophagus was removed by blunt dissection without formal thoracotomy. In Case 2, the sternum was vertically cut at the level of third intercostal space, and midsternotomy was done at the upper region. Then, dissection of the upper mediastinal lymph nodes and separation of the esophagus were carried out. In all of the cases, the stomach was used for esophageal replacement. The gastric tube was pulled up through antethoracic route in Case 4, and through retrosternal route in other 3 cases.

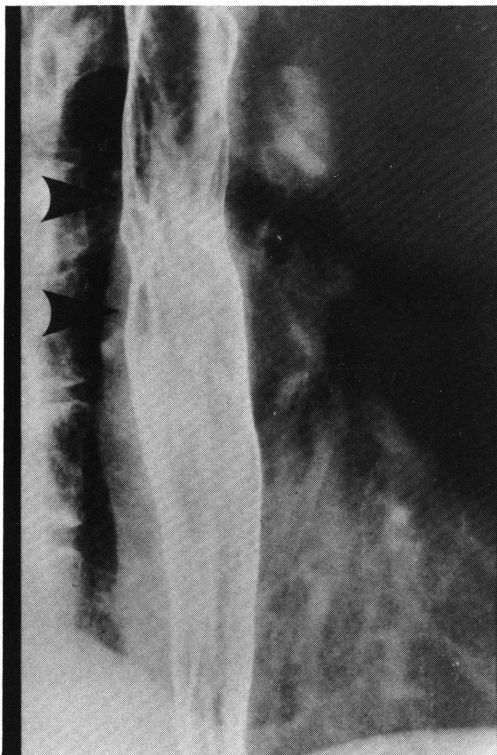

Fig. 1. Esophagogram of Case 3 showing a superficial elevated lesion in the middle intra-thoracic esophagus.

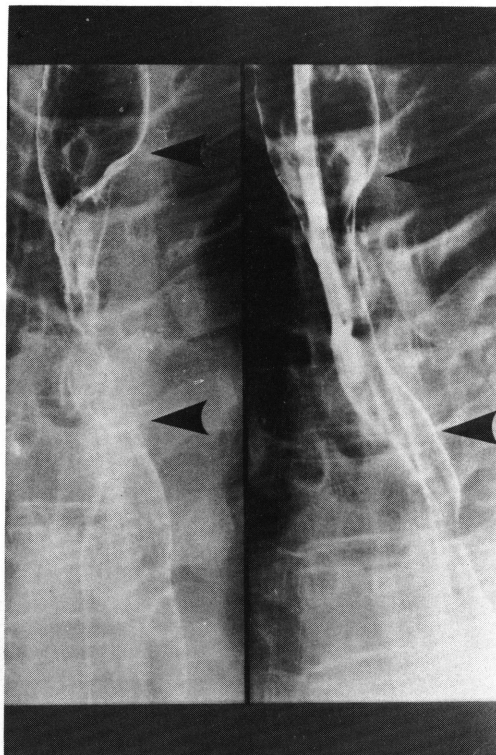


Fig. 2. Esophagogram of Case 2 showing a marked spiral shadow defect before irradiation (Fig. 2-a) and a narrowing with smooth surface after irradiation (Fig. 2-b).

The postoperative course was satisfactory, and none of them showed leakage at the site of anastomosis or any complication of the lung.

In the removed esophagus, carcinoma of ulcerative type was found in Case 1 and 4, a scar-like lesion produced by irradiation in Case 2 and superficial elevation in Case 3 (Figs. 3-6). Histological examination revealed squamous cell carcinoma in all cases. In Case 2, the preoperative irradiation was found to be moderately effective (Ef_2) as cancer cells were seen only in T. muscularis propria, and numerous fibroses were observed at the submucosal and muscular layer. In Case 1, cancer invasion reached T. muscularis propria, in Case 3 T. submucosae and in Case 4 T. adventitia. Mild cancer invasion to the lymph vessels (ly) was observed only in Case 4. Metastasis to lymph nodes dissected was not observed in any case.

After the operation, a total dose of 30 Gy Linac-X-ray was given to the posterior mediastinum in Case 2, 40 Gy in Case 3 and 50 Gy in Case 4, but postoperative irradiation

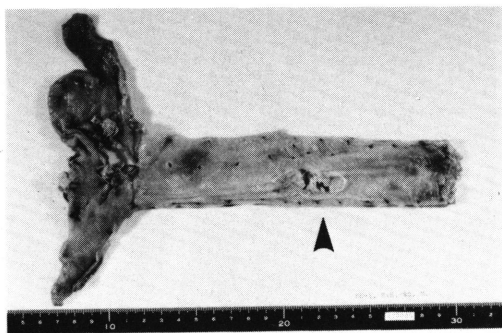


Fig. 3. Case 1. An ulcerative lesion.




Fig. 4. Case 2. A superficial scar.

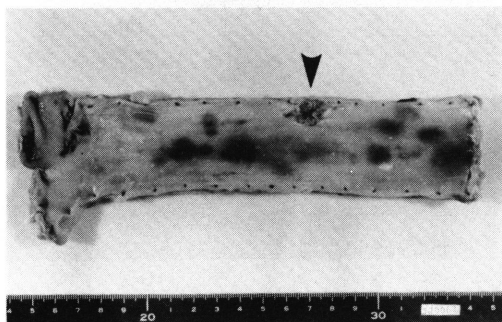


Fig. 5. Case 3. A protruded lesion.

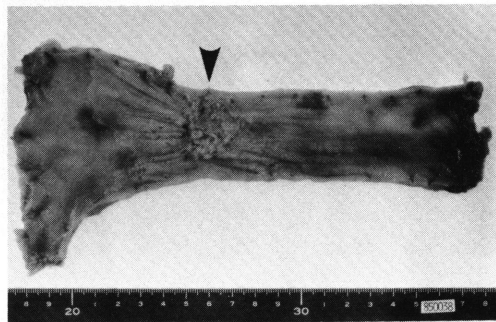


Fig. 6. Case 4. An ulcerative lesion.

was not performed in Case 1 because of the advanced age. As for the postoperative chemotherapy, Tegafur at a dose of 750mg/day was given in Case 3 for one year.

The Case 2, 3 and 4 are alive now with the postoperative periods of 4 years and one month, 3 years and 10 months and one year and 2 months respectively. The Case 1 survived 4 years after surgery and died of recurrence of carcinoma in mediastinal lymph nodes invading to the bronchus, that autopsy revealed.

For one year since 1982, 9 cases with esophageal carcinoma received resection and reconstruction of the esophagus in our division (Table 2). In six of these cases, the intrathoracic esophagus was removed transthoracally, and in 3 cases, blunt dissection was performed. Of six cases with transthoracal esophagectomy, one belonged to "stage 0" (a case with intraepithelial carcinoma without metastasis) and has been alive for 3 years and 8 months after surgery. The other 5 cases belong to stage or and died within one year after

Table 2. Prognosis of 9 Patients Operated in 1982

Survival stage		Number of cases	6M.	1y.	2y.	3y.	4y.
Transthoracic dissection	0	1	→				
	I	0					
	II	0					
	III	1	→				
	IV	4	→	→	→	→	→
Blunt dissection		3	→				
Total		9	5	4	4	4	

→ dead → alive

surgery due to recurrence of carcinoma. The two of the 3 cases with blunt dissection (Case 2 and 3) are alive now, over 3 years after surgery, and another one (Case 1) survived for 4 years.

DISCUSSION

The history of blunt dissection of the esophagus started in 1933 when Turner³⁾ carried out enucleation of the esophagus by finger for a 58-year-old man with esophageal cancer. In 1970, Leonard⁴⁾ published a paper on the method of mobilizing the esophagus by blunt finger dissection which he performed for cancer of the hypopharynx and cervical esophagus. In Japan, Akiyama⁵⁾⁶⁾ performed esophagectomy by blunt dissection for cancer of the hypopharynx and the cardia and reported its usefulness in 1973. Since then, the techniques of the esophagectomy by blunt dissection have been adopted and applied exclusively to cancer of the hypopharynx, of the cervical esophagus and of the cardia. On esophagectomy by blunt dissection for cancer of these regions it is quite significant that the intrathoracic esophagus which may possess multiple lesion can be resected without thoracotomy, and the value of this method has become widely recognized today.

In 1974, on the other hand, Kirk⁷⁾ removed the intrathoracic esophagus by finger dissection through the esophageal hiatus in a patient with esophageal cancer without a hope for radicality. In 1977, Yonezawa et al⁸⁾ reported their experience of the blunt

dissection for cancer of the intrathoracic esophagus and discussed the indication of this method. They also presented the cases without a hope for radicality due to extreme metastasis to the cervical or abdominal lymph nodes as one of the conditions attached to the indication of this method⁹⁾. Roka¹⁰⁾ emphasized that this method should not be employed for the cases with possibility of carrying out radical resection. By blunt dissection, the metastasis to the mediastinal lymph nodes can not be confirmed and any possibility of dissecting it may be avoided in the cases with cancer of the hypopharynx, of the cervical esophagus and of the cardia as well as in the cases with cancer of the intrathoracic esophagus. On the other hand, the greatest difference between the present method for cancer of the hypopharynx, cervical esophagus and cardia and that for cancer of the intrathoracic esophagus is that the main tumor can be removed by sharp dissection under direct observation in the former, while it is removed by blunt dissection under blind conditions in the latter. Thus, in the latter it is possible to leave out a local cancer invasion in the adventitia of the esophagus. In Case 4 of this paper, a postoperative irradiation (50 Gy) was given because of cancer invasion to the adventitia of the esophagus. Therefore, it is advisable to perform this method only for the cases in which cancer invasion is not suspected in the adventitia of the esophagus by preoperative examinations. In the cases with metastasis to the mediastinal lymph nodes and invasion to the adventitia of the esophagus, esophagectomy by blunt dissection for cancer of the intrathoracic esophagus always has possibilities of lacking radicality. At the 39th Congress of Japanese Society for Diseases of the Esophagus in Tokyo (1985), it was reported that many patients who received this method died of recurrence of cancer within 3 years after surgery. However, several researchers⁹⁾¹¹⁾ reported that esophagectomy without thoracotomy by blunt dissection showed the low rate of postoperative mortality due to pulmonary complications.

In our Department, while many patients having received esophagectomy under thoracotomy died within 2 years after surgery, two of 3 cases which received esophagectomy by blunt dissection have been alive more than 3 years, and another one, in spite of his old age of 81 at the time of operation, survived for 4 years after surgery.

From these results, it may be concluded that we can expect a relatively long survival after surgery, when the present method is performed for the cases with cancer of the intrathoracic esophagus diagnosed endoscopically as superficial, in which thoracotomy is dangerous due to old age or pulmonary disease.

SUMMARY

Esophagectomy by blunt dissection was performed in 4 cases with cancer of the intrathoracic esophagus, and these cases have shown satisfactory postoperative course.

To the cases with cancer of intrathoracic esophagus, in which thoracotomy is regarded as dangerous due to old age or to pulmonary complications, positive employment of the esophagectomy by blunt dissection is quite effective provided that the cases show findings of superficial carcinoma of the esophagus.

REFERENCES

- 1) INOGUCHI, T., TAKEUCHI, K., TAKEDA, H. and SASATOMI, K.: Blunt dissection of the esophagus by invaginate technic for upper gastric cancer with carcinomatous proximal infiltration to the esophagus. *Surgical Therapy*, 36: 509-511, 1977. (in Japanese)
- 2) JAPANESE SOCIETY FOR ESOPHAGEAL DISEASES: Guide lines for the clinical and pathological studies on carcinoma of the Esophagus (6th Edition). Kanehara, Tokyo, 1984.
- 3) TURNER, G. G.: Excision of the thoracic oesophagus for carcinoma with construction of an extra thoracic gullet. *Lancet*, 2: 1315-1316, 1933.
- 4) LEONARD, J. R. and MARAN, A. G. D.: Reconstruction of the cervical esophagus via gastric anastomosis. *Laryngoscopy*, 80: 849-862, 1970.
- 5) AKIYAMA, H., SATO, Y., TAKAHASHI, F., KOGURE, T. and ITAI, Y.: Pharyngogastrostomy by blunt dissection of the esophagus. *Operation*, 27: 1-5, 1973. (in Japanese)
- 6) AKIYAMA, H.: Blunt dissection of the esophagus for cancer of the cardia. *Surgical Therapy*, 29: 458-460, 1973. (in Japanese)
- 7) KIRK, R. M.: Palliative resection of oesophageal carcinoma without formal thoracotomy. *Br. J. Surg.*, 61: 689-690, 1974.
- 8) YONEZAWA, T., YONEMOTO, T., IKEDA, N. and TSUCHIYA, S.: Blunt dissection of the esophagus for cancer of the thoracic esophagus. *Operation*, 31: 107-113, 1977. (in Japanese)
- 9) YONEZAWA, T., TSUCHIYA, S., HOSOI, H., IKEDA, Y. and SUZUKI, K.: Blunt dissection of the esophagus for carcinoma of the thoracic esophagus. *Operation*, 33: 1027-1033, 1979. (in Japanese)
- 10) ROKA, R., FUNOVICS, J., NIEDERLE, B. and FRITSCH, A.: Resection of intrathoracic oesophageal cancer by blunt dissection without thoracotomy. *Wiener Klinische Wochenschrift*, 94 (2): 57-63, 1982.
- 11) TOMITA, M., HONDA, S., KUBOTA, F., SETOGUCHI, M., UCHIDA, Y., TSUJI, Y. and SHIRABE, J.: Resection of the esophagus without thoracotomy. *GEKA*, 36: 1139-1142, 1974. (in Japanese)