

Malignant Lymphoma of the Brain Associated with Multiple Sclerosis-Like Manifestations

Masao KISHIKAWA, Yoshihide TAKAKI, Minoru HONDA, Masachika ISEKI,
Issei NISHIMORI, Hideharu FUJII*, Hideo NAMIKI**,
Noritoshi SHIBUYA***, and Naoko KINOSHITA***

*Department of Pathology, Scientific Data Center of Atomic Bomb
Disaster, Nagasaki University School of Medicine, Nagasaki*

** Department of Pathology, Nagasaki-chuo National Hospital, Nagasaki*

*** Department of Pathology, The Queen's Medical Center,
Honolulu, Hawaii, U. S. A.*

**** Division of Neurology, National Kawatana Hospital, Nagasaki*

Received for publication, November 1, 1985

A 55-year-old female who had been treated for multiple sclerosis, died of respiratory failure. The brain was externally atrophic (1020gm). Serial coronal sections of the cerebral hemispheres showed multiple soft, friable lesions without distinct demarcation, distributed predominantly in the white matter of the corpus callosum, subcortical regions, periventricular areas, and semioval centers. Microscopically, the lesions were composed of confluent foci of rarefaction without distinct borders. The rarefied foci demonstrated not only demyelination, but also destruction of the axons associated with the presence of innumerable foamy histiocytes, lymphocytes, and a number of hypertrophic astrocytes. Another outstanding finding was the presence of perivascular infiltrates, that is, pleomorphic atypical lymphocytes, at the margin of and adjacent to the rarefied white matter lesions, and also in the grey matter. These perivascular, atypical lymphocytic infiltrates were interpreted as those of malignant lymphoma. It was impossible to determine whether the lymphomatous changes were those of primary brain lymphoma or brain involvement by systemic lymphoma. Perivascular concentration of lymphoma cells with possible alteration of the blood-brain barrier may have led to marked cerebral edema and subsequent rarefaction in the cerebral white matter, which in turn may have led to the manifestation mimicking multiple sclerosis.

岸川 正大, 高木 芳秀, 本田 実, 井関 充及, 西森 一正, 藤井 秀治, 並木 秀男,
渋谷 統寿, 木下 直子

Mailing address: Masao KISHIKAWA, M.D., Department of Pathology, Scientific Data
Center of Atomic Bomb Disaster, Nagasaki University School of Medicine,
12-4 Sakamoto-machi, Nagasaki 852, JAPAN

INTRODUCTION

Multiple sclerosis (MS) displays characteristic clinical manifestations and pathological findings, and so typical cases of the disease are easily diagnosed. Most cases show variable neurological symptoms and signs, and a tendency toward remission and exacerbation and a pathological picture characterized by well-demarcated and segmental demyelination, particularly in the periventricular regions and in the white matter. Recently, however, there have been reports of cases that followed a clinical course similar to that of MS during the course of malignant lymphoma (ML) of the brain^{4,5}. The clinical course of case which we experienced and report here was extremely similar to MS, and autopsy revealed the presence of malignant lymphoma and multiple rarefaction.

CASE REPORT

A 55-year-old woman visited a certain national hospital in December 1981 complaining of weight loss (8kg/ 7 months), but a detailed physical examination revealed no particular disorder. When the weight loss continued (15kg/ year) and the patient returned for examination on February 4, 1982, a duodenal ulcer was detected and she was admitted to the hospital. While receiving conservative treatment, masked depression and slight fever continued, but the patient was discharged after 2 weeks in accordance with her wishes. On May 30 of the same year, nausea and vomiting appeared, and a speech disturbance was noticed. A CT scan of the head conducted on June 7 revealed an abnormal shadow in the right putamen and right internal capsule (Fig. 1), and the patient was readmitted to the hospital. At the time of admission consciousness was clear, but left hemiparesis, left hemihypesthesia, and Babinski's reflex were observed. There was no evidence of neck stiffness or abnormality in the ocular fundui. On June 17, the left hemiparesis disappeared, although a slight hypesthesia of the left lower extremity remained, and the upper extremities and face returned to normal. On July 7, left hemiparesis reappeared, the level of consciousness deteriorated slightly, and an onset of palsy of the 7th cranial nerve, left hemihypesthesia (including the face), and exaggerated deep reflex were noticed. There was no mental disturbance, and orientation was good. On July 30, urinary incontinence appeared. On August 6, conjugate deviation to the left was noticed along with the

appearance of rigidity in the left upper extremity. On August 10, the administration of decadron was started in 18mg doses, reduced gradually from 16 to 8mg and then stopped. As a result, the level of consciousness improved and the left hemiparesis almost disappeared. On August 23, the patient suffered from perforation of the duodenal ulcer and received an emergency abdominal operation. At the time of operation no mass lesion was noticed in the abdominal cavity. Postoperatively, the patient's course was stable and her consciousness was clear, but on October 6 she fell into a stuporous to somnolent state with the appearance of left hemiparesis (left lower extremity > left upper extremity), rigidity of the right side, and palsy of the 7th cranial nerve.

Subsequently, the level of consciousness gradually deteriorated and decerebrated rigidity appeared, and so the administration of 10mg doses of decadron was resumed. On December 8, the patient was transferred to the *Division of Neurology at National Kawatana Hospital*. Findings at the time of admission included decerebrated rigidity, akinetic

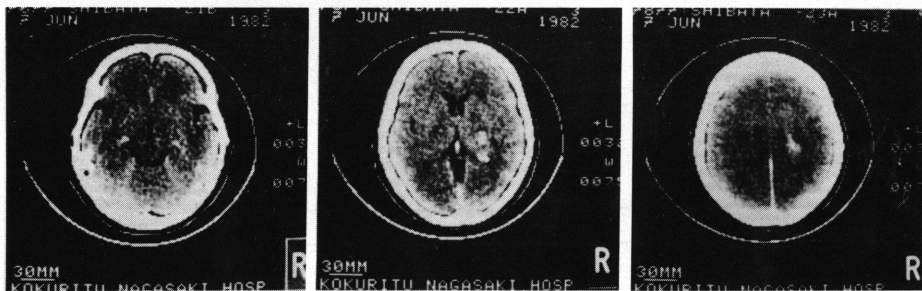


Fig. 1. CT scan (July 7, 1982) showing abnormal densities in the right putamen and right internal capsule.

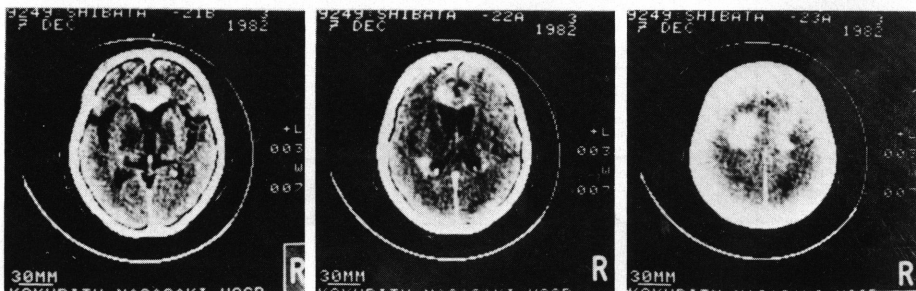


Fig. 2. CT scan (December 7, 1982) showing a high density area in the corpus callosum.

mutism, mydriasis, and the absence of corneal reflex. Deep reflex had advanced in the lower extremities but was absent in the upper extremities. Babinski's reflex was positive on the right side. CT scan revealed a lesion with marked enhancement in the corpus callosum (Fig. 2). The patient's illness was diagnosed as MS, and plasma exchange (PE) was carried out 2 liters at a time, at a rate of 2 times per week. After the 3rd PE the pupils returned to their normal size, and light reflex and corneal reflex reappeared. PE was carried out a total of 16 times, but the consciousness deterioration and decerebrate rigidity did not improve. On March 23, 1983, urinary volume diminished, symptoms of bronchopneumonia and pulmonary edema appeared, and the patient died the following day on March 24, 1983.

In the latter stages of the illness there was a rise in alkaline-phosphatase and LDH, but otherwise no irregularities were noticed during the entire course of the patient's disease (Fig. 3, Table 1). Immunologically, IgG was normal, and there was no evidence of oligoclonal IgG band. The C_{1q} binding was very high level ($48 \mu\text{gAHGEq/ml}$; normally less than $3.0 \mu\text{gAHGEq/ml}$), while RA and Coomb's test proved negative (Table 2).

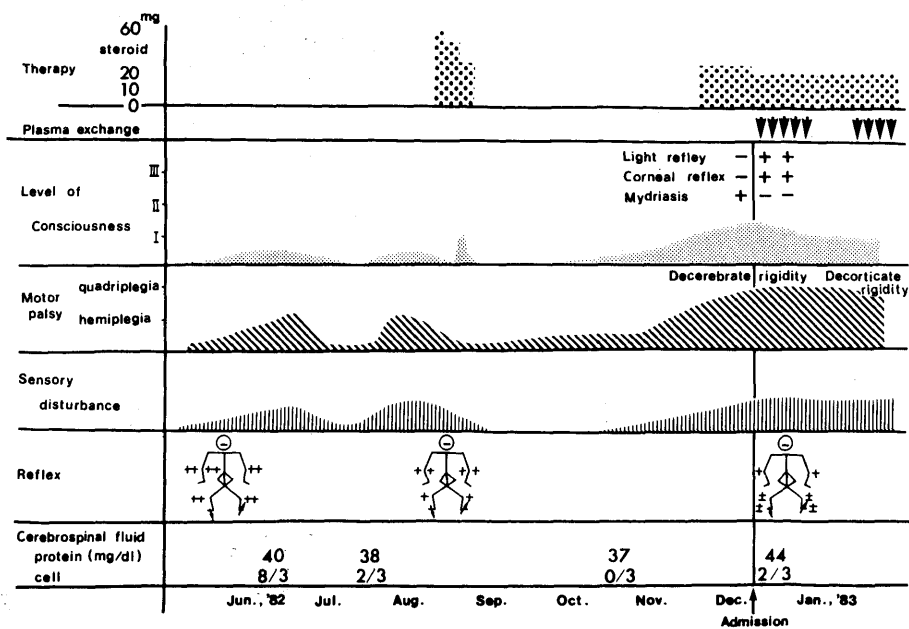


Fig. 3. Clinical findings and treatment.

Table 1. Laboratory Data (1)

<u>Labo. Data</u>	Jun., '82	Mar., '83
GOT(10-28)	14	24
GPT(3-26)	12	58
Al-Pase(3-11)	6	24
LDH(93-190)	115	809
<u>Blood Data</u>	Jun., '82	Mar., '83
RBC	450	365
WBC	6700	6400
Stab.	6	17
Seg.	53	45
Lymph.	31	36
Mono.	10	2
Eryth. Blast		5

Table 2. Laboratory Data (2)

<u>Immunological Study</u>	Jun., '82			
IgG 1210 mg/dl	C ₃	116	mg/dl	
IgA 496 mg/dl	C ₄	58	mg/dl	
IgM 220 mg/dl	CH ₅₀	20	u/ml	
IgE 60 u/ml	I.C.(C _{1q} binding)	48	µgAHGEq/ml	
<u>Liquor</u>	Jun.	Jul.	Oct.	Dec., '82
Protein(mg/dl)	40	38	37	44
Sugar(mg/dl)	63	77	64	89
Cell	8/3	2/3	0/3	2/3
Cl(mEq/l)	116	125	119	
M.B.P.	2.8 ng/ml(Jul.), IgG 6.14 mg/dl(Dec.),			
Oligoclonal band:	negative(Dec.)			

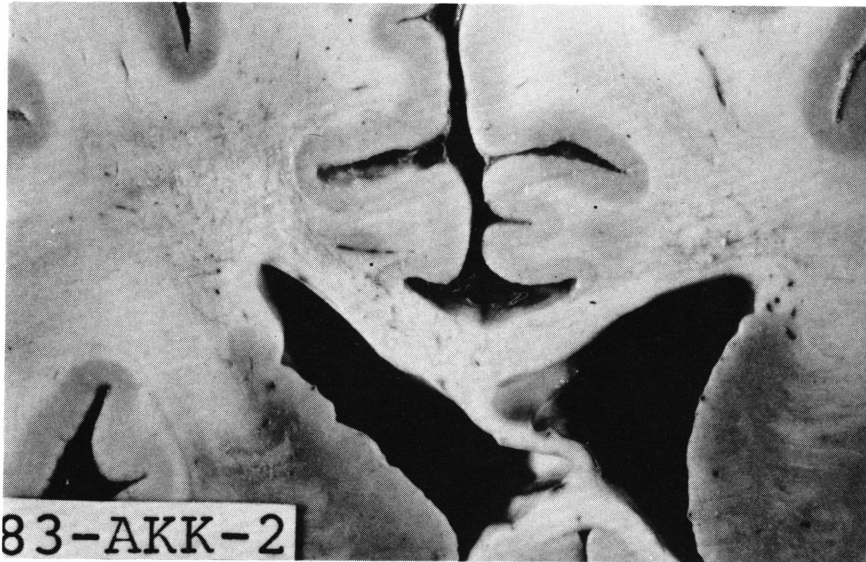


Fig. 4a

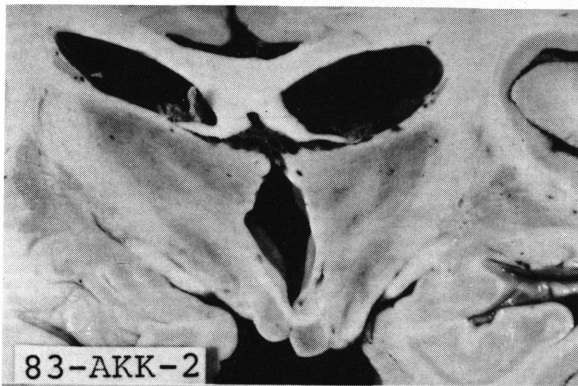


Fig. 4b

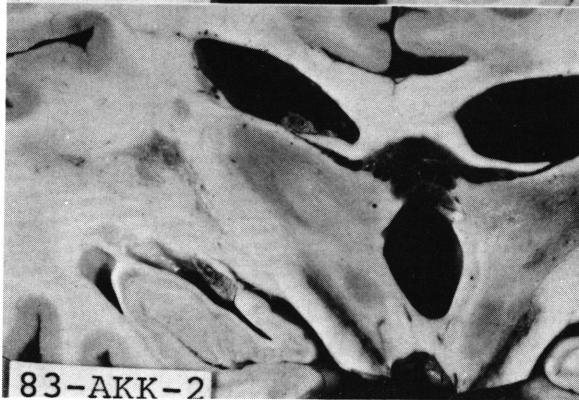

Fig. 4c

Fig. 4. Gross pathologic lesions of the brain. a) Poorly demarcated rarefied lesions in both semioval centers and corpus callosum, dilatation of the lateral ventricles, and uneven ependymal surface of the left caudate nucleus. b) & c) Atrophy of the thalami and moderate dilatation of the third ventricle.

AUTOPSY FINDINGS

An autopsy was performed 3.5 hours postmortem, but permission was received only for brain necropsy. The rest of the body was examined superficially and no swelling of the lymph nodes or lesions of the skin were noticed. Height was 148cm and nutrition was poor. The weight of the total brain was 1020gm and showed marked atrophy, while the combined weight of the cerebellum, pons, and medulla oblongata was 155gm. The right and left hemispheres were roughly symmetrical. There was evidence of localized mild swelling in the leptomeninges. The sulci, on the whole, were rather deep, and atrophy was observed in the basal portion of the cerebrum in particular. Multiple and varied rarefaction was evident in the coronal section, especially the frontal portion of the genu corporis callosi, the centrum semiovale, the nucleus lentiformis, and the thalamus, and it was scattered in both the right and left hemispheres. The caudate nucleus and the thalamus were atrophied, while the lateral ventricle and the 3rd ventricle were dilated (Fig. 4a-4c). The pyramidal tract of the midbrain, pons, and medulla oblongata was pale and atrophied. There was no macroscopic change observed in the mammillary body, substantia nigra, or in the cerebellum.

HISTOPATHOLOGICAL FINDINGS

Demyelination and rarefaction, and marked disappearance of the myelin were evident in the macroscopically softened areas, and their border with the unaffected areas was generally obscure (Fig. 5a). Even in areas where the border was somewhat distinct, the axons as well as the myelin had disappeared, and numerous foamy cells were present. Numerous foamy cells, and the infiltration of atypical mononuclear cells, were also noticed in the areas with obscure borders, and the axons were preserved in some areas (Fig. 5, inset). In the old lesions, severe gliosis and the infiltration of mononuclear cells were observed, and the gliosis was characterized by the marked proliferation of hypertrophic astrocytes. Among these there was a sparse scattering of ALZHEIMER type I-like astrocytes with bizarre nuclei. This rarefaction and/or rarefaction necrosis was widely present in the cerebral white matter, although absent in the cortex and cerebellum. Wallerian degeneration identical to that of the pyramidal tract was observed in the

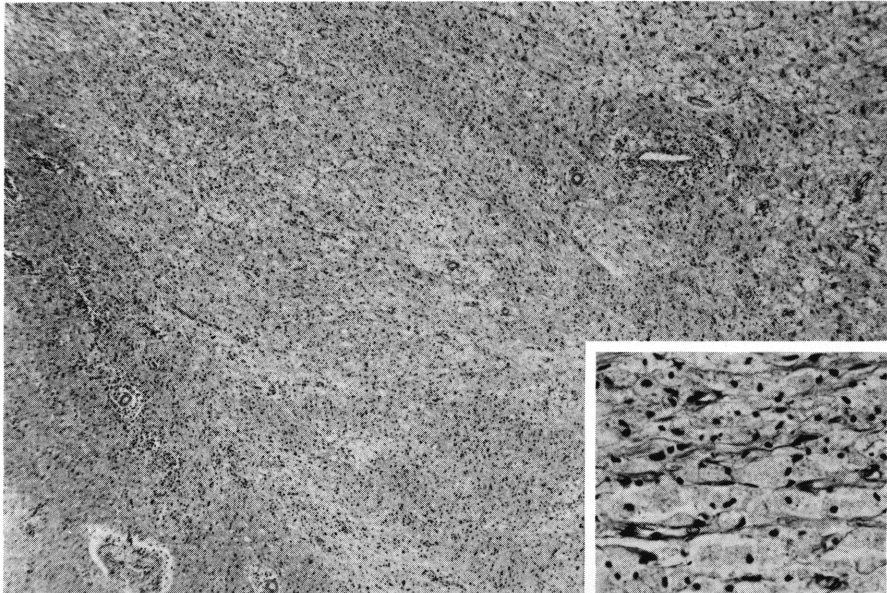


Fig. 5a

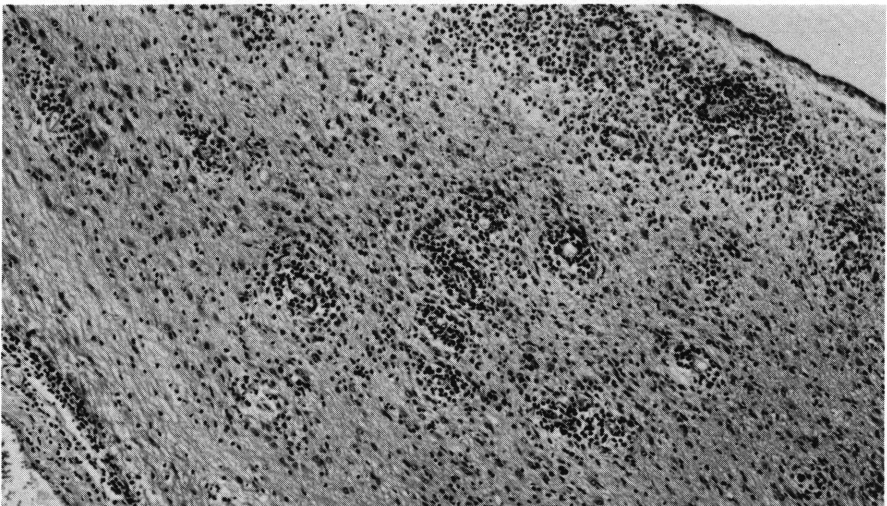


Fig. 5b

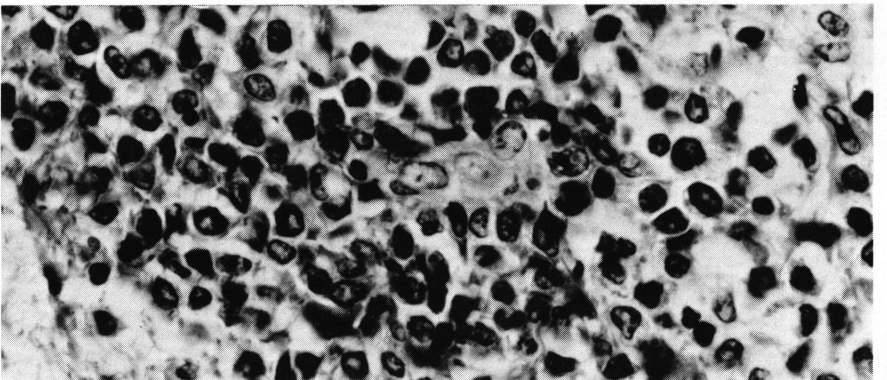


Fig. 5c

midbrain, pons, medulla oblongata, and the uppermost portion of the spinal cord (C₁₋₂). There was no apparent difference between the right and left hemispheres. Immunohistopathological examination of the rarefied lesions revealed that there was no direct correlation between the IgG (PAP method, DAKO Corp.) and the affected myelin sheath, although moderately positive findings were obtained for hypertrophic astrocytes. Numerous epon blocks of the rarefied foci were prepared from the post-formalin fixed materials and observed by electron microscopy. Hypertrophic astrocytes with numerous glial fibrils, microglia phagocytizing the destroyed myelin, and swollen degenerated neuropiles were detected, but no virus particles were observed.

Another characteristic finding was the marked and widespread proliferation of atypical mononuclear cells. Multiple representative sections from the cerebral hemispheres, diencephalon, brain stem and cerebellum demonstrated massive minute mononuclear cell infiltration around small vessels in the cerebral and cerebellar parenchyma. The individual cells were medium-sized and almost isomorphic, and their cytoplasm was scanty. The hyperchromatic nuclei showing frequent atypism and mitosis did not appear to be cleaved but rather to be convoluted. Immunohistopathologically, these cells were completely negative for immunoglobulins (IgG, IgA, IgM, kappa chain). These tumor cells displayed conspicuous proliferation mainly around the blood vessels (Fig. 5b), and moreover, there was a high degree of infiltration into the vessel walls. Stenosis or obstruction of the vascular cavity was also observed (Fig. 5c). Along with the infiltration of cells, the proliferation of reticulin fiber around the vessels was evident, and swelling of the endothelial cells was also noticed. It was particularly evident in the caudate nucleus, centrum semiovale, and thalamus. It did not appear in the cerebral parenchyma as a mass lesion, but rather as a scattering of small foci. The atypical cells showed widespread infiltration, although in varying degrees. A mild infiltration of cells around the blood vessels in the cerebellum was noticed occasionally. Focal lymphomatous infiltration was also observed in the leptomeninx and pachymeninx.

Fig. 5. Major histopathologic findings. a) Demyelination associated with anisomorphic astrogliosis and proliferation of foamy histiocytes in the semioval center. LFB, $\times 40$. Inset: Numerous foamy histiocytes and hypertrophic astrocytes. H. E., $\times 200$. b) Perivascular infiltration with atypical lymphocytes, drop-out of neurons, rarefaction of neuropil and proliferation of hypertrophic astrocytes in the caudate nucleus. H. E., $\times 95$. c) Dense perivascular infiltration with large, moderately pleomorphic, atypical lymphocytes. H. E., $\times 600$.

DISCUSSION

Pathological Diagnosis :

CT scans of the head revealed multiple lesions with marked enhancement, but not all of their local symptoms could be grasped clinically. The lesions detected by CT scan showed a correlation with the aggravation and remission of symptoms during the illness. So, in view of the clinical course, MS was the most compatible diagnosis.

Macroscopically, the fact that the lesion was also present in the periventricular regions seemed to support the diagnosis of MS. However, the border of the lesion in the centrum semiovale was obscure, and the border between the lesion and the surrounding tissues in the corpus callosum was also unclear.

Histopathologically, the obscurity of the borders became even more evident. Also, there was widespread disappearance of both the myelin and the axons, and Wallerian degeneration was observed as a secondary change in the depended tracts. These findings are not in keeping with MS, and point rather to circulatory disturbance or another form of degeneration, or to the direct destruction of brain tissue. The characteristic histopathological finding was the marked proliferation and infiltration of atypical cells. These atypical cells displayed mild polymorphism along with nuclear convolution, but the nuclei did not appear cleaved. Cells showing mitotic figures were also observed frequently, and on the basis of their reaction to the immunoglobulin stain (PAP method), malignant lymphoma (ML), especially T-cell lymphoma, seemed the most likely diagnosis. The high level of immune complex (C_{1q} binding) was compatible to malignant lymphoma.

Unfortunately, it is unknown whether or not there were lesions in organs other than the brain because only brain necropsy was performed. At the time of the abdominal operation 7 months prior to death, there was no swelling of the superficial or intra-abdominal lymph nodes, and routine blood tests revealed no abnormalities. In only one instance 3 weeks before death, the appearance of a very small amount of erythroblasts was detected in peripheral blood examination and so a bone marrow study was performed. But no unusual findings could be detected. At the time of autopsy, the superficial lymph nodes were not palpable. Usually, cases of primary cerebral ML are presented with mass lesions, and even when this is eradicated by steroid hormone therapy, scar-like lesions remain in most cases. In the present case, diffuse infiltration of mononuclear cells, and perivascular infiltration and invasion into the vascular walls, were predominant, and there

was a marked and widespread proliferation of astrocytes. These findings indicate the possibility of an invasion of systemic lymphoma into the brain. However, infiltration of ML cells, although noticed to a very small extent in the dura, was absent in the pituitary gland and its periphery, and there were no findings to suggest that lesions were more severe in the basal portion of the cerebrum than in other areas. It is impossible to conclude whether the present case is primary ML or the invasion of systematic ML into the brain.

Generally speaking, primary ML of the brain is thought to be B-cell, but one of the authors of the present paper experienced two cases of primary cerebral ML that could be clearly identified as T-cell by immunohistochemical survey of surface markers (Namiki, unpublished). This immunohistochemical survey of surface markers of lymphoma cells was not carried out in the present case, but light microscopic findings revealing complete negativity for IgG, IgA, IgM and kappa chain indicated the possibility of T-cell. However, an immunohistochemical study using surface markers was not carried out, and so a definitive diagnosis is impossible.

Pathogenesis of rarefaction :

Another very interesting fact here is that, along with the extreme similarity between the clinical picture in the present case and that of MS, pathologically a widespread rarefaction of the white matter was present. The tumor cells showed diffuse, although mild, infiltration into the brain, and locally they proliferated in some areas in the form of small nodules. Also, the massive infiltration of the cells into the vessel walls points to the role they played in the stenosis and obstruction of the vascular cavities. On the basis of the above findings, it seems likely that what was thought to be MS was actually a circulatory disturbance due to a direct destruction or invasion of the blood vessel walls caused by ML. However, even though similar perivascular infiltration and stenosis of the small blood vessels (especially venules) are evident in almost all cases of brain lymphoma, it is a very significant fact that there have been virtually no reports of the widespread rarefaction we experienced in the present case. There was almost no marked ischemic change in the region of the cortex that had lymphomatous involvement accompanied by stenosis. Therefore, it is incorrect to say that the rarefaction in the present case was infarction due to stenosis or obstruction of the blood vessels.

Side effects produced by treatment for ML such as methotrexate leukoencephalopathy² are known, but the authors have been unable to find a reported case like our own in which rarefaction or softening occurred without the use of anticarcinogenic agents.

Progressive multifocal leukoencephalopathy (PML) is known to bring about wide-

hormone or those in which immunotolerance is low. In the present case there was no evidence viral infection such as inclusion bodies in the rarefied foci or their peripheral areas, and although numerous epon blocks were prepared and examined by electron microscopy the findings remained negative. PRICE *et al.*³ reported a case of "burnt-out" PML in which intranuclear inclusion bodies, and JC virus antibody were detected by initial biopsy, but could not be detected at an autopsy carried out 16 months later. In that respect, the possibility of PML could not be completely overlooked in our case. However, severe lesions were evident in the cingulate gyri, as well as in the thalamus and caudate nucleus, and the axons had almost completely disappeared from the affected portion of the white matter, remaining only in certain regions. These findings are contradictory to usual PML, and so the authors assumed that PML could be denied in this case. On the other hand, the microscopic findings from the regions showing rarefaction were very similar to lesions due to chronic edema, to the cerebral lesion of Behcet's disease, and to the lesion in the white matter during radionecrosis. In other words, the most compatible etiology concerning the rarefaction observed in the present case is chronic edema caused by a continual advanced state of vascular permeability due to perivascular and/or vascular wall infiltration of lymphoma cells. Another possibility is that the lymphoma cells produced antimyelin IgG, which in turn brought about rarefaction, but investigation by the PAP method indicated that there was no direct relationship with the disintegration of myelin.

Multiple sclerosis and Malignant lymphoma :

It is a well-known fact that remission and exacerbation occurs during the course of MS. Recently, cases of ML in which the clinical course is extremely similar to MS have been reported by WILLIAMS *et al.*⁵ and RUFF *et al.*⁶ The CT scan of both cases reported by WILLIAMS *et al.* showed enhancements very similar to the present case, and in their first case, they described the perivascular proliferation and infiltration into the cerebral parenchyma of ML cells. In the case reported by RUFF *et al.*, aggravation and remission of nystagmus and loss of muscular coordination were observed during the first 3 years. No abnormality was detected by CT scan, and the patient received steroid hormone therapy for MS. After 4 years, CT scan revealed a tumor-like enhancement, and cytological examination of the cerebrospinal fluid led to the diagnosis of ML. This serves as a warning about the possibility of misdiagnosis of early-stage ML as MS. In the reports of WILLIAMS *et al.* and RUFF *et al.*, there was no description of rarefied white matter lesions in the brain at autopsy. In the CT scan carried out in our case, the lesion appeared as a low-density area. In fact, mass effect was absent and enhancement was obtained only after the administration of contrast medium, and so, in that respect as well, MS seemed the

most compatible diagnosis.

The fact that this case displayed during its course a clinical picture strongly indicative of MS is very unusual, and it is considered worthy of announcement in terms of the ongoing compilation of cases in this field of study.

ACKNOWLEDGEMENT

The authors express their gratitude to Doctor Kazuo Nagashima, Department of Pathology, Faculty of Medicine, Tokyo University, for his invaluable suggestions and comments in the diagnosis of this case. The authors are grateful to Miss Fujiko Tanaka for typing the manuscript. An outline of this report was presented at the 25th Annual Meeting of the Japanese Society of Neuropathology (Tokyo, 1984). Also, it was reported as MS at the 81st Kyushu District Meeting of the Japanese Society of Neurology, which was held prior to the death of the patient. (Clin. Neurol. 23 : 545-546, 1983)

REFERENCES

- 1) LINDENBERG, R., HAYMAKER, W. : Progressive multifocal leucoencephalopathy. *In* HAYMAKER, W. and ADAMS, R. D. (Editors): Histology and Histopathology of the Nervous System, Vol. 1, pp.1215-1219. Charles C Thomas Publisher, Illinois, 1982.
- 2) PORTLOCK, C. S. : Lymphomatous involvement of the central nervous system. *In* WHITEHOUSE, J. N. A. and KAY, H. E. M. (Editors): CNS Complications of Malignant Disease, pp.113-120. The Macmillan Press, London and Basingstoke, 1979.
- 3) PRICE, R. W., NIELSEN, S., HORTEN, B., RUBINO, M., PADGETT, B., WALKER, D., : Progressive multifocal leucoencephalopathy: A burnt-out case. *Ann. Neurol.* 13 :485-490, 1983.
- 4) RUFF, R. L., PETITO, C. K., RAWLINSON, D. G. : Primary cerebral lymphoma mimicking multiple sclerosis. *Arch. Neurol.* 36 : 598-599, 1979.
- 5) WILLIAMS, R. S., CROWELL, R. M., FISHER, C. M., DAVIS, K., LAVYNE, M. H., ROPPER, A. H., BREMER, A. M. : Clinical and radiologic remission in reticulum cell sarcoma of the brain. *Arch. Neurol.* 36 : 206-210, 1979.