

Intraoperative Heparin Injection Reduced D-dimer and TAT Levels after Total Hip Arthroplasty

Masato TOMITA,¹ and Satoru MOTOKAWA²

¹Department of Orthopedic Surgery, Nagasaki University Graduate School of Biomedical Science, Nagasaki, Japan

²Department of Orthopedic Surgery, National Nagasaki Medical Center, Omura, Japan

【Background】 Recently, the incidences of pulmonary embolism (PE) and/or deep vein thrombosis (DVT) after orthopedic operation increased in Japan. However the effective prevention methods have not been established yet. To make the effective prevention of PE and/or DVT after total hip arthroplasty (THA), we investigated the time-dependent changes of serum thrombin-antithrombin III complex (TAT) and D-dimer levels after THA.

【Subjects & Methods】 We measured changes of serum TAT, and D-dimer levels (before, on day 1, day 5, week 2 and week 4 after operation). Twenty-six women (mean age 64.5 years old), who had undergone THA for osteoarthritis of the hip joint were enrolled and divided into two groups at random. One group had been intravenously injected with 1,000 units of heparin during THA (IH Group, 14 patients), and the other group had not been injected (NH Group, 12 patients).

【Results】 No patients showed clinical PE and/or, DVT. The levels of TAT and D-dimer in IH group significantly reduced compared with these in NH group on the fifth and first postoperative day, respectively ($p < 0.05$). There were no severe complications clinically.

【Conclusion】 Our data suggests that intravenous heparin injection during THA might be a potentially effective and safe strategy for prophylaxis of PE after THA.

ACTA MEDICA NAGASAKIENSIA 53: 9 - 13, 2008

Keywords: Total hip arthroplasty; Pulmonary embolism; Heparin, thrombin-antithrombin III complex (TAT); D-dimer

Introduction

Deep vein thrombosis (DVT) and pulmonary embolism (PE) have been reported as complications after total hip arthroplasty (THA) and total knee arthroplasty (TKA). However, an effective strategy for the prevention of such complications has not been established yet. Because we have experienced a PE case that developed immediately after THA and there is abundant evidence that many of thrombi occur intraoperatively (6), we concluded that effective intraoperative control is necessary to prevent PE immediately after operation. Although Japanese Guideline for Prevention of Venous Thromboembolism was published in 2004, it did not show the effective prophylaxis against PE and/or DVT immediately after THA as our previous case.

To establish an effective prophylaxis against PE and/or DVT immediately after THA, we examined the effects of intraoperative injection of sodium heparinate and investigated its usefulness and safety.

In the present study, we investigated serial changes in serum thrombin-antithrombin III complex (TAT) and D-dimer levels as markers of PE and/or DVT in patients undergoing preventive antiplatelet and anticoagulant therapies after THA for osteoarthritis (OA).

Subjects and Methods

Twenty-six women, (mean age, 64.5 years old) who underwent THA for osteoarthritis (OA) were included in the present study. Patients with THA were divided into two groups at random; one group that had un-fractionated heparin injected during the operation (1,000 units of sodium heparinate intravenously injected after femoral reaming) (IH Group, 14 patients) and the other group of non-injection of heparin (NH Group, 12 patients). On the first day after operation, a total of 5,000 units of un-fractionated sodium heparinate

Address correspondence: Masato Tomita, M.D., Department of Orthopedic Surgery, Nagasaki University Graduate School of Biomedical Science, 1-7-1 Sakamoto, Nagasaki, 852-8501 JAPAN

TEL: +81-(0)95-819-7321, FAX: +81-(0)95-819-7325, E-mail: mtomita@nagasaki-u.ac.jp

Received February 12, 2008; Accepted April 2, 2008

was continuously injected over 24 hours to the all above-mentioned patients; furthermore, from the second day, one tablet of aspirin (81 mg, Bafferin®) per day for a week and one tablet of ticlopidine hydrochloride (100 mg, Panaldine®) per day for three weeks were administered. Levels in TAT and D-dimer in sera were measured before, day 1, day 5, week 2 and week 4 after operation. All participants in this study provided informed consent, previously.

Enzyme immunoassay was used to determine TAT, and latex near-infrared immunoturbidimetric method was used for D-dimer.

Variations in the presence or absence of bone cement, autologous blood transfusion and epoetin alfa (Espo®), which have been known to influence TAT and D-dimer, were then studied to confirm whether the variations observed were specific to heparin injection. Cemented group contained 10 patients, and non-cemented group contained 16 patients. Autologous blood transfused group contained 14 cases, and not autologous blood transfused group contained 12 cases. Epoetin alfa used group contained 12 cases, and epoetin alfa not used group contained 14 cases (see Table 1).

Table 1. Examination of possible factors affecting Thrombin-Antithrombin III Complex (TAT) or D-dimer

Group	No. of patients	Mean age (years)	No. of Heparin injection
1. Bone cement			
Presence	10 (38.5)	73.4	IH 2, NH 8
Absence	16 (61.5)	59.6	IH 10, NH 6
2. Autologous transfusion			
Transfused	14 (53.8)	60.6	IH 8, NH 6
Not transfused	12 (46.2)	69.9	IH 4, NH 8
3. Epoetin alfa			
Presence	12 (46.2)	60.5	IH 7, NH 5
Absence	14 (53.8)	68.7	IH 5, NH 9

The numbers show patients in each group. The numbers in parenthesis show the percentage of the patients in each group.

IH; group of intraoperative heparin injection. NH; group of non-injection of heparin

We defined PE and/or DVT based on only clinical symptoms (pectoralgia, decrease of arterial partial oxygen pressure, or ECG abnormalities, which are clinical manifestations indicating the possibility of PE, and pain and enlargement of the lower extremities, or Homan's sign manifestations indicating DVT).

Values of TAT and D-dimer were statistically compared between groups by t-test. Differences at P values of less than 0.05 were considered to be statistically significant.

Results

In the present study, no PE and DVT were observed. The TAT level was highest on the next day of the operation, and decreased time-dependently from day 5. On the 5th day after operation, TAT

levels in the IH group were significantly lower than those in the NH group (Figure 1).

The levels of D-dimer increased on the next day of the operation, remained high until day 14, then decreased by day 28. D-dimer levels in the IH group were significantly lower than those in the NH group on the next day of the operation (Figure 2).

Variation in blood volume loss due to heparin injection was compared to examine the safety of intraoperative heparin injection. Although both intra- and post-operative blood volume losses in the IH group were slightly more than those in NH group, there was no significant difference. Total blood volume loss was significantly higher in the IH group (Table 2).

TAT and D-dimer were not significantly influenced by the presence or absence of bone cement, autologous blood transfusion or epoetin alfa (Figures 3, 4, and, 5) .

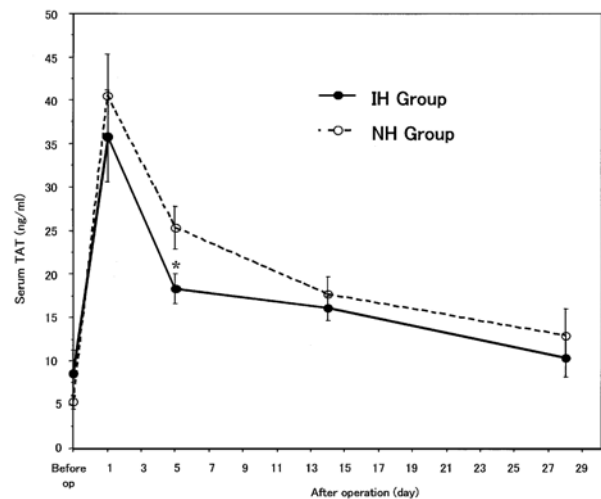


Figure 1. Effects of intravenous heparin injection during operation on serum TAT after THA. TAT in the IH group is significantly decreased on day 5. Data show mean±SEM. *: Significantly different (p < 0.05)

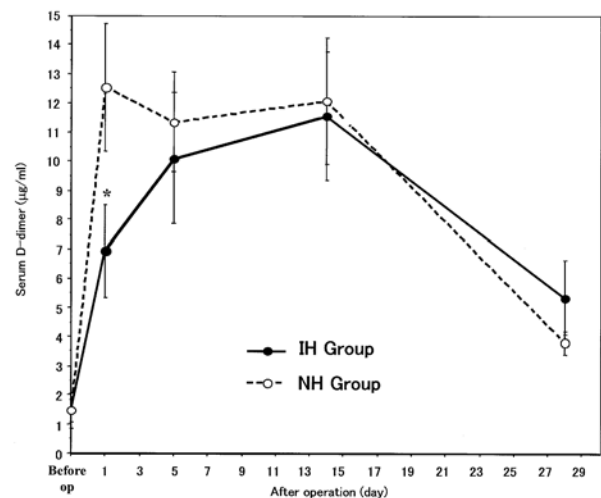
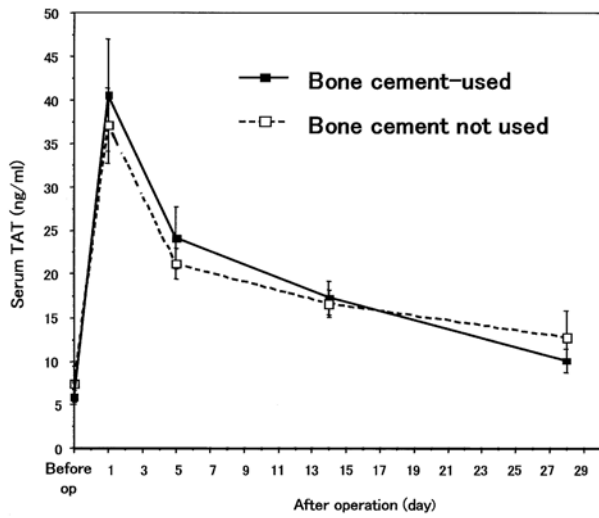


Figure 2. Effects of intravenous heparin injection during operation on serum D-dimer after THA. D-dimer in the IH Group has significantly decreased on day 1. Data show mean±SEM. *: Significantly different (p < 0.05)

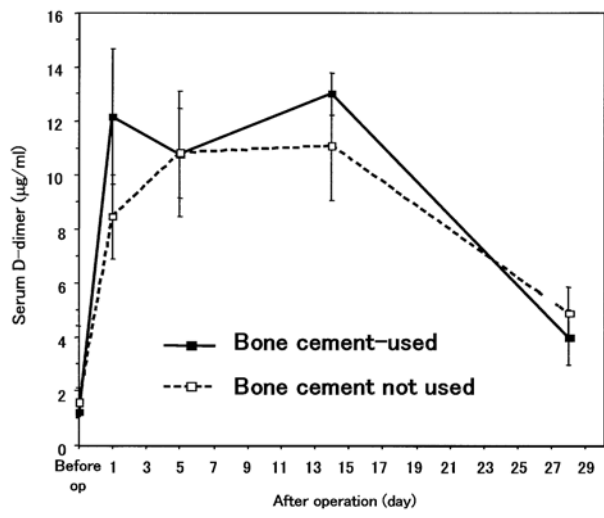
Table 2. Effects of intravenous heparin injection during operation on blood volume loss due to THA

Group	intraoperative blood loss (ml)	postoperative blood loss (ml)	total blood loss (ml)
NH	628.9 ± 240.7	289.7 ± 125.6	918.6 ± 289.8
IH	820.8 ± 287.7	363.9 ± 161.9	1184.8 ± 284.3*

Data show mean±SD. *: Significantly different (p < 0.05)

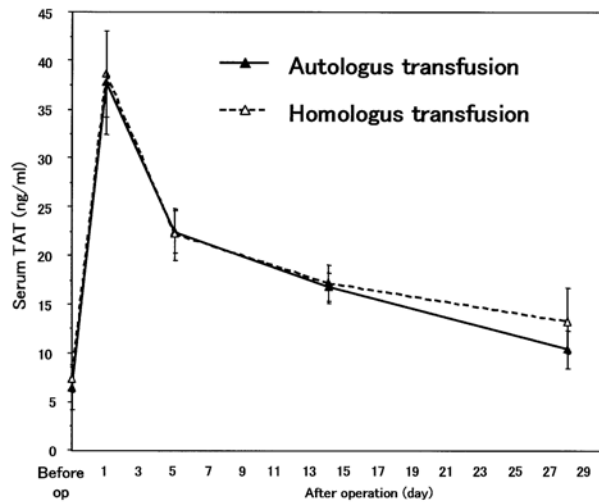


Sequential changes in TAT

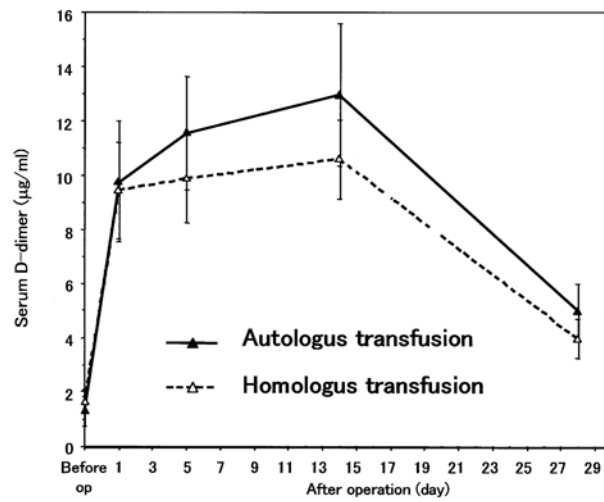


Sequential changes in D-dimer

Figure 3. Effects of the use of bone cement on serum TAT and D-dimer after operation. There is no significant difference in either TAT or D-dimer between the presence or absence of bone cement groups. Data show mean±SEM.

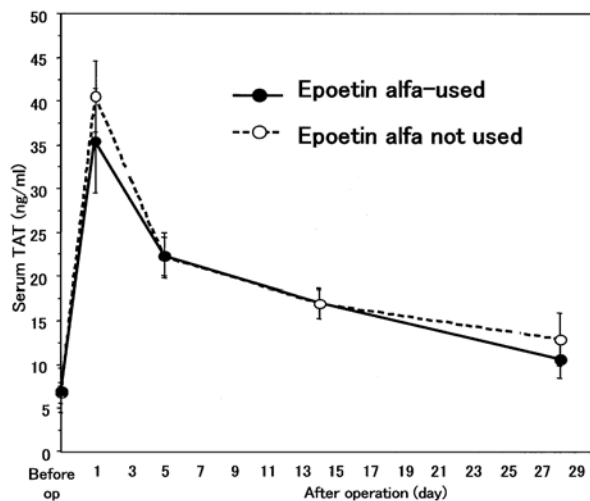


Sequential changes in TAT

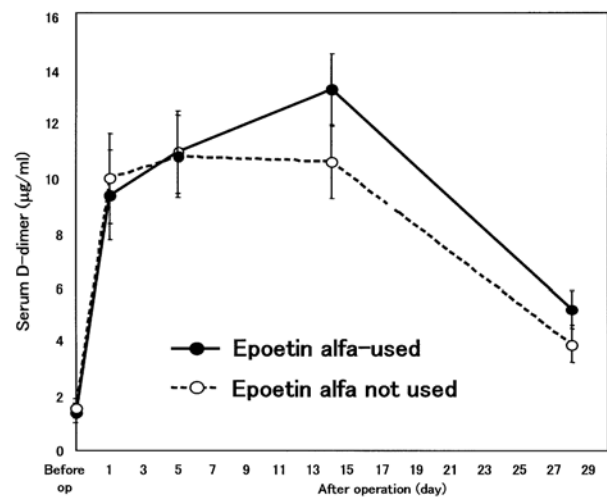


Sequential changes in D-dimer

Figure 4. Effects of autologous blood transfusion on serum TAT and D-dimer after operation. There is no significant difference in either TAT or D-dimer between the presence or absence of autologous blood transfusion groups. Data show mean±SEM.



Sequential changes in TAT



Sequential changes in D-dimer

Figure 5. Effects of epoetin alfa on serum TAT and D-dimer after operation. There is no significant difference in either TAT or D-dimer between the presence or absence of epoetin alfa groups. Data show mean \pm SEM.

Discussion

Because TAT enables precise tracking of the production of thrombin resulting from activation of coagulation, we used high TAT levels as an indicator of promotion of coagulation(1). D-dimer is a measure of FDP decomposed product D fraction, and an indicator of promotion of secondary fibrinolysis. Therefore, D-dimer acts as a sensitive indicator of fibrinolysis of thrombi in the blood vessels as well as an indicator of the presence of a thrombus(1,2). Thus, high levels of serum TAT and D-dimer are known to indicate the presence of PE and DVT. TAT and D-dimer can be measured relatively easily in clinical, therefore we considered these as possible markers for early detection of DVT and PE.

We have previously reported that a patient who developed DVT on day 28 after TKA had shown abnormally high levels of TAT on the day following operation, remaining high until day 28, with D-dimer increasing steeply on day 14 after operation(3). We have proposed a relationship between abnormally high levels of TAT and D-dimer and development of DVT(3). To establish method for the predictive diagnosis of PE after joint arthroplasty, Kubo et al. measured TAT, D-dimer, fibrin monomer, and other markers of thrombophilia time dependently(2). Their data were similar time dependent changes of serum TAT and D-dimer of our NH group.

As preventive strategies to eliminate postoperative thromboembolism, the various approaches such as mobile soon after operation, elastic stocking, intermittent pneumatic compression and foot pump, pharmacological prevention, and filtering of inferior vena cava were reported. Although many prophylaxes have been reported, there is no one best method of prophylaxis of DVT and/or PE immediately after THA and/or TKA(4). In the present study, we examined these approaches with the specific aim of preventing PE and DVT by means of pharmacological prevention.

We attempted to prevent DVT and PE by means of drugs with different modes of action, specifically heparin, aspirin and ticlopidine. None of the patients clinically developed DVT and/or PE, and no severe complications due to these preventive treatments were observed. Our results suggested that the anticoagulant and antiplatelet therapies we conducted prevent DVT and/or PE safely and effectively.

We employed intraoperative heparin injection to prevent PE immediately after THA. The administration dosage of heparin was determined to 1,000 units (assuming a patient mean weight of 50 kg) according to Sharrock et al.(5), reporting inhibition of fibrin thrombus formation during THA by 20 units/kg of injected heparin. Furthermore, Sharrock et al.(5), reported that during THA, there is minimal activation of thrombogenesis on the acetabulum, but an immediate activation of thrombosis occurs during surgery on the femur. Therefore, we decided the timing of the heparin injection immediately after femoral reaming. In the IH group, D-dimer showed significantly lower levels on the next day of the operation. We therefore conclude that formation of thrombus was inhibited during or immediately after operation by intraoperative heparin-injection. Nassif et al.(6). reported that many of the factors leading to thromboembolism occur intraoperatively, and there is abundant evidence that many of the thrombi occur intraoperatively as well. From these data, intraoperative heparin injection is very reasonable and effective prevention method against DVT and/or PE after operation. The reason why intraoperative heparin-injection affected on the TAT value on 5th day after surgery is unclear, but we thought that this reason might relate to the high incidence of PE about one week after operation. Additionally, blood volume loss was higher in the IH group; however, no homologous blood transfusions were required in patients who had undergone autologous blood transfusions. These results provide evidence that intraoperative heparin injection is a safe and effective strategy for prevention of DVT and/or PE after THA. Recently, the

low molecule heparin was reported to have less effect on bleeding tendency than un-fractionated heparin. If we used low molecule heparin, blood volume losses in IH group might be comparable with NH group.

In the present study, TAT and D-dimer were not influenced by utilization of bone cement. In our hospital, bone cement has been used for the stem fixing of aged patients rigidly and for decreasing postoperative bleeding from the medullary cavity. The risk of PE and/or DVT development by bone cementing was considered to be low. We have been using autologous blood transfusion with epoetin alfa to prevent infection due to homologous blood transfusion. Epoetin alfa acts on the hematopoietic stem cells to increase erythrocyte production as well as platelet production (7). For this reason, we believed that there might be a risk that coagulation ability would be enhanced by increased numbers of erythrocytes and platelets, but in the present study, no effects of the use of epoetin alfa on TAT or D-dimer were found. However, Mukai et al (8). reported the development of PE after THA in patients autotransfused with epoetin alfa. Therefore, it must be used with caution and further investigation will be needed.

In this study, we measured the value of TAT and D-dimer as markers of PE and/or DVT, but we don't have any case of PE and DVT clinically. We could not mention about the specific changes of TAT and D-dimer in PE and DVT cases. However, we could show the effects of intraoperative heparin injection on the value of TAT and D-dimer after THA. We need the effective prevention of PE after THA. Intraoperative heparin injection might be a good prevention method of intra or after operation. Further study is needed in order to make this prevention method be more effective and safe.

Summary

The time-dependent changes of serum TAT and D-dimer levels in patients undergoing anticoagulant and antiplatelet therapies after

THA were examined. TAT peaked on the next day of the operation, and D-dimer peaked from the next day to two weeks postoperatively. In the intraoperative heparin-injected group, a significant low value was found in TAT on the 5th day after operation, as well as D-dimer on the next day of operation compared to those in the non-injected group. Total blood volume loss was significantly increased in the heparin-injected group; however, no homologous transfusions were required in patients transfused with autologous blood. Use of bone cement, autologous blood transfusion or epoetin alfa showed no influences on sequential changes in TAT and D-dimer after THA. Intraoperative heparin injection caused no clinical complications and were concluded this therapy to be a safe and effective preventative strategy against PE and/or DVT immediately after THA.

References

1. Yanagimoto S, Yoshida H, Honma T, Fujita T, Sakamaki T. Diagnosis of deep vein thrombosis and pulmonary embolism after total hip arthroplasty: the significance of molecular markers for coagulation and fibrinolytic systems (in Japanese). *Orthopaedic Surgery and Traumatology* 44: 1179-1187, 2001
2. Kubo T, Kitajima I, Makinodan A, Niratsuka S, Inoue S, Otsuka G, et al. Fibrin monomer could be a useful predictor of pulmonary embolism after total hip arthroplasty: preliminary report. *J Orthop Sci* 6: 119-122, 2001
3. Uezono E, Nagamine S, Tomita M, Fujimoto K, Sumi M, Motokawa S, et al. Sequential changes in serum TAT and D-dimer after artificial joint replacement of the lower extremities (in Japanese). *Orthopedics & Traumatology* 50: 684-689, 2001
4. Mesko JW, Brand RA, Iorio R, Gradisar I, Heekin R, Leighton R et al. Venous Thromboembolic Disease Management Patterns in Total Hip Arthroplasty and Total Knee Arthroplasty Patients. *J Arthroplasty* 16: 679-688, 2001
5. Sharrock NE, Go G, Sculco TP, Salvati EA, Westrich GH, Harpel PC. Dose response of intravenous heparin on markers of thrombosis during primary total hip replacement. *Anesthesiology* 90: 981-7, 1999
6. Nassif JM, Ritter MA, Meding JB, Keating EM, Faris PM. The Effect of Intraoperative Intravenous Fixed-Dose Heparin During Total Joint Arthroplasty on the Incidence of Fatal Pulmonary Emboli. *J Arthroplasty* 15: 16-21, 2000
7. Berridge MV, Fraser JK, Carter JM, Lin FK. Effect of recombinant human erythropoietin on megakaryocyte and on platelet production in the rat. *Blood* 72: 970-977, 1988
8. Mukai E, Shiba M, Imai T. A death case due to pulmonary embolism after THA using autologous blood transfusion with erythropoietin (in Japanese). *Ryumachika* 16: 209-212, 1996