

Apical membrane localization of glycogen synthase kinase 3 β protein in normal colon epithelium and aberrant distribution in colorectal cancer

Hiroshi Hirakawa ^a, Toshiyuki Nakayama ^a, Kenichiro Shibata ^b, Yumi Mihara ^a, Mitsuru Taba ^a, Takeshi Nagayasu ^b, Ichiro Sekine ^a

^a Department of Tumor and Diagnostic Pathology, Atomic Bomb Disease Institute, Nagasaki University Graduate School of Biomedical Sciences, 1-12-4 Sakamoto, Nagasaki 852-8523, Japan.

Phone: +81-95-819-7107

FAX: +81-95-819-7108

E-mail: h-hira@nagasaki-u.ac.jp

^b Division of Surgical Oncology, Department of Translational Medical Sciences, Nagasaki University Graduate School of Biomedical Sciences, 1-7-1 Sakamoto, Nagasaki 852-8501, Japan

FAX: +81-95-819-7306

Abstract

Glycogen synthase kinase 3 β (GSK-3 β) was subsequently shown to function in a wide range of cellular processes. GSK-3 β is a multifunctional serine/threonine kinase which performs a role in several signaling pathways including Wnt signal transduction. Recently, the activity of membrane-localized GSK-3 β has been shown to be crucial for initiation of Wnt cascade. In our study, the membrane localization of GSK-3 β was found on the apical membrane of normal epithelium, where co-localized and directly bound with MUC1. In colorectal cancer, depolarized cells showed the aberrant distribution of GSK-3 β on the cellular membrane with β -catenin nuclear accumulation. The aberrant distribution of the membrane-localized GSK-3 β may contribute to the development of colorectal cancer.

Key words: colon, GSK-3 β , subcellular localization, immunohistochemistry

1. Introduction

The serine/threonine kinase glycogen synthase kinase 3 β (GSK-3 β) was first described for a metabolic pathway for glycogen synthesis regulation that is sensitive to insulin-mediated inhibition [1]. GSK-3 β has subsequently been shown to regulate various physiological responses, including protein synthesis, gene expression, subcellular localization of proteins, and protein degradation, in mammalian cells by phosphorylating many substrates [2-4]. GSK-3 β plays a central role in Wnt pathway [5]. In colorectal neoplasm, the activation of the Wnt signaling [6,7] or the dysfunction of the so-called β -catenin destruction complex are reported [8-10]. Upon activation of

the Wnt signaling pathway or by abnormalities/deviations in the β -catenin degradation process, β -catenin accumulates in the nucleus, where it functions as a transcriptional regulator by interacting with T-cell transcription factor (TCF) to activate Wnt-specific target genes [5]. In the cytoplasm, GSK-3 β takes in a part of the β -catenin destruction complex, which regulates the level of β -catenin by targeting it for ubiquitin-mediated proteasomal degradation [11]. However, it was reported that GSK-3 β also had important function in tumor cell proliferation via the NF- κ B pathway [12,13] and the increased expression of GSK-3 β was reported in colorectal cancer [14]. These data show discrepancy with regard to the role of GSK-3 β in the colorectal cancer development. There are only limited studies examining the involvement of GSK-3 β expression in tumor development and the findings are occasionally contradictory [14-16].

In this study, GSK-3 β was found on the apical membrane of normal colon epithelium with MUC1. The distribution of GSK-3 β was aberrant on the membrane in cancer tissue. We speculated that the aberrant distribution of active GSK-3 β may be associated to colorectal cancer development.

2. Materials and Methods

2.1. Antibodies

For detection of GSK-3 β , we obtained mouse monoclonal anti-GSK-3 β from BD Bioscience (San Jose, USA) and polyclonal rabbit anti-GSK-3 β from Santa Cruz Biotechnology (Santa Cruz, USA). Monoclonal mouse anti-phosphorylated-GSK-3 β (ser⁹) was obtained from Cell Signaling Technologies (Beverly, USA). Monoclonal mouse antibody for β -catenin was from BD Bioscience. Monoclonal mouse and

polyclonal goat antibody for MUC1 were from Santa Cruz Biotechnology.

2.3. Immunohistochemistry

Surgical specimens were subjected to this study, which were done pathological diagnosis in our institution from 2005 to 2007. All investigations were approved by our institutional review board and informed consent was obtained from all participants. Immunohistochemistry was performed on 4- μ m thick sections prepared from formalin-fixed, paraffin-embedded tissue blocks using the avidin-biotin complex detection system (Vector Laboratories, Burlingame, USA). For antigen retrieval, sections were incubated in Tris-EDTA buffer (pH 9.0) at 121°C for 15 min. The sections were examined using a Nikon Eclipse 50/inverted microscope (Nikon, Tokyo, Japan) with 10x, 20x, 40x and 100x objective lens. Histofine DAB kit (Nichirei, Tokyo, Japan) (brown) was used for detection. Control sections were incubated with isotype-matched IgG. The specificity of immunoreactivity of GSK-3 β was confirmed by pre-incubation of mouse monoclonal anti-GSK-3 β antibody with 0.1 μ g or 1 μ g of GST-GSK-3 β recombinant protein (Cell Signaling Technologies). The images were captured with a Nikon digital sight Fi1 camera (Nikon).

2.4. Immunofluorescence

After incubating with primary antibodies, the sections were incubated with secondary antibodies (Alexa 488 conjugated affinipure goat anti-mouse IgG and Alexa 555 conjugated affinipure goat anti-rabbit IgG) obtained from Molecular Probes (Eugene, OR). Slides were then mounted with Vectashield mounting medium containing 4,6-diamidino-2-phenylindole (DAPI) nuclear counterstain (Vector Laboratories, Burlingame, CA). The fluorescence images were examined using a MD2500 microscope (Leica Microsystems, Tokyo, Japan) with a x100 objective lens.

The pictures were captured with a Leica DC500 camera (Leica Microsystems).

2.5. Immunoprecipitation and immunoblotting

Cancer tissue was homogenized in ice-cold lysis buffer (50 mM Tris-Cl [pH 7.6], 150 mM NaCl, 0.1% Nonidet P-40, and 1 tablet of Complete protease inhibitor cocktail (Roche Diagnostics, Indianapolis, USA) and incubated on ice for 30 min. Lysates were cleared by centrifugation at 15,000 rpm for 20 min and 200 µg of total protein was used for immunoprecipitation. Anti-GSK-3β rabbit polyclonal and anti-MUC1 mouse monoclonal antibodies were used for Seize X Protein G Immunoprecipitation Kit (Pierce, Rockford, USA) according to the manufacture's methods. The immunoprecipitates were separated by sodium dodecyl sulfate-polyacrylamide gel electrophoresis (SDS-PAGE) and then the proteins were transferred to nitrocellulose membranes. The membranes were blocked with 5% nonfat dry milk in phosphate-buffered saline (PBS) containing 0.05% Tween 20 and then incubated with goat polyclonal anti-MUC1 (1:100), mouse monoclonal anti-GSK-3β (1:500), or monoclonal mouse anti-phosphorylated-GSK-3β (1:250) antibodies. Reactivity was detected by the use of horseradish peroxidase-conjugated secondary antibodies and chemiluminescence (ECL, Amersham Pharmaceuticals, Amersham, UK).

3. Results

3.1. Apical membrane localization of GSK-3β in colon and other epithelium

The localization of GSK-3β was on the apical membrane. We also found the expression of GSK-3β in the cytoplasm and the nucleus. Normal epithelium of small intestine and the ducts of breast also expressed GSK-3β on the apical side of the

membrane (Figs. 1-3).

3.2. Specificity of the immunoreactivity of the apical membrane localization of GSK-3 β

To confirm the specificity of anti-GSK-3 β antibody, anti-GSK-3 β antibody was incubated with 0.1 μ g or 1 μ g of GST-GSK-3 β recombinant protein (Cell Signaling Technologies) (Fig. 4).

3.3. Co-distribution of GSK-3 β and MUC1 in colon epithelial cells

In our study, the distribution of GSK-3 β was similar to MUC1 and the molecular interaction of GSK-3 β and MUC1 was shown previously [17]. In normal colon epithelium and colorectal cancer, MUC1 is known to be located on the apical membrane, and is often used for detection of this polarity for clinical diagnosis [18-21]. We speculated that GSK-3 β and MUC1 are co-distributed on the cellular membrane. In our study, we found that both GSK-3 β and MUC1 on the apical membrane. Immunoprecipitation with colorectal cancer tissues showed the direct binding of GSK-3 β and MUC1. However, no phosphorylated GSK-3 β (Ser⁹) was immunoprecipitated with MUC1 antibody.

3.4. Distribution of GSK-3 β and association to β -catenin nuclear accumulation in colorectal cancer

In this study, clusters of cancer cells at the invasive front, known as tumor budding, frequently showed β -catenin nuclear accumulation (Fig. 4B2). Histopathological findings of tumor budding is reported to be related to the malignant behavior of colorectal cancer [22,23]. Those cells showed aberrant GSK-3 β expression, notably on

the cellular membrane (Fig. 4C), where cancer cells got an unusual interaction with extracellular matrix.

Discussion

This is the first report to show the distribution of membrane-localized GSK-3 β with MUC1 on the apical side of normal epithelium with human tissue. MUC1 is a glycoprotein normally located on the apical membrane of normal glandular epithelium [18] and aberrant expression of MUC1 was reported various cancers [18-21]. We found the aberrant of GSK-3 β , which is associated to the β -catenin nuclear accumulation. Numerous reports showed that the β -catenin nuclear accumulation at the invasive front contributes to poor prognosis [24,25]. However, nothing is known about why the nuclear accumulation of β -catenin was detected mainly at the invasive front of cancer.

Recently, a novel mechanism of GSK-3 β for the activation of Wnt signaling was reported. GSK-3 β was reported to phosphorylate low-density-lipoprotein-related protein (LRP), co-receptor of Wnt protein [26]. On the cellular membrane, phosphorylation of LRP by GSK-3 β and casein kinase (CKI) γ recruits axin to the plasma membrane, where it is inactivated and/or targeted for degradation, resulting in the β -catenin stability [27]. In the model, the activity of membrane-localized GSK-3 β is considered crucial for initiation of Wnt cascade.

In our study, depolarized cells at the invasive front, which lost apical/basal polarity, showed unusual interaction of membrane-localized GSK-3 β and extracellular matrix. Most Wnt proteins transmit signals locally, since their secretion is under tight control in normal epithelium. Heparan sulfate proteoglycans, extracellular matrix protein, are considered to regulate the transport of Wnt proteins [28-30]. The Wnt of secreted signal proteins were reported to play a key role in numerous aspects of embryogenesis, as well as in carcinogenesis [31-33]. We speculated that the particular distribution of GSK-3 β may have an unusual interaction with Wnt protein storage of extracellular

matrix, resulting in Wnt signaling activation. Further investigation is needed to clarify the role of GSK-3 β on tumor progression.

References

- [1] S.E. Plyte, K. Hughes, E. Nikolakaki, B.J. Pulverer, J.R. Woodgett, Glycogen synthase kinase-3: functions in oncogenesis and development, *Biochim. Biophys. Acta.* 1114 (1992) 147-162.
- [2] P. Cohen, S. Frame, The renaissance of GSK3, *Nat. Rev. Mol. Cell Biol.* 2 (2001) 769-776.
- [3] B.W. Doble, J.R. Woodgett, GSK-3: tricks of the trade for a multi-tasking kinase, *J. Cell Sci.* 116 (2003) 1175-1186.
- [4] C.A Grimes, R.S. Jope, The multifaceted roles of glycogen synthase kinase 3beta in cellular signaling, *Prog. Neurobiol.* 65 (2001) 391-426
- [5] B. Rubinfeld, I. Albert, E. Porfiri, C. Fiol, S. Munemitsu, P. Polakis, Binding of GSK3beta to the APC-beta-catenin complex and regulation of complex assembly, *Science* 272 (1996) 1023-1026.
- [6] A. Dimitriadis, E. Vincan, I.M. Mohammed, N. Roczo, W.A. Phillips, S. Baidur-Hudson, Expression of Wnt genes in human colon cancers, *Cancer Lett.* 166 (2001) 185-191.
- [7] K. Smith, T.D. Bui, R. Poulson, L. Kaklamanis, G. Williams, A.L. Harris, Up-regulation of macrophage wnt gene expression in adenoma-carcinoma progression of human colorectal cancer, *Br. J. Cancer.* 81 (1999) 496-502.
- [8] K.W. Kinzler, B. Vogelstein, Lessons from hereditary colorectal cancer, *Cell* 87 (1996)

159-170.

- [9] P.J. Morin, A.B. Sparks, V. Korinek, N. Barker, H. Clevers, B. Vogelstein, K.W. Kinzler, Activation of beta-catenin-Tcf signaling in colon cancer by mutations in beta-catenin or APC, *Science* 275 (1997) 1787-1790.
- [10] J.H. van Es, N. Barker, H. Clevers, You Wnt some, you lose some: oncogenes in the Wnt signaling pathway, *Curr. Opin. Genet. Dev.* 13 (2003) 28-33.
- [11] P. Polakis, The many ways of Wnt in cancer, *Curr. Opin. Genet. Dev.* 17 (2007) 45-51.
- [12] K.P. Hoeflich, J. Luo, E.A. Rubie, M.S. Tsao, O. Jin, J.R. Woodgett, Requirement for glycogen synthase kinase-3beta in cell survival and NF-kappaB activation, *Nature* 406 (2000) 86-90.
- [13] R.F. Schwabe, D.A. Brenner, Role of glycogen synthase kinase-3 in TNF-alpha-induced NF-kappaB activation and apoptosis in hepatocytes. *Am. J. Physiol. Gastrointest. Liver Physiol.* 283 (2002) G204-211.
- [14] A. Shakoory, A. Ougolkov, Z.W. Yu, B. Zhang, M.H. Modarressi, D.D. Billadeau, M. Mai, Y. Takahashi, T. Minamoto, Deregulated GSK3beta activity in colorectal cancer: its association with tumor cell survival and proliferation, *Biochem. Biophys. Res. Commun.* 334 (2005) 1365-1373.
- [15] M. Farago, I. Dominguez, E. Landesman-Bollag, X. Xu, A. Rosner, R.D. Cardiff, D.C. Seldin, Kinase-inactive glycogen synthase kinase 3beta promotes Wnt signaling and mammary tumorigenesis, *Cancer Res.* 65 (2005) 5792-5801.

- [16] A.V. Ougolkov, M.E. Fernandez-Zapico, D.N. Savoy, R.A. Urrutia, D.D. Billadeau, Glycogen synthase kinase-3beta participates in nuclear factor kappaB-mediated gene transcription and cell survival in pancreatic cancer cells, *Cancer Res.* 65 (2005) 2076-2081.
- [17] Y. Li, A. Bharti, D. Chen, J. Gong, D. Kufe D, Interaction of glycogen synthase kinase 3beta with the DF3/MUC1 carcinoma-associated antigen and beta-catenin, *Mol. Cell Biol.* 18 (1998) 7216-7224.
- [18] D. Kufe, G. Inghirami, M. Abe, D. Hayes, H. Justi-Wheeler, J. Schlom, Differential reactivity of a novel monoclonal antibody (DF3) with human malignant versus benign breast tumors, *Hybridoma* 3 (1984) 223-232.
- [19] G. Pettinato, C.J. Manivel, L. Panico, L. Sparano, G. Petrella, Invasive micropapillary carcinoma of the breast: clinicopathologic study of 62 cases of a poorly recognized variant with highly aggressive behavior, *Am. J. Clin. Pathol.* 121 (2004) 857-866.
- [20] H. Nassar, V. Pansare, H. Zhang, M. Che, W. Sakr, R. Ali-Fehmi, D. Grignon, F. Sarkar, J. Cheng, V. Adsay, Pathogenesis of invasive micropapillary carcinoma: role of MUC1 glycoprotein, *Mod. Pathol.* 17 (2004) 1045-1050.
- [21] K. Sakamoto, M. Watanabe, C. De La Cruz, H. Honda, H. Ise, K. Mitsui, K. Namiki, Y. Mikami, T. Moriya, H. Sasano, Primary invasive micropapillary carcinoma of the colon, *Histopathology* 4 (2005) 479-484.
- [22] T. Nakamura, H. Mitomi, H. Kanazawa, Y. Ohkura, M. Watanabe, Tumor budding

as an index to identify high-risk patients with stage II colon cancer, *Dis. Colon Rectum* 51 (2008) 568-572.

[23] K. Guzińska-Ustymowicz, The role of tumour budding at the front of invasion and recurrence of rectal carcinoma. *Anticancer Res.* 25 (2005) 1269-1272.

[24] B. Zhang, A. Ougolkov, K. Yamashita, Y. Takahashi, M. Mai, T. Minamoto, beta-Catenin and ras oncogenes detect most human colorectal cancer, *Clin. Cancer Res.* 9 (2003) 3073-3079.

[25] A.V. Ougolkov, K. Yamashita, M. Mai, T. Minamoto, Oncogenic beta-catenin and MMP-7 (matrilysin) cosegregate in late-stage clinical colon cancer, *Gastroenterology* 122 (2002) 60-71.

[26] X. Zeng, K. Tamai, B. Doble, S. Li, H. Huang, R. Habas, H. Okamura, J. Woodgett, X. He, A dual-kinase mechanism for Wnt co-receptor phosphorylation and activation, *Nature* 438 (2005) 873-877.

[27] K.M. Cakigan, Y.I. Liu, Wnt signaling: complexity at the surface, *J. Cell Sci.* 119 (2005) 395-402.

[28] U. Häcker, K. Nybakken, N. Perrimon, Heparan sulphate proteoglycans: the sweet side of development, *Nat. Rev. Mol. Cell Biol.* 67 (2005) 530-541.

[29] X. Lin, Functions of heparan sulfate proteoglycans in cell signaling during development, *Development* 131 (2004) 6009-6021.

[30] G.H. Baeg, X. Lin, N. Khare, S. Baumgartner, N. Perrimon, Heparan sulfate

proteoglycans are critical for the organization of the extracellular distribution of Wingless, *Development*. 128 (2001) 87-94.

[31] C.Y. Logan, R. Nusse, The Wnt signaling pathway in development and disease, *Annu. Rev. Cell Dev. Biol.* 20 (2004) 781-810

[32] R.T. Moon, A.D. Kohn, G.V. De Ferrari, A. Kaykas, WNT and beta-catenin signalling: diseases and therapies, *Nat. Rev. Genet.* 5 (2004) 691-701.

[33] T. Reya, H. Clevers, Wnt signalling in stem cells and cancer, *Nature*. 14 (2005) 843-850.

Figure legends

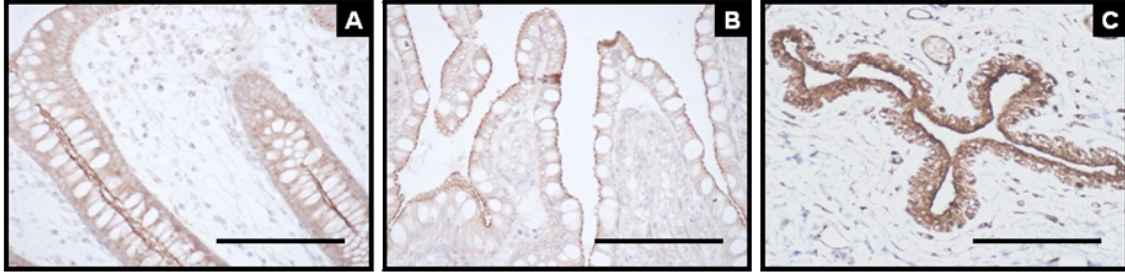


Figure 1.

Cellular distribution of GSK-3 β in normal epithelium. (A) normal colon epithelium. (B) Normal small intestine. (C) Ducts of mammary gland. The immunoreactivity of GSK-3 β was on the apical side of the membrane of epithelial cells. Bar, 100 μ m.

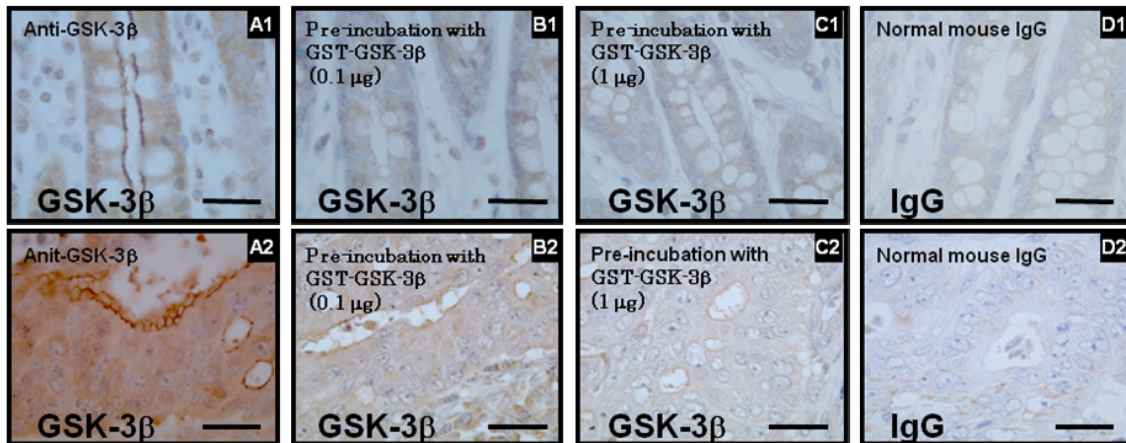


Figure 2.

The specificity of immunoreactivity of GSK-3 β in normal colon epithelium (A1-D1)

and colorectal cancer (A2-D2). (A-D) The immunoreactivity of GST-3 β was

predominantly on the cellular membrane. (B), (C) The antibody was pre-incubated

with GST-GSK-3 β recombinant protein or normal mouse IgG. (B) 0.1 μ g of

GST-GSK-3 β recombinant protein. (C) 1 μ g of GST-GSK-3 β recombinant protein.

(D) Normal mouse IgG1. Bar, 25 μ m.

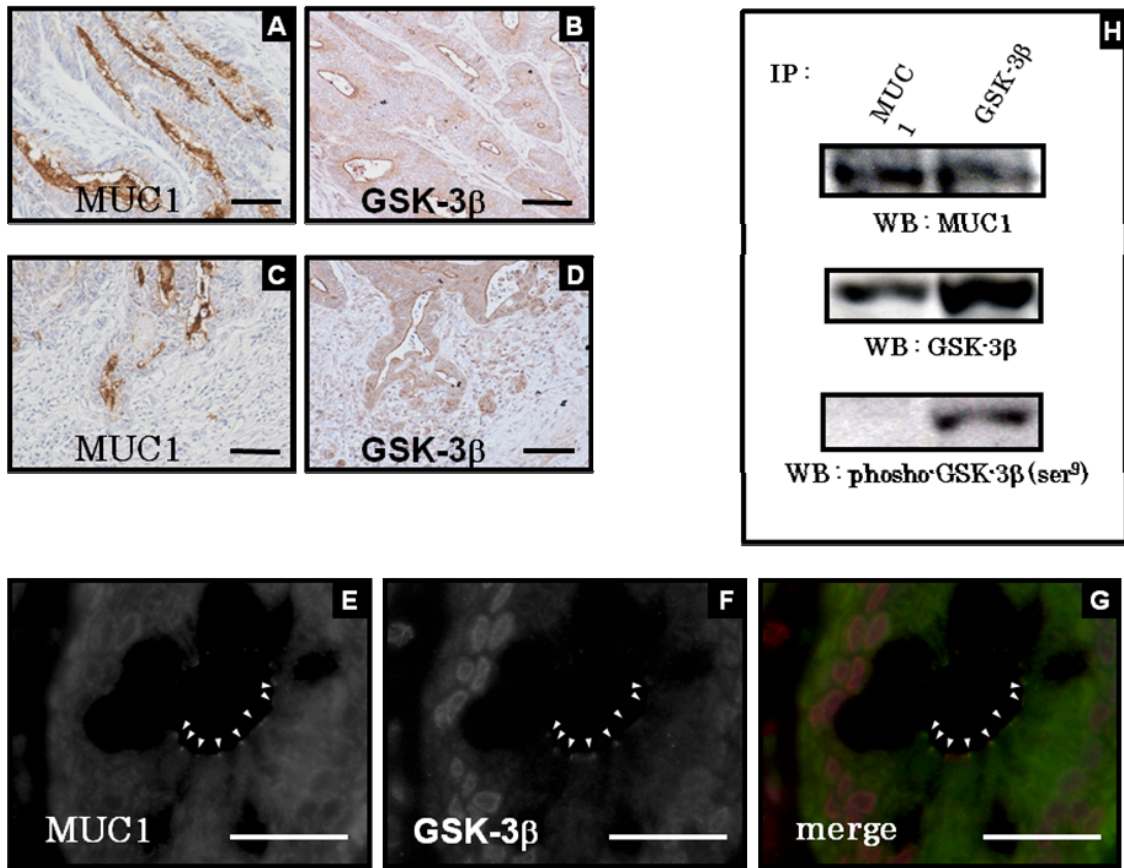


Figure 3.

Interaction of GSK-3 β and MUC1. Immunohistochemistry of GSK-3 β and MUC1(A-D). (A) and (C) MUC1 expressed on the apical side. (A) Central area of cancer tissue. (C) Invasive front. (B) and (D) GSK-3 β was expressed on the apical side. (B) Central area of cancer tissue. (D) Invasive front. Bar, 100 μ m. (E)-(G) Double immunofluorescence in normal colon mucosa. Monoclonal MUC1 (green) and polyclonal GSK-3 β (red) antibodies were used. (E) MUC1 was detected on the apical membrane. (F) GSK-3 β was found on the apical membrane and in the cytoplasm and the nucleus in normal epithelium. (G) Co-distribution of both MUC1 and GSK-3 β was detected on the apical membrane. Bar, 25 μ m.

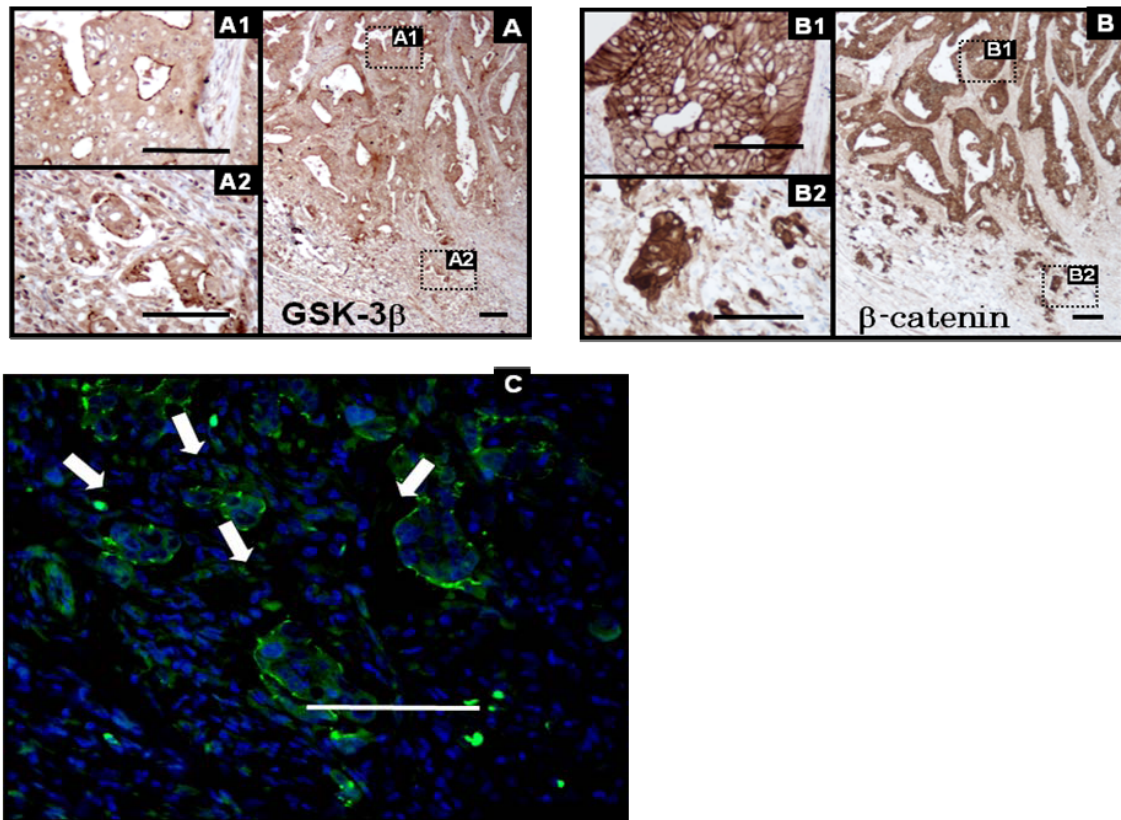


Figure 4.

Low and high magnification of immunostaining for GSK-3 β and β -catenin in colorectal cancer. (A) The expression of GSK-3 β (A1) GSK-3 β was detected on the apical side of cancer cell in the central area of cancer tissue. (A2) The aberrant distribution of GSK-3 β was on the membrane of depolarized cancer cell at the invasive front. (B1) β -catenin was detected on the cellular membrane in the central area. (B2) the nuclear accumulation of β -catenin was found at the invasive front. Bar, 100 μ m.