

Intraductal papillary mucinous neoplasm of the pancreas with a bifid pancreatic duct

Yoshitsugu Tajima, M.D., Ph.D., Tomohiko Adachi, M.D., Tamotsu Kuroki, M.D., Ph.D., Noritsugu Tsuneoka, M.D., Ph.D., Takehiro Mishima, MD., Taiichiro Kosaka, M.D., Takashi Kanematsu, M.D., Ph.D

Department of Surgery, Nagasaki University Graduate School of Biomedical Sciences, 1-7-1 Sakamoto, Nagasaki 852-8501, Japan.

Running head: Bifid pancreatic duct

Key words: bifid pancreatic duct; endoscopic retrograde pancreatography; intraductal papillary mucinous neoplasm of the pancreas; intraoperative ultrasonography; pancreatic resection

Correspondence to: Yoshitsugu Tajima, M.D., Department of Surgery, Nagasaki University Graduate School of Biomedical Sciences, 1-7-1 Sakamoto, Nagasaki 852-8501, Japan

TEL: 81-95819-7316

FAX: 81-95819-7319

E-mail: ytajima@net.nagasaki-u.ac.jp

Abstract

A bifid pancreatic duct presenting a major bifurcation in the main pancreatic duct is one of the anatomical variations of the pancreatic ducts. We encountered a 71-year-old female with a 5-cm-diameter branch duct intraductal papillary mucinous neoplasm of the pancreas in whom preoperative endoscopic retrograde pancreatography demonstrated an anomalous bifurcation of the main pancreatic duct at the body of the pancreas. We performed a distal pancreatectomy, instead of a middle pancreatectomy, with a cutting line at the downstream pancreas to the duct bifurcation point. Intraoperative ultrasonography was useful to confirm the exact location of the pancreatic duct bifurcation as well as the tumor extension. The procedure resulted in a favorable outcome without any postoperative complications. Although a bifid pancreatic duct is an unusual anomalous condition, this case should alert surgeons to be aware of such anatomical variants when performing pancreatic resection, otherwise, incurable pancreatic complications may occur postoperatively.

Introduction

It is well known that various forms of developmental abnormalities of the pancreas, including pancreas divisum,¹ annular pancreas,² aberrant pancreas,³ and pancreatic hypoplasia,⁴ can occur. The wide application of endoscopic retrograde pancreatography (ERP) and recent advances in magnetic resonance (MR) cholangiopancreatography have allowed the identification of such anatomical variants involving the pancreatic duct system. A bifid pancreatic duct presenting a major bifurcation in the main pancreatic duct is one of the anatomical variations of the pancreatic ducts, however, this unusual condition could account for troublesome postoperative complications when pancreatic resections are indicated. This report describes a case with a branch duct intraductal papillary mucinous neoplasm (IPMN) of the pancreas in which preoperative ERP demonstrated a bifid configuration of the main pancreatic duct in the body of the pancreas.

Case report

A 71-year-old female was admitted to our hospital in May 2007 for further investigation of a cystic tumor in the body of the pancreas. Approximately 15 years previously, the patient noticed occasional mild

back pain and a subsequent computed tomography (CT) examination of the abdomen revealed a cystic tumor, measuring 1 cm in diameter, in the body of the pancreas. Thereafter, she was followed up at an outside hospital. In January 2003, the cystic tumor of the pancreas had enlarged to 3 cm in diameter and the follow-up was continued. Recently, the patient began to suffer from back pain after meals and therefore was referred to this hospital.

On admission, her body temperature was 36.4°C, pulse was 76/min, and blood pressure was 108/78 mmHg. A physical examination revealed a mild tenderness in the epigastric region. No mass was palpable in her abdomen. The laboratory data and tumor markers, including carcinoembryonic antigen (CEA) and carbohydrate antigen 19-9 (CA19-9), were all within the normal limits. Abdominal CT scans and MR imaging studies revealed a unilocular cystic tumor, measuring 5 cm in diameter, in the body of the pancreas. The tumor showed neither enhancement nor solid components within the cyst wall on contrast-enhanced CT examinations. MR cholangiopancreatography showed the main pancreatic duct to not be dilated either proximal or distal to the pancreatic tumor (**Figure 1**). ERP depicted a cystic tumor in contact with the main pancreatic duct via a pancreatic branch in the body of the pancreas. In addition, the ERP clearly demonstrated an anomalous bifurcation of the main pancreatic duct at the body of the pancreas (**Figure 2**). Although no mucin secretion via the

ampula of Vater was observed, these findings indicated the possibility of a branch duct IPMN of the pancreas with a bifid pancreatic duct. The patient was therefore indicated to undergo a laparotomy for a potential malignancy because of the increasing and large-sized cystic tumor, exceeding 30 mm in diameter, and the associated clinical symptoms. To achieve a complete removal of the pancreatic tumor along with the preservation of pancreatic exocrine and endocrine functions, a middle pancreatectomy was proposed as the optimal treatment for the patient. However, two major pancreatic duct orifices might be exposed on the transection plane of the remnant distal pancreas during the middle pancreatectomy. Therefore, a distal pancreatectomy was performed on this patient. During the surgery, intraoperative ultrasonography (IOUS) was utilized to identify the tumor extension and exact location of the pancreatic duct bifurcation. The transection line of the pancreas was set on the downstream side to the duct bifurcation as well as the pancreatic tumor, and then the pancreatic parenchyma was carefully divided with an ultrasonic device. The "single" main pancreatic duct was identified and isolated from the pancreatic parenchyma, and cut after ligation with an absorbable suture. A frozen section examination showed that the surgical margin of the pancreatic stump was free of atypical or cancer cells. Postoperative pancreatography of the resected pancreatic specimen demonstrated a bifid secondary pancreatic duct draining the distal pancreas along with a pancreatic cystic

tumor communicating with the main pancreatic duct (**Figure 3**). Histologically, the pancreatic lesion was a multilocular cystic tumor with thin septa and diagnosed as noninvasive adenocarcinoma of IPMN. The patient's postoperative course was uneventful and she was discharged 16 days after surgery.

Discussion

The anatomical variants of the pancreas are grossly classified into 3 types⁵ according to the embryological developmental aspects: (1) Migration variants (annular pancreas and aberrant pancreas), (2) Fusion variants (pancreas divisum and functional divisum), and (3) Duplication variants (number variants and form variants). The bifid pancreatic duct is categorized as a number variant of a duplication anomaly. The pancreas develops from the dorsal and ventral elements arising from the foregut, which normally fuse with each other during the second month of the embryonic development. The ventral pancreatic bud gives rise to a portion of the pancreatic head and to the uncinate process, while the rest of the pancreatic gland develops from the dorsal pancreatic bud.^{6,7} The ventral bud is initially bilobed and the bilobed configuration eventually regresses in most individuals, although a remnant may persist and possibly cause anomalies or variants of the uncinate branches as well as aberrant

pancreatic tissue in the gut.⁸ The dorsal pancreatic element may also be bilobed, thus possibly accounting for the anomalous bifurcation in the main pancreatic duct.⁹

Among the various anatomical variants of the pancreatic duct system, the bifid pancreatic duct is a relatively rare condition especially in adults. A large series of ERP investigation demonstrated the frequency of this anomalous pancreatic duct to be 0.9-2.7%.^{10,11} The clinical significance of the bifid pancreatic duct, including the development of pancreatic tumors as seen in the present case, still remains unclear. Bang *et al.*¹⁰ as well as Uomo *et al.*¹¹ demonstrated no significant relationship between various pancreatic duct anomalies and pancreaticobiliary diseases or clinical conditions. However, anomalies of the pancreatic duct system, including the bifid pancreatic duct, could present as troublesome problems when pancreatic resections are indicated.^{12,13} In the present case, preoperative ERP findings provided useful information for understanding the configuration of the bifid pancreatic duct as well as the pancreatic IPMN and for planning the optimal treatment strategy. Although branch duct IPMNs can be candidates for limited pancreatectomy,^{14,15} a distal pancreatectomy was thus performed instead of a middle pancreatectomy, with a cutting line at the pancreas downstream of the duct bifurcation point to avoid postoperative serious pancreatic complications because the bifid secondary pancreatic duct appeared to be too small in diameter to

anastomose appropriately without post operative pancreatic leakage or too large in its drainage area to ligate and sacrifice. IOUS was useful for confirming the exact location of the pancreatic duct bifurcation as well as the tumor extension and also for determining the appropriate transection line for the pancreas. Ohkubo *et al.*¹² demonstrated the efficacy of IOUS and IOUS-guided pancreatography in performing a successful pancreaticoduodenectomy in a patient with a bifid pancreatic duct associated with carcinoma of the duodenal papilla. On the other hand, Yoshida *et al.*¹³ reported a pancreaticojejunostomy with double duct-to-mucosa anastomotic technique after a pylorus-preserving pancreaticoduodenectomy for chronic pancreatitis with a bifid pancreatic duct.

Although an anomalous bifurcation of the main pancreatic duct is an unusual anatomical disorder, a lack of knowledge regarding the possible presence of such pancreatic duct anomalies could lead to incurable postoperative pancreatic complications, including pancreatic leakage and obstructive pancreatitis. The preoperative evaluation as well as intraoperative assessment of the pancreatic duct system is therefore important when performing pancreatic resections in patients associated with pancreatic duct anomalies. ERP should be the confirmative modality for diagnosis and treatment of these patients, even though MR

cholangiopancreatography has emerged as an effective noninvasive alternative procedure.

References

1. Cotton PB. Congenital anomaly of pancreas divisum as cause of obstructive pain and pancreatitis. *Gut*. 1980 21(2):105-14.
2. Kiernan PD, ReMine SG, Kiernan PC, ReMine WH. Annular pancreas: May Clinic experience from 1957 to 1976 with review of the literature. *Arch Surg*. 1980 115(1):46-50.
3. FELDMAN M, WEINBERG T. Aberrant pancreas: a cause of duodenal syndrome. *J Am Med Assoc*. 1952 148(11):893-8
4. Suda K, Matsumoto Y, Fujii H, Miura K, Nobukawa B. Clinicopathologic differentiation of atrophy of the pancreatic body and tail aplasia. *Int J Pancreatol*. 1998 24(3):227-35.
5. Siegel JH, ed. Radiologic interpretation: normal biliary system and variations; normal pancreatic duct and variations. In: *Endoscopic retrograde cholangiopancreatography: Technique, Diagnosis and Therapy*. New York: Raven Press Ltd; 1992. P. 25-59.
6. Laitio M, Lev R, Orlic D. The developing human fetal pancreas: an ultrastructural and histochemical study with special reference to exocrine cells. *J Anat*. 1974 117(3):619-34
7. Adda G, Hannoun L, Loygue J. Development of the human pancreas: variations and pathology. A tentative classification. *Anat Clin*. 1984 5(4):275-83.

8. PEARSON S. Aberrant pancreas. Review of the literature and report of three cases, one of which produced common and pancreatic duct obstruction. *AMA Arch Surg.* 1951 63(2):168-86
9. Halpert RD, Shabot JM, Hearse BR, Rogers RE. The bifid pancreas: a rare anatomical variation. *Gastrointest Endosc.* 1990 36(1):60-1
10. Bang S, Suh JH, Park BK, Park SW, Song SY, Chung JB. The relationship of anatomic variation of pancreatic ductal system and pancreaticobiliary diseases. *Yonsei Med J.* 2006 47(2):243-8.
11. Uomo G, Manes G, D'Anna L, La ccetti M, Di Gaeta S, Rabitti PG. Fusion and duplication variants of pancreatic duct system. Clinical and pancreatographic evaluation. *Int J Pancreatol.* 1995 17(1):23-8
12. Ohkubo T, Imamura H, Sugawara Y, Takayama T, Makuuchi M. Successful pancreatic duct-to-jejenum anastomosis in a patient with a double pancreatic duct: usefulness of intraoperative ultrasonography (IOUS) and IOUS-guided pancreatography. *Hepatogastroenterology.* 2002 49(48):1724-5.
13. Yoshida T, Ninomiya S, Morii Y, Matsumata T, Arimura E, Hidaka H. Double duct-to-mucosa pancreaticojejunosotomy for bifid pancreatic duct. *Hepatogastroenterology.* 2004 51(58):1196-7
14. Kim SC, Park KT, Lee YJ, Lee SS, Seo DW, Lee SK, Kim MH, Jang SJ, Byun JH, Han DJ. Intraductal papillary mucinous neoplasm of the pancreas: clinical characteristics and treatment outcomes of 118

consecutive patients from a single center. J Hepatobiliary Pancreat Surg.
2008 15(2):183-8

- 15.** Beger HG, Gansauge F, Siech M, Schwarz M, Poch B.
Duodenum-preserving total pancreatic head resection for cystic
neoplastic lesions in the head of the pancreas. J Hepatobiliary Pancreat
Surg. 2008;15(2):149-56

Figure legends

Figure 1. MR cholangiopancreatography outlines the entire main pancreatic duct (arrows) and a cystic tumor in the body of the pancreas. No remarkable findings are noted in the main pancreatic duct. GB: gallbladder.

Figure 2. ERP demonstrating a bifid secondary pancreatic duct (white arrow) at the body of the pancreas and a cystic tumor (black arrows) connecting with the main pancreatic duct.

Figure 3. Postoperative pancreatography of the resected specimen clearly demonstrates the bifid secondary pancreatic duct (white arrow). The contrast material was injected via the main pancreatic duct orifice exposed on the transsection plane of the pancreas. MPD: main pancreatic duct.

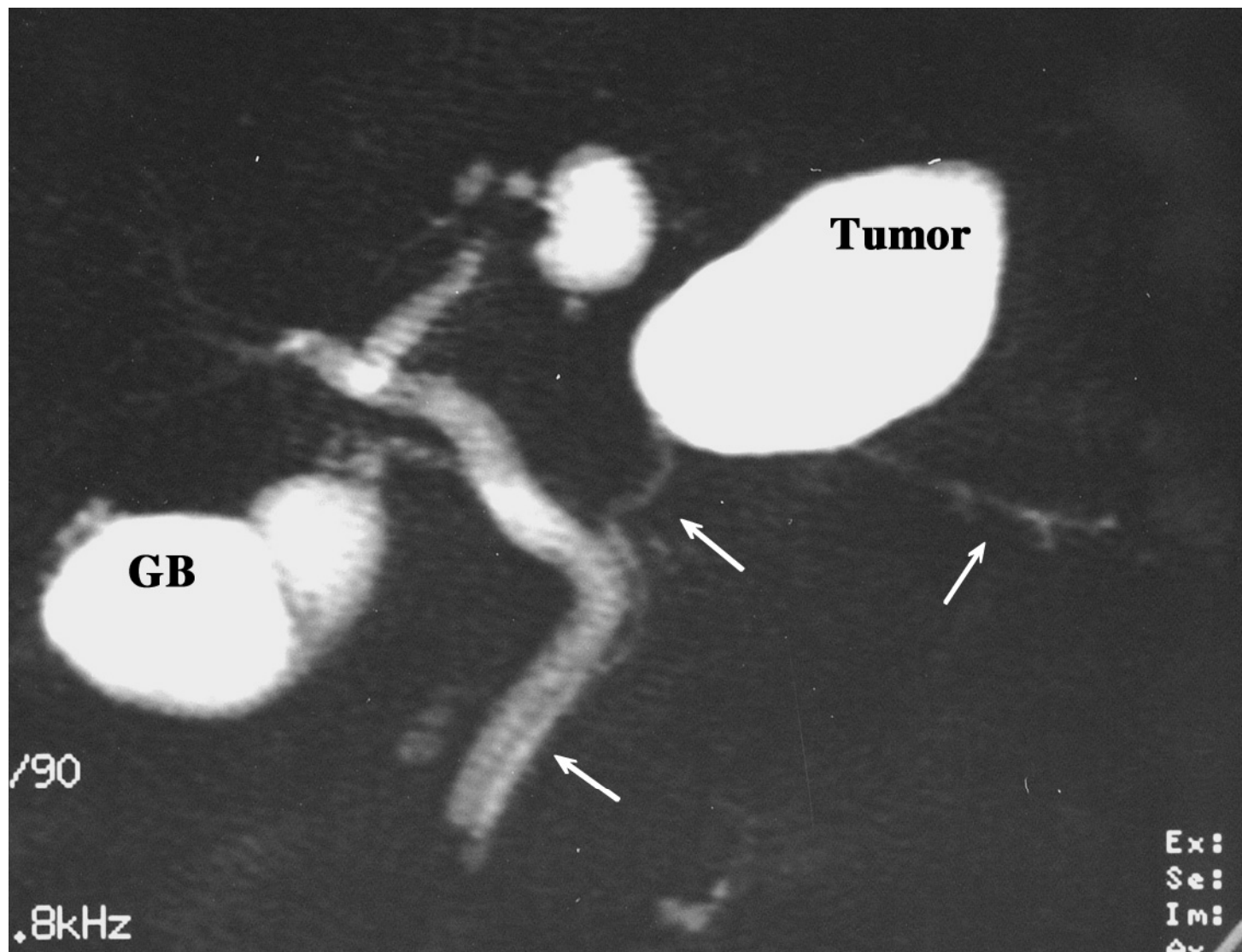


Figure 1

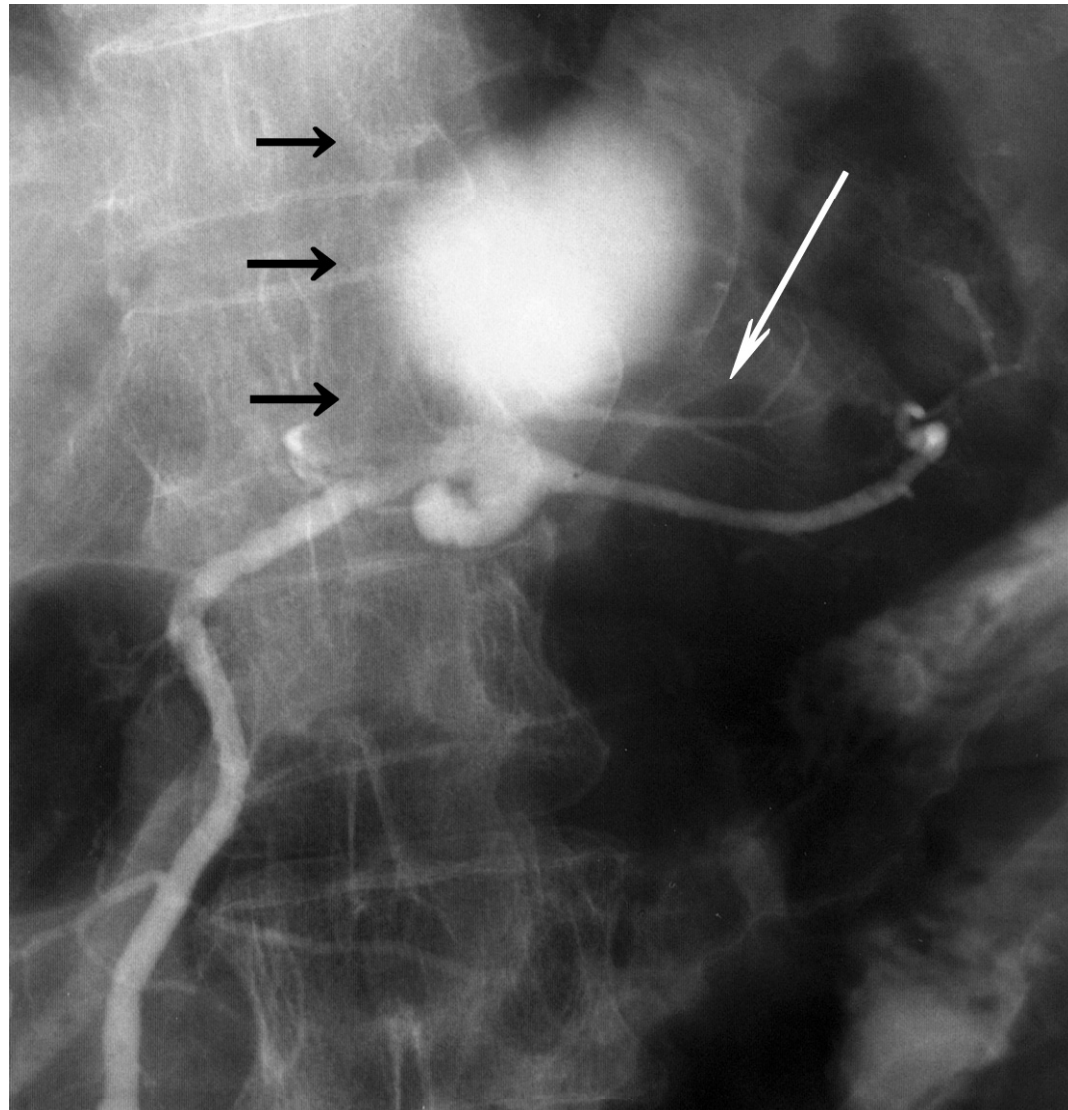


Figure 2

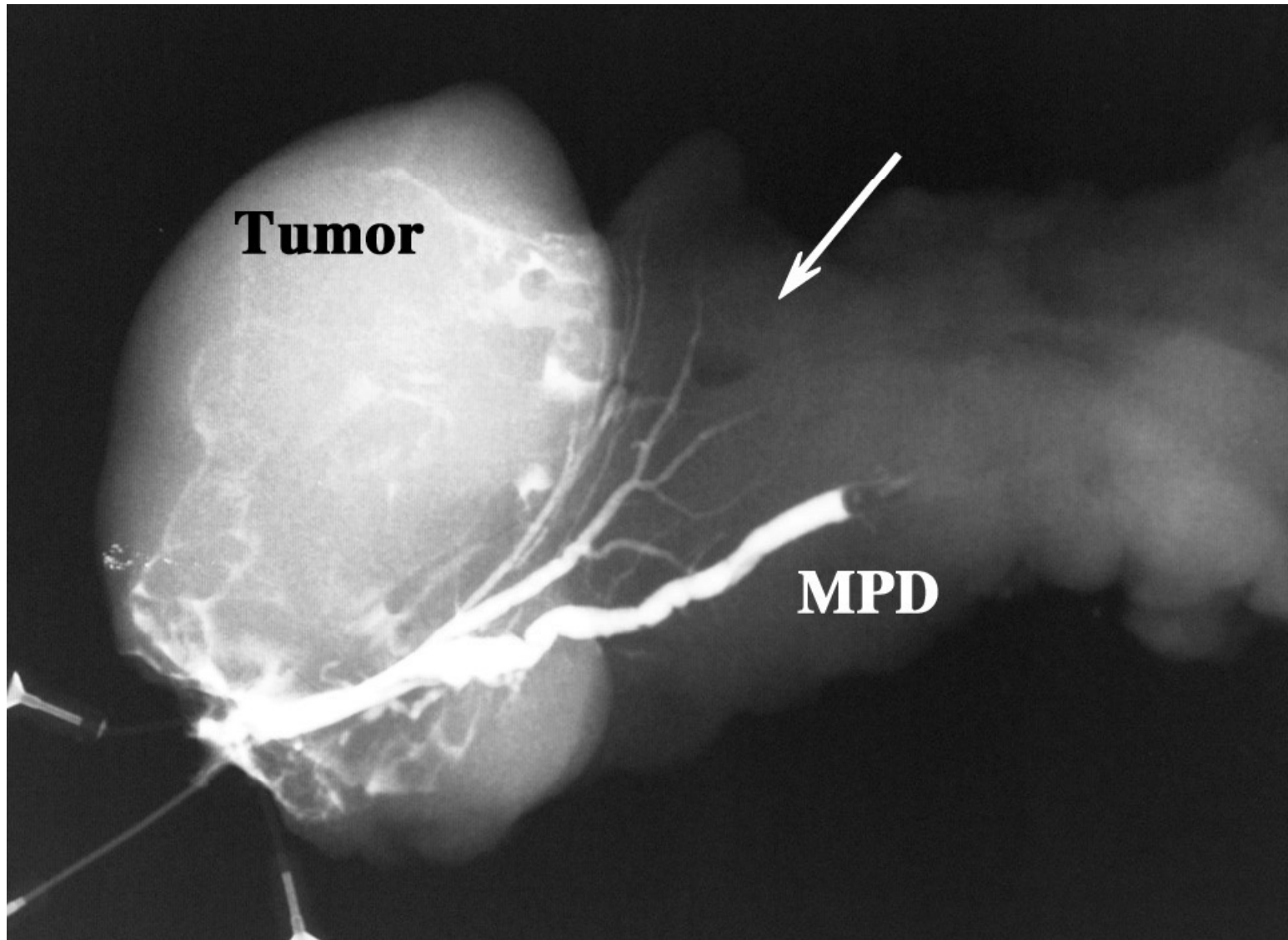


Figure 3