

**A case of pulmonary cryptococcosis followed by pleuritis in an apparently
immunocompetent patient during fluconazole treatment**

KOICHI IZUMIKAWA¹, YONG ZHAO¹, KOHEI MOTOSHIMA¹, TAKAHIRO
TAKAZONO¹, TOMOMI SAIJO¹, SINTARO KURIHARA¹, SHIGEKI
NAKAMURA¹, TAIGA MIYAZAKI¹, MASAFUMI SEKI¹, HIROSHI KAKEYA¹,
YOSHIHIRO YAMAMOTO¹, KATSUNORI YANAGIHARA^{1,2}, YOSHITSUGU
MIYAZAKI¹, TOMAYOSHI HAYASHI³ and SHIGERU KOHNO¹

¹*Second Department of Internal Medicine, ²Department of Laboratory Medicine, and
³Department of Pathology, Nagasaki University School of Medicine, Nagasaki, Japan*

Corresponding author:

Koichi IZUMIKAWA, M.D., Ph.D.

Second Department of Internal Medicine, Nagasaki University School of Medicine

1-7-1 Sakamoto, Nagasaki 852-8501, JAPAN

Phone: +81-95-819-7276, Fax: +81-95-849-7285

E-mail: koizumik@nagasaki-u.ac.jp

Abstract

Cryptococcal pleuritis is rare in individuals with no underlying disease. We report a case of pulmonary cryptococcosis followed by pleuritis in a patient on fluconazole treatment. Biopsy of the pleura revealed a granuloma and a cryptococcal body, while PCR and sequence analysis of extracted DNA from the pleura proved the presence of *Cryptococcus* species, most likely *C. neoformans*. Voriconazole with flucytosine and drainage of the pleural effusion were effective in treating the patient.

Introduction

Cryptococcosis in humans is found worldwide. Cryptococcosis is rare in immunocompetent individuals and clinical manifestations of pulmonary infections are usually mild and asymptomatic [1]. Hence, cryptococcosis in immunocompromised hosts such as, human immunodeficiency virus (HIV) infected and acquired-immunodeficiency syndrome (AIDS) patients, becomes more severe and clinical manifestations become more diverse [2].

Pulmonary inhalation of *Cryptococcus neoformans* is generally regarded as the initiator for diseases in humans and pulmonary cryptococcosis may present a wide variety of findings in chest X-ray films such as nodules, masses, pneumonia, and miliary lesions, however pleural disease is not common [3]. Although the frequency of cryptococcal pleuritis has increased recently because of an increasing number of immunocompromised patients [4, 5], it is still rare among immunocompetent cryptococcosis patients.

We report here a rare case of pulmonary cryptococcosis followed by pleuritis in an apparently immunocompetent patient during fluconazole treatment as maintenance therapy.

Case report

A 24-year-old male patient who primarily lived in Nagasaki, Japan visited Nagasaki Municipal Hospital complaining of dry cough, right back pain and fever for 2 weeks. He possessed no previous underlying diseases and no history of smoking or oral steroid use. He had visited Venice, Italy three months prior to the onset of his symptoms, where he had experienced a heavy exposure to pigeons, but had no history of breeding the birds. Chest X-ray films revealed infiltrative shadows with cavitation in the right lower lung field (Figure 1). Since serum cryptococcal antigen level was high (X 1,024), he was diagnosed as having pulmonary cryptococcosis and was referred to Nagasaki University Hospital for further treatment.

On admission, vital signs of the patient were as follows: body temperature: 36.5 °C, heart rate: 76 beats/minute with a regular rhythm, respiratory rate: 14 breaths/minute and blood pressure: 111/65 mmHg. Physical examination revealed no rales or murmurs and no signs of systemic lymphadenopathy, hepatosplenomegaly, or pre-tibial edema. There were no abnormalities on neurological examination such as neck stiffness or disorientation. Laboratory findings on admission were: white blood cells count: $8.9 \times 10^3/\mu\text{L}$ with a shift to the left (neutrophils: 73 %), C-reactive protein (CRP): 1.99 mg/dL and erythrocyte sedimentation rate: 38 mm/h. Sputum microbiology testing

revealed no causative bacteria or *Cryptococcus* spp. Bronchoscopy and bronchial alveolar lavage (BAL) were performed. India ink staining of BAL fluid (BALF) revealed encapsulated yeast-like cells and a high titer of cryptococcal antigen (X 64). Lumbar puncture, performed to rule out cephalomeningitis, demonstrated a clear and colorless recall. India ink staining showed no causative agents and the titer of cryptococcal antigen was negative.

Since the patient's cough was persistent and severe, liposomal amphotericin B (L-AMB) was administered intravenously. Within ten days of L-AMB administration, the patient improved symptomatically with chest X-ray and CRP also showing improvement. Nausea and loss of appetite, however, occurred 8 days after initiation of treatment and serum potassium levels decreased to 3.1 mEq/ml, apparently as side effects of L-AMB. The decision was made to discontinue L-AMB and instead, 400 mg/day of fluconazole (FLC) orally was initiated. Six months administration of oral FLC on an outpatient basis was planned and the patient was discharged from the hospital.

Fourteen days after discharge, the patient was re-admitted to our hospital, again with the same symptoms of dry cough, back pain and fever. Chest X-ray films revealed a new right pleural effusion with original infiltrative shadow in the right lower lung field.

Physical examination and laboratory findings were almost identical to those of his previous admission. However, this time CRP level was elevated to 5.17 mg/dl. On admission, aspiration of the pleural effusion was performed. Aspirated fluid was slightly bloody in appearance with elevated levels of albumin (2.9 mg/dl) and lactate dehydrogenase (444 IU/dl), indicating that the effusion was exudative rather than transudative in nature, probably due to inflammation. Total cell counts of the fluid were 6.1×10^6 /ml, consisting of 13% eosinophilic cells, although there was no eosinophilia in the blood. Cryptococcal antigen level of the pleural effusion was also high (X 256). The results indicated that the effusion was a complication of deterioration of pulmonary cryptococcosis and hence, intravenous itraconazole (ITC) 200 mg/ day was initiated instead of the FLC that the patient was previously receiving.

However, 13 days after administration of ITC was commenced, CRP level was elevated to 9.41 mg/dl, fever persisted and the pleural effusion had increased (Figure 2). The second analysis of the aspirated fluid revealed that the effusion was exudative with no eosinophilic cells being present. No bacteria or *Cryptococcus* spp. were isolated on culture. L-AMB, 200mg/day, was once again administered instead of ITC, with no decrease in pleural effusion or fever. Seven days after administration of L-AMB, pleural biopsy under video-assisted thoracoscopy (VATS) was performed in order to examine

the etiology of the effusion. Pathological findings of pleura showed fibrin and foreign-body granuloma. Multiple yeast-like fungus bodies were observed in the inflammatory granuloma by periodic acid Schiff and Grocott staining (Figure 3). Drainage of the pleural effusion was performed and a combination of 400 mg/day voriconazole (VRC) and 6 g/day of flucytosine (5FC) orally was administered instead of L-AMB. Fever and cough gradually improved and CRP level also normalized within three weeks of commencing this combination therapy. Both the antifungal drugs were continued for five months after discharge with no clinical recurrence of the disease.

PCR analysis using extracted DNA from the pleura obtained under VATS was performed to identify the causative agent. Extraction of DNA from paraffin-embedded pleura was performed according to the method previously reported with minor modifications [6]. Briefly, five sections (thickness, 10 μ m) of specimen cut by a sterile microtome blade were used. To remove paraffin wax, xylene was added, mixed, incubated at room temperature for 10 min, and centrifuged (at 15,000 rpm for 5 min). The pellet was washed three times with ethanol, dried at room temperature and suspended in distilled water. Further extraction was performed by mechanical disruption by the glass bead technique as previously reported [7]. PCR was performed based on the protocol previously reported by Leaw *et al.* [8]. The universal fungal primers ITS1

(5'-TCCGTAGGTGAACCTGCGG-3') and ITS2 (5'-GCTGCGTTCTTCATCGATGC-3') were used to amplify the internal transcribed spacer 1 (ITS1) region and 52 bp from the 5' end of the 5.8S gene as well as about 30 bp from the 3' end of the 18S gene [9]. PCR was performed in a total reaction volume of 50 µl of premix Taq (Takara, Tokyo, Japan), with 0.4 µM each of primers ITS1 and ITS2, and DNA template. PCR was carried out using the following steps: initial denaturation at 94°C for 3 min, 30 cycles of denaturation (94°C for 1 min), annealing (60°C for 1 min), extension (72°C for 1 min) and a final extension step at 72°C for 3 min. In the PCR analysis, a 202-bp band was amplified from DNA extracted from pleura and gDNA extracted from the H99 *Cryptococcus neoformans* reference strain. The PCR product was then purified by PCR purification kit (Stratagene, La Jolla, CA) and cloned into the TA cloning vector by a TA cloning kit (Qbiogene, Irvine, CA). The cloned PCR product was sequenced with both M13 and Reverse sequencing primers twice and the acquired sequence chromatograms by ABI prism 310 Genetic analyzer (Applied Biosystems, Foster City, CA) were carefully assessed and corrected by investigators. The ITS1 region (121 bp) of cloned PCR product was compared to the NCBI nucleotide database using nucleotide-nucleotide BLAST with default setting, except that the sequences were not filtered for low complexity [10]. The BLAST search resulted in 100% match across all

121 bp to the ITS1 sequence of *C. neoformans* var. *neoformans* JEC 21 (Genbank accession number AY217025) (Figure 4). The sequence differed from that of *C. neoformans* var. *grubii* (H99 strain; Genbank accession number AY217027) by two nucleotides at the discriminatory positions 19 and 108 of the ITS1 region (Figure 4) [11]. The sequence also differed from that of *C. gattii* (formerly *C. neoformans* var. *gattii*; Genbank accession number EF081159) by four nucleotides at the discriminatory positions 11, 15, 19 and 108 of the ITS1 region (Figure 4) [11]. These results indicate that the pleuritis was caused by *Cryptococcus* species, most likely *C. neoformans*.

Discussion

Pleural diseases due to fungi are rare, with the reported frequency being about 1% of all pleural diseases [12]. Before the HIV/AIDS era, pleural effusions due to *C. neoformans* were extremely rare. However, recently, the frequency has reportedly increased to 5 to 25 % [4, 5]. More than half of the patients have moderate to severe underlying diseases such as AIDS, leukemia and lymphoma [13], cryptococcal pleuritis being uncommon in patients without underlying diseases. Our patient, however, was a 24 year-old previously healthy man with no known predisposing conditions.

Another uncommon occurrence in our patient was that the pleural effusion gradually increased during treatment with L-AMB as well as with FLC. It is very rare for pleural effusion to increase during treatment in immunocompetent hosts. Direct extension of the primary pulmonary cryptococcal nodule into the pleural space causes pleural cryptococcosis [14], with exudative effusions. Though laboratory findings demonstrated the exudative nature of the effusion in our case, eosinophils were elevated in the first aspirate. There are reports that eosinophils are increased in cryptococcal pleuritis [13, 15], although the mechanism is not quite understood. The diagnosis of cryptococcal pleuritis requires proof of the presence of *Cryptococcus* spp. in the effusion or on pleural culture.

Since all attempts to culture sputum, BALF and pleural effusion failed in our patient, we performed PCR to detect fungal DNA extracted from the pleura obtained by VATS. Identification of yeast species by sequence analysis of ITS regions was established by Leaw *et al.* [8] and we analyzed the total of 121 bp of ITS1 region. The result revealed that the presence of *Cryptococcus* spp. in the pleura of our patient. Since the ITS1 region is highly conserved among *Cryptococcus* spp., a complete identification of the causative organism was not possible. However the high level of nucleotide identity of the sequence to *C. neoformans* sequences, suggests that this species is most likely the cause of the pleuritis. Recently described molecular methods enable the identification of *Cryptococcus* species, varieties and/or serotypes, by sequencing the entire ITS1-5.8S-ITS2 region [11] , or multiplex PCR of the laccase and capsule genes [16]. However, our attempts to replicate these methodologies failed due to unknown reasons.

Although cryptococcal pleuritis sometimes resolves without medication especially in immunocompetent hosts [12], drainage and administration of VRC and 5FC were required in our patient. A total of five months treatment of VRC and 5FC was effective, with no recurrence being observed after discontinuation of drug therapy. As *Cryptococcus* was never isolated from sputum, BALF or pleural effusion, we were not able to perform drug susceptibility tests. It is possible that the strain that was

responsible for symptoms in our patient might have been resistant to older generations of azoles.

In conclusion, we experienced a rare case of cryptococcal pleuritis in an apparently immunocompetent host, who deteriorated during FLC treatment. Drainage of the pleural effusion and combination therapy of VRC and 5FC treatment were effective.

Conflict of interest

None.

Figure 1

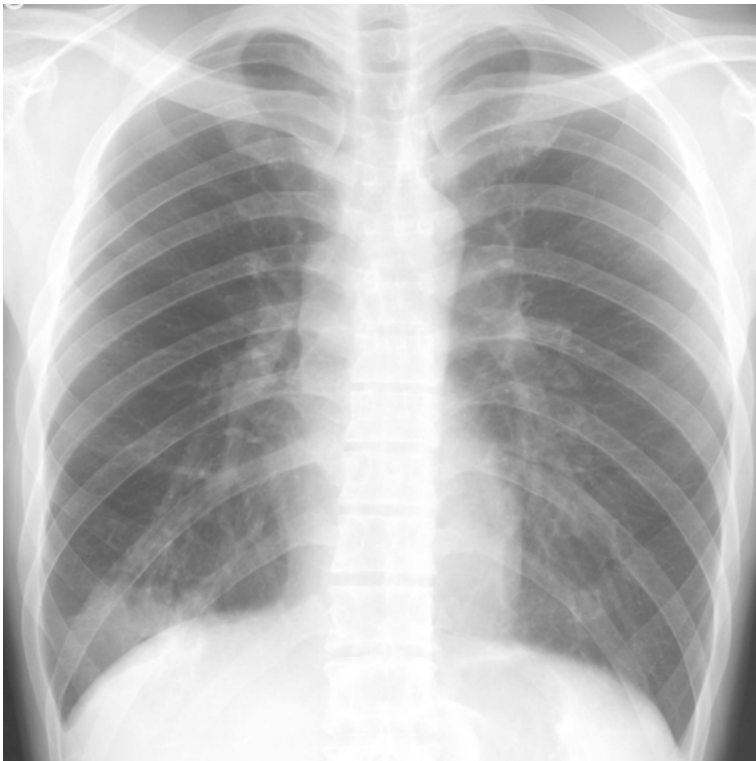

Figure 2

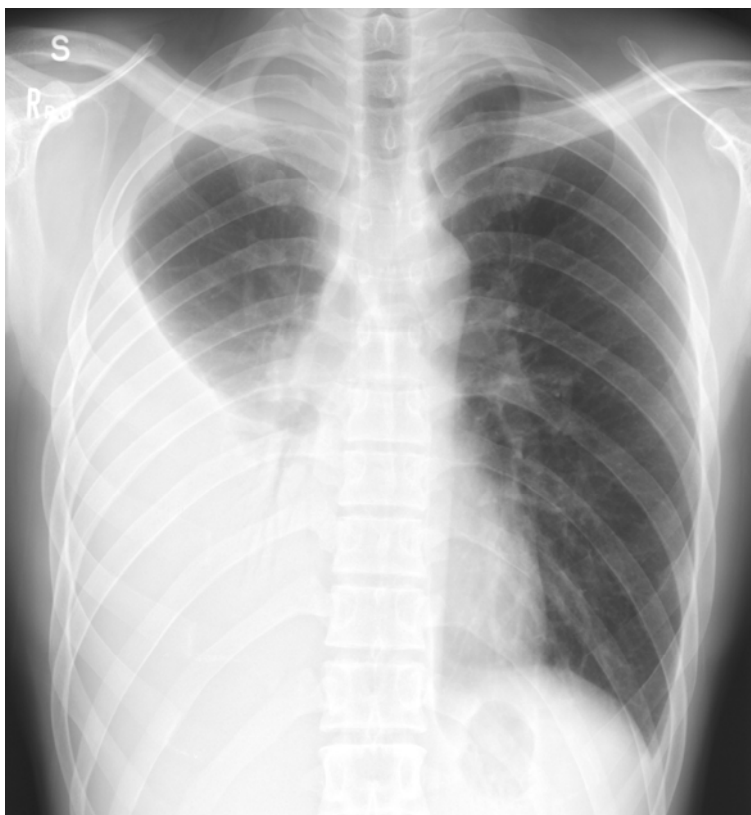


Figure 3

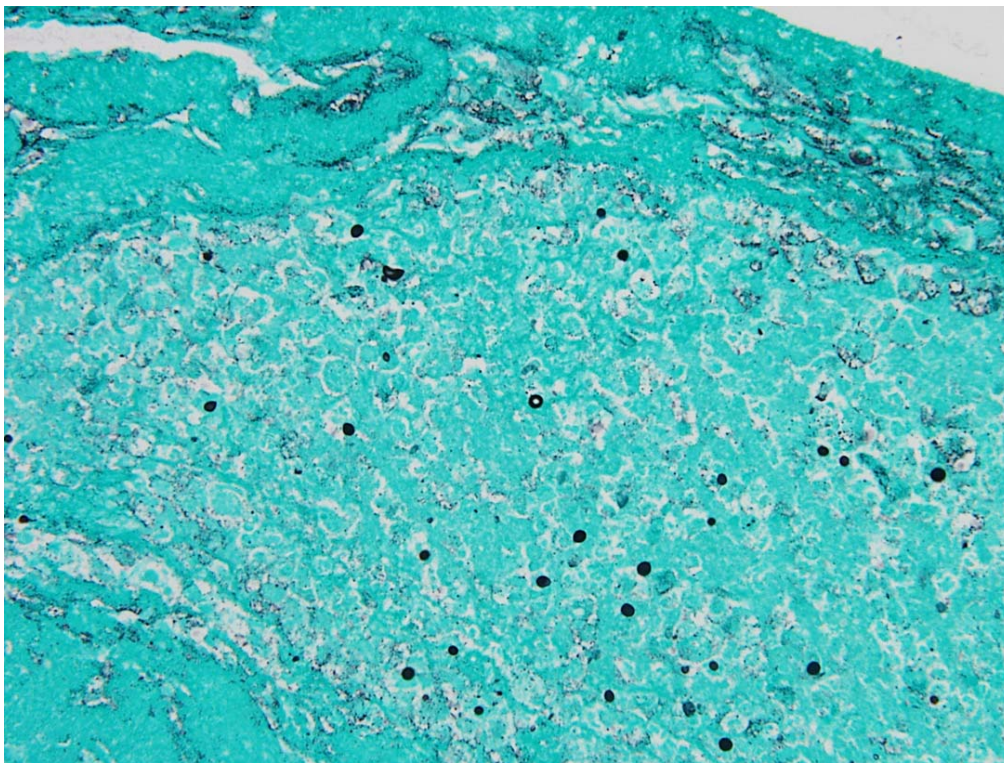


Figure 4

	10	20	30	40	50	60	
Sample	GTAGAGAATA	TTGGACTTTG	GTCCATTTAT	CTACCCATCT	ACACCTGTGA	ACTGTTTATG	
AY217025 (<i>var. neoformans</i>)	GTAGAGAATA	TTGGACTTTG	GTCCATTTAT	CTACCCATCT	ACACCTGTGA	ACTGTTTATG	
AY217027 (<i>var. grubii</i>)	GTAGAGAATA	TTGGACTTCG	GTCCATTTAT	CTACCCATCT	ACACCTGTGA	ACTGTTTATG	
EF081159 (<i>C. gatti</i>)	GTAGAGAATA	CTGGGCTTCG	GTCCATTTAT	CTACCCATCT	ACACCTGTGA	ACTGTTTATG	
		* * *					
	70	80	90	100	110	120	
Sample	TGCTTCGGCA	CGTTTTACAC	AAACTTCTAA	ATGTAATGAA	TGTAATCATA	TTATAACAAT	A
AY217025 (<i>var. neoformans</i>)	TGCTTCGGCA	CGTTTTACAC	AAACTTCTAA	ATGTAATGAA	TGTAATCATA	TTATAACAAT	A
AY217027 (<i>var. grubii</i>)	TGCTTCGGCA	CGTTTTACAC	AAACTTCTAA	ATGTAATGAA	TGTAATCTTA	TTATAACAAT	A
EF081159 (<i>C. gatti</i>)	TGCTTCGGCA	CGTTTTACAC	AAACTTCTAA	ATGTAATGAA	TGTAATCTTA	TTATAACAAT	A
					*		

Figure Legends

Figure 1: Chest X-ray film on first admission demonstrating infiltrative shadows with cavitation in the right lower lung field.

Figure 2: Chest X-ray film during second admission. Massive pleural effusion is indicated in the right thorax with infiltrates in the right lower lung field.

Figure 3: Pathological finding of the pleural tissue obtained by VATS. Typical yeast-form fungus bodies are seen. (Grocott stain, X400).

Figure 4: Alignment of ITS1 sequences of the sample from the patient, *C. neoformans* var. *neoformans* JEC 21 (Genbank accession number AY217025), *C. neoformans* var. *grubii* (H99 strain; Genbank accession number AY217027) and *C. gattii* (formerly *C. neoformans* var. *gattii*; Genbank accession number EF081159). The asterisks indicate the nucleotides difference in alignments of all sequences. The sequence of ITS1 of clinical sample was 100% match across all 121 bp to that of *C. neoformans* var. *neoformans* JEC 21 (Genbank accession number AY217025). The sequence differed from those of *C. neoformans* var. *grubii* (H99 strain; Accession number AY217027)

and *C. gattii* (formerly *C. neoformans* var. *gattii*; Accession number EF081159) by two (discriminatory positions 19 and 108 in the ITS1 region) and four (discriminatory positions 11, 15, 19 and 108 in the ITS1 region) nucleotides, respectively.

Reference

1. Kuykendall SJ, Ellis FH, Jr., Weed LA, Donoghue FE. Pulmonary cryptococcosis. *N Engl J Med* 1957; **257**: 1009-1016.
2. Sugar AM. Overview: cryptococcosis in the patient with AIDS. *Mycopathologia* 1991; **114**: 153-157.
3. Patz EF, Jr., Goodman PC. Pulmonary cryptococcosis. *J Thorac Imaging* 1992; **7**: 51-55.
4. Cadranet JL, Chouaid C, Denis M, *et al.* Causes of pleural effusion in 75 HIV-infected patients. *Chest* 1993; **104**: 655.
5. Chechani V, Kamholz SL. Pulmonary manifestations of disseminated cryptococcosis in patients with AIDS. *Chest* 1990; **98**: 1060-1066.
6. Goelz SE, Hamilton SR, Vogelstein B. Purification of DNA from formaldehyde fixed and paraffin embedded human tissue. *Biochem Biophys Res Commun* 1985; **130**: 118-126.
7. Tanaka K, Miyazaki T, Maesaki S, *et al.* Detection of *Cryptococcus neoformans* gene in patients with pulmonary cryptococcosis. *J Clin Microbiol* 1996; **34**: 2826-2828.

8. Leaw SN, Chang HC, Sun HF, *et al.* Identification of medically important yeast species by sequence analysis of the internal transcribed spacer regions. *J Clin Microbiol* 2006; **44**: 693-699.
9. White TJ, Bruns T, Lee S, Taylor J. Amplification and direct sequencing of fungal ribosomal RNA genes for phylogenetics. In: Innis MA, Gelfand DH, Sninsky JJ, White TJ (eds.). *PCR protocols: a guide to methods and applications*. San Diego: Academic Press, 1990: 315-322.
10. Altschul SF, Gish W, Miller W, *et al.* Basic local alignment search tool. *J Mol Biol* 1990; **215**: 403-410.
11. Katsu M, Kidd S, Ando A, *et al.* The internal transcribed spacers and 5.8S rRNA gene show extensive diversity among isolates of the *Cryptococcus neoformans* species complex. *FEMS Yeast Res* 2004; **4**: 377-388.
12. Light RW. Pleural effusion secondary to fungal infections, actinomycosis, and nocardiosis. In: Light RW (ed.). *Pleural Diseases*. 4th edn., Philadelphia: Lippincott Williams & Wilkins, 2001: 196-203.
13. Young EJ, Hirsh DD, Fainstein V, Williams TW. Pleural effusions due to *Cryptococcus neoformans*: a review of the literature and report of two cases with cryptococcal antigen determinations. *Am Rev Respir Dis* 1980; **121**: 743-747.

14. Salyer WR, Salyer DC. Pleural involvement in cryptococcosis. *Chest* 1974; **66**: 139-140.
15. Nei T, Enomoto T, Sakamoto T, *et al.* A case of secondary pulmonary cryptococcosis with pleural effusion involving type 1 allergy. *Nihon Kokyuki Gakkai Zasshi* 2007; **45**: 551-555.
16. Ito-Kuwa S, Nakamura K, Aoki S, Vidotto V. Serotype identification of *Cryptococcus neoformans* by multiplex PCR. *Mycoses* 2007; **50**: 277-281.