

Surgical techniques

Vascular transection using endovascular stapling in hepatic resection

Atsushi Nanashima, MD, Yori-hisa Sumida, MD, Masahiro Oikawa, MD,

Goshi Murakami, MD, Takafumi Abo, MD, Shigekazu Hidaka, MD,

Hiroaki Takeshita, MD, Terumitsu Sawai, MD, Takeshi Nagayasu, MD

Division of Surgical Oncology, Department of Translational Medical Sciences,
Nagasaki University Graduate School of Biomedical Sciences, 1-7-1 Sakamoto,
Nagasaki 852-8501, Japan

Correspondence and reprint requests to: Atsushi Nanashima, M.D.

Division of Surgical Oncology, Department of Translational Medical Sciences,
Nagasaki University Graduate School of Biomedical Sciences,

1-7-1 Sakamoto, Nagasaki 852-8501, JAPAN

Tel.: +81-95-819-7304, Fax: +81-95-819-7306

E-mail: a-nanasm@net.nagasaki-u.ac.jp

ABSTRACT

Background/Aims: In anatomical resection of the liver, transection of the hepatic vein or Glisson's pedicle is necessary. We examined the surgical records and outcome of 25 patients who underwent hepatectomy.

Methodology: An endovascular stapler with 35 and 60 mm staples was used for transection of the hepatic vein or Glisson's pedicle, and hepatic parenchyma including vessels.

Results: Surgery included also left lateral sectoriectomy in 6 patients, right lateral sectoriectomy in one, right hepatectomy in 12, left hepatectomy in two and trisegmentectomy in 4. Endovascular stapling was used for transection of hepatic veins (n=25) in all patients and Glisson's pedicle (n=8). No failure of firing occurred during cutting. Injury of an aberrant bile duct occurred in one patient, but none suffered bleeding or bile leakage from the transected parts.

Conclusions: Vascular transection using vascular stapler could be performed safely and rapidly during anatomical hepatic resection.

Keywords: Hepatectomy; Vascular stapler; Hepatic vein, Glisson's pedicle; Biliary injury

INTRODUCTION

Endovascular stapling is used for vascular division based on its safety, ease of use and shortening of the operating time. Radical operation for hepatobiliary malignancies provides better patient survival (1). Therefore, systematic or anatomic resection, at the base of Glisson's pedicle and hepatic veins in the region occupied by the tumor, has been proposed to ensure radical excision of the tumor. To accomplish anatomic resection, division of these hepatic vessels is necessary. Furthermore, left lateral sectoriectomy can be performed under laparoscopy at present, and stapling can be used for hepatic transection including vessels (2). We have employed endovascular stapling in recent years and here we report our experience using this technique in hepatic resection.

METODOLOGY

Patients

We analyzed the data of 25 patients with hepatobiliary malignancies who underwent hepatic resection between 2006 and June of 2007. Informed consent for use of stapler and data collection was obtained from each patient.

Operative procedure

In this procedure, the hepatoduodenal ligament was routinely clamped for complete occlusion of the vascular inflow to the liver during transection (Pringle's maneuver), followed by application of the forceps fracture method and ultrasonic dissector (USU MH-207, Olympus, Tokyo, Japan) for the transection of liver parenchyma. The liver

hanging maneuver was used whenever possible for parenchymal transection in major hepatectomy (3).

In the present series, we used Endopath-Endocutter ETS-Frex 35 (staple load; 3.0 mm x 35 mm, white cartilage, Ethicon Endo-Surgery, Johnson & Johnson, Somerville, NJ) for dividing the isolated hepatic vein or Glisson's pedicle (**Figure 1**). Vascular cutting could be employed even in a limited space since part of the staple load is malleable and can be bent (articulate shaft) (**Figure 2**). After firing, 6 parallel rows were ligated by titanium staples (3.0 x 1.0 mm) while 3 rows remained in the body (**Figure 3**). The cartridge could be exchanged.

The hepatic parenchyma, including intrahepatic Glisson's pedicle and hepatic vein, was transected by the vascular stapler in a case of left lateral sectoriectomy using Echelon™ 60 Endopath® Stapler (staple load; 5.4 mm x 60 mm, gold cartilage, Ethicon Endo-Surgery). Before firing, 1 cm depth from the liver surface was cut using an ultrasonic cutting and coagulating surgical device, Harmonic Scalpel® LCS Slim with 15 mm blade and 35 cm shaft (Ethicon Endo-Surgery) adjacent to the transected plane (**Figure 4**). The remnant liver parenchyma was carefully held by the stapler and then transected by three-step firing (**Figure 5**). The cartridge was compressible to 1.8 mm. After firing, 6 rows were ligated by titanium staples (3.0 x 1.8 mm) and 3 rows remained in the body.

RESULTS

The mean age of patients was 68.5 ± 13.1 years (\pm SD, range, 55-87 years). The above procedure was performed in 9 patients with hepatocellular carcinomas, 7 with

cholangiocarcinomas, 2 with metastatic liver carcinomas, and 6 with bile duct carcinomas, in addition to one patient with gall bladder carcinoma. Background liver disease included normal liver in 11 patients, chronic viral hepatitis in 8 and obstructive jaundice in 6. Operative procedures included left lateral sectoriectomy in 6 patients, right lateral sectoriectomy in one, right hemi-hepatectomy in 12, left hemi-hepatectomy in two, right trisegmentectomy in two, and left trisegmentectomy in two. Laparoscopy assisted left lateral sectoriectomy was performed in 4 patients. The liver hanging maneuver was applied for hemihepatectomy in 7 patients.

The hepatic veins were cut in all patients, including the right hepatic vein in 10, inferior right hepatic vein in 7, confluence of middle and left veins in 3, and left hepatic vein in 5. Glisson's pedicles were cut in 8 including 6 Glisson's branches in left lateral sector, one left hepatic Glisson's pedicle, and one right lateral Glisson's pedicle. Although inter-locking before firing of the stapler was observed in one case, no failure of firing was observed during stapler cutting. Injury of the aberrant bile duct toward the right paramedian sector was observed in one patient when the right lateral Glisson's pedicle was divided. The injured bile duct ran from the bile duct of right lateral sector.

No bleeding and no bile leakage were noted from the transected parts during and after operation. Two patients developed intra-abdominal infection, however, this complication did not involve the stapling parts. There were no other serious complications after operation. Post-operative death during hospital stay was not observed in our series.

DISCUSSION

In recent years, the pulmonary artery or veins and bronchus are usually cut by vascular staplers during thoracic surgery (4). Complications after suturing are rare. In the field of liver surgery, vascular stapling has also been used for transection of the hepatic veins or Glisson's pedicles and the usefulness of this device has been reported already (5). Vascular stapling has been used also in liver transplantation as well (6). Our results indicate that this technique is easy to use and safe especially when miss-firing does not occur. Stapling may reduce operating time, particularly in laparoscopic hepatectomy (2). In case of transection of Glisson's pedicle, it is necessary to check for any anomaly of the bile duct by intraoperative cholangiography before cutting, to avoid iatrogenic injury.

REFERENCES

- (1) **Hasegawa K, Kokudo N, Imamura H, Matsuyama Y, Aoki T, Minagawa M, Sano K, Sugawara Y, Takayama T, Makuuchi M:** Prognostic impact of anatomic resection for hepatocellular carcinoma. *Ann Surg* 2005;242:252-259.
- (2) **Dagher I, Proske JM, Carloni A, Richa H, Tranchart H, Franco D:** Laparoscopic liver resection: results for 70 patients. *Surg Endosc.* 2007;21:619-624.
- (3) **Belghiti J, Guevara OA, Noun R, Saldinger PF, Kianmanesh R:** Liver hanging maneuver: a safe approach to right hepatectomy without liver mobilization. *J Am Coll Surg.* 2001;193:109-111.

- (4) **Szwerc MF, Landreneau RJ, Santos RS, Keenan RJ, Murray GF:**
Minithoracotomy combined with mechanically stapled bronchial and vascular ligation for anatomical lung resection. *Ann Thorac Surg.* 2004;77:1904-1910.
- (5) **Yanaga K, Nishizaki T, Yamamoto K, Taketomi A, Matsumata T, Takenaka K, Sugimachi K:** Simplified inflow control using stapling devices for major hepatic resection. *Arch Surg.* 1996;131:104-106.
- (6) **Eguchi S, Kawashita Y, Takatsuki M, Kanematsu T:** Application of endovascular stapler in living-donor liver transplantation. *Am J Surg.* 2007;193:258-259.

FIGURE LEGENDS

Figure 1. The right hepatic vein was isolated and held by the endovascular stapler before parenchymal resection.

Figure 2. The right hepatic vein was ligated by endovascular stapling after parenchymal resection was performed by the Hanging maneuver. Tumor involved vena cava and the space between the vena cava and right hepatic vein was narrow. Placement of stapler into this space was possible.

Figure 3. The 3 and 3 parallel row staples were sutured on the vena cava followed by resection of the tumor.

Figure 4. The hepatic parenchyma, including intrahepatic vessels, was ligated by using 60 mm staples.

Figure 5. The transected plane showed complete suturing of the staple line and vessels without any bleeding or bile leakage.

Fig1



Fig2

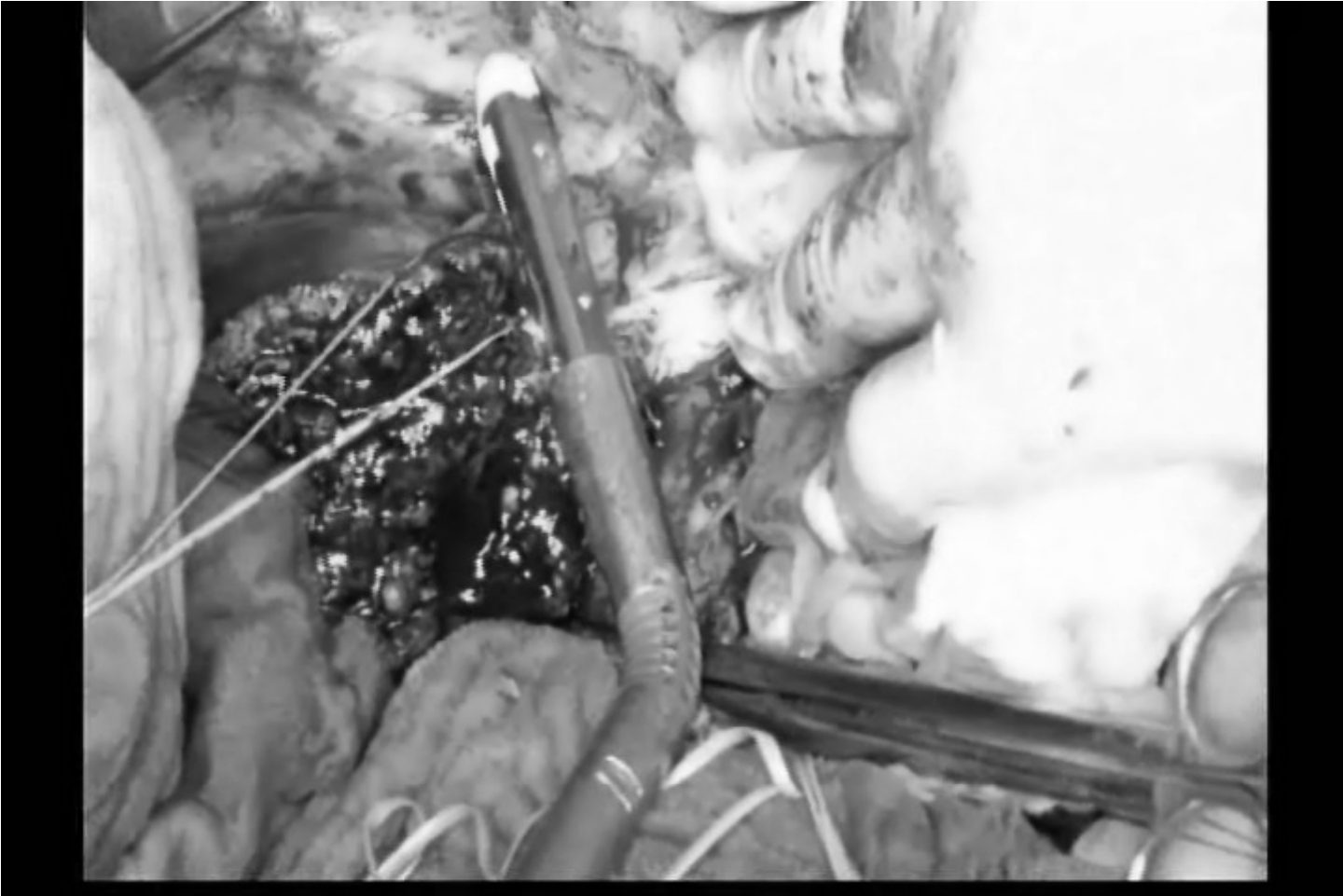

Fig3

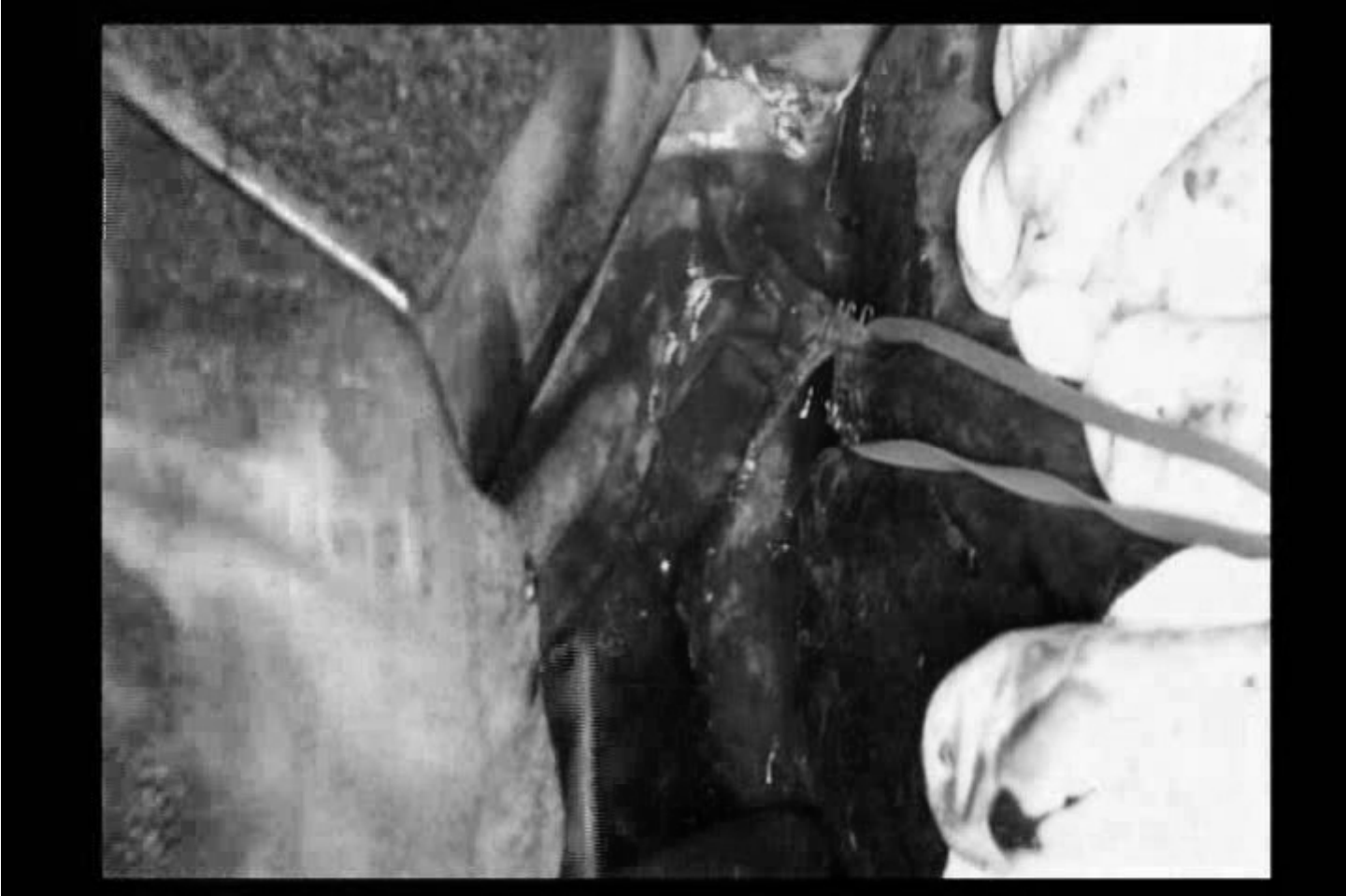

Fig4

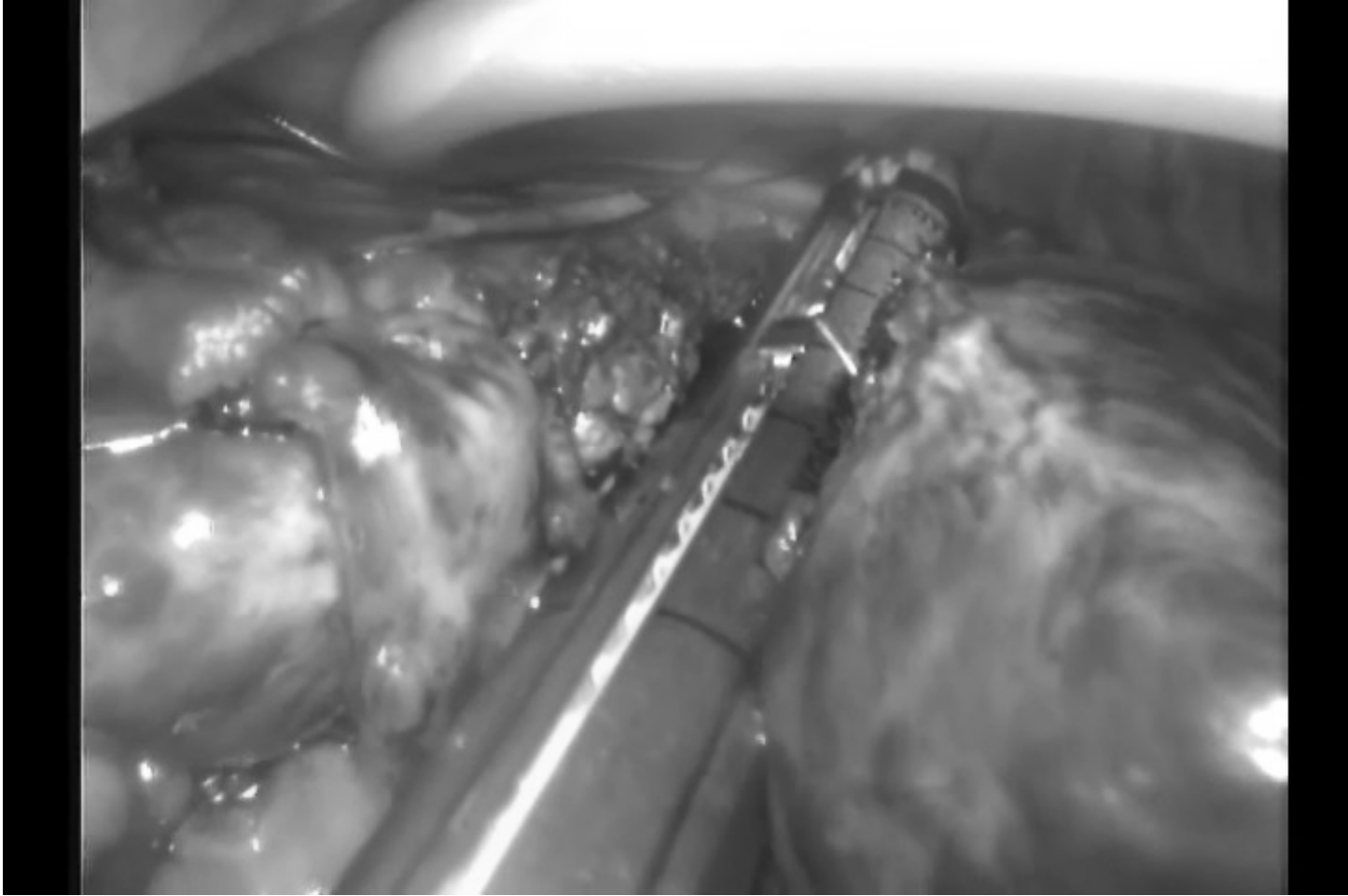


Fig5

