

PED-00163-2005.R2

Title page

A case of probable Noonan syndrome boy without PTPN11 mutation, manifesting unusual complications

Muneichiro Sumi, MD.¹, Yasuharu Ohno, MD,PhD.², Rie Sasaki, MD, PhD.³,

Tatsuro Kondoh, MD,PhD.¹, Masato Tagawa, MD.¹, Hideaki Masuzaki, MD, PhD.⁴,

Hiroyuki Moriuchi, MD, PhD.¹

¹ Department of Pediatrics, Nagasaki University School of Medicine, Nagasaki, Japan

² Department of Surgery II, Nagasaki University School of Medicine, Nagasaki, Japan

³ Department of Endocrinology and Metabolism, National Research Institute for Child Health and Development, Tokyo, Japan

⁴ Department of Obstetrics and Gynecology, Nagasaki University School of Medicine, Nagasaki, Japan

Corresponding to; Muneichiro Sumi MD.

Department of Pediatrics, National Hospital Organization Nagasaki Medical Center,
2-1101-1 Kubara, Ohmura, Nagasaki 856-8562, Japan.

Tel: +81-957-52-3121 Fax: +81-957-54-0292 e-mail:msumi@nmc.hosp.go.jp

Introduction

Noonan syndrome (NS) (MIM No.163950) is an autosomal dominant disorder characterized by short stature, cardiovascular defects, and dysmorphic features, including hypertelorism, a webbed neck, a pectus excavatum and a chest wall deformity. Mental retardation and hearing difficulty are often observed in affected individuals.

Approximately 40% of NS patients have Protein-Tyrosine Phosphatase, Nonreceptor type 11 (*PTPN11*) mutations.¹ The genotypic-phenotypic correlation and phenotypic heterogeneity between the two genotypes have been reported.¹ Pulmonary valve stenosis is more frequent in *PTPN11* mutation-positive patients than mutation-negative patients,¹ whereas hypertrophic cardiomyopathy is more frequent in *PTPN11* mutation-negative patients than mutation-positive patients. Gastrointestinal complications are very few among NS patients. Double outlet right ventricle (DORV) and congenital rectal atresia have never been associated with the *PTPN11* mutation –negative NS patients.

We here report a Japanese boy with DORV and rectal atresia. He fulfilled clinical criteria for NS and had no *PTPN11* gene mutation.

Case presentation

The patient, a newborn Japanese boy, is the first child of non-consanguineous parents.

There are no other patients with mental retardation or dysmorphological problems in his family. Both parents were 33 years old, when the boy was born. The mother was primipara. Ultrasound examination of the fetus revealed intrauterine growth retardation, distended digestive tract, cardiac dilatation and pericardial effusion at 33 weeks of his gestational age. The mother underwent emergent caesarian section at 34 gestational weeks due to non re-assuring fetal states.

Apgar scores were 7 and 9 at 1 and 5 minutes after birth, respectively. His birth weight was 1,806 g (below the 10th percentile), length 40.5 cm (below the 10th percentile), and occipitofrontal head circumference 29.0 cm (the 10-50th percentile). Physical examinations revealed broad forehead, downward eye slants, epicanthal folds, ptosis, low set posterior rotated ears, cleft velum, small jaw, a short neck without webbing of skin, pectus carinatus, distended abdomen, small anal dimple with sphincter ani and bilateral hydrocele. He had no bleeding diathesis, choanal atresia and coloboma.

His complete blood cell counts and biochemical tests showed as follows: WBC $14.2 \times 10^3/\text{ul}$ (normal range; 5.0-19.0) with Ba 1 Eo 2 St 2 Seg 57 Ly 32 and Mo 6, erythroblasts 10/100wbc, RBC $4.63 \times 10^6/\text{ul}$ (4.77-5.93), hemoglobin 14.2g/dl (14-22),

hematocrit 53.1% (53.5-62.3), platelets $239 \times 10^3/\text{ul}$ (80-356), Na 140 mEq/l (133-146), K 6.5 mEq/l (4.6-6.7), Cl 100 mEq/l (100-117), Ca 10.6 mg/dl (6.1-11.6) , inorganic phosphate 5.2 mg/dl (5.4-10.9), BUN 8 mg/dl (3.1-25.5), CRP 0.04mg/dl (<0.30), total bilirubin 0.3mg/dl (3.8-17.7), AST 59 IU/l (11-59), ALT 23 IU/l (4-21), LDH 384 IU/l (364-1120), and γ -glutamyl transpeptidase 152 IU/l (1-45).

Chest X-ray showed widening of cardiac shadow and normal pulmonary blood flow. Plain abdominal X-ray showed small amount of digestive tract air with no gases in the pelvic region (Fig.1). Echocardiography found DORV with patent ductus arteriosus (PDA). Ultrasound examination of the abdomen revealed enlarged colon with massive calcificated debris. His abdominal distention was so severe, as to require emergent colostomy on day 0, and further investigation for his large intestinal obstruction was performed thereafter. Barium contrast fluoroscopy found interruption of his rectum (Fig.2) and abdominal magnetic resonance imaging (MRI) revealed no tumors or masses around the rectum (Fig.3), indicating simple congenital rectal atresia.

He is now 18 months of age. His body weight is 5,320 g (below the 3rd percentile), length 63.6 cm (below the 3rd percentile), and occipitofrontal head circumference 42.0 cm (below the 3rd percentile). He has no hematological problems. He cannot sit without support, nor speak at all. His present developmental quotient is around 40.

As he had typical facial anomalies, cardiac defects, short stature, pectus carinatus and mental retardation, he was diagnosed as NS from the clinical criteria by van der Burgt et al.²

Since DORV and rectal atresia were quite unusual complications of NS, molecular analysis of *PTPN11* gene was performed with an informed consent from his parents.

The leukocyte genomic DNA of the patient was amplified by PCR for all 15 exons and flanking introns of the *PTPN11* gene. Subsequently, the PCR products were subjected to direct sequencing from both directions on a CEQ 8000 autosequencer (Beckman Coulter, Fullerton, CA; www.beckman.com). The primer sequences and the PCR condition were previously described by Yoshida et al.³

Direct sequencing results revealed no mutations in all 15 exons or intronic regions adjacent to splicing junctions. Therefore, he was classified into the *PTPN11* mutation-negative NS patient.

Discussion

In this report, we presented a Japanese boy who was diagnosed as NS based on the clinical criteria by van der Burgt et al.², however, he was unique in that he was also complicated with DORV and rectal atresia.

PTPN11, which encodes the non-receptor type protein tyrosine phosphatase SHP-2 (src homology region 2-domain phosphatase-2), was identified as NS1 disease gene.¹ Epidermal growth factor (EGF) signaling is important for semilunar valve development and SHP-2 is a component of the EGF-mediated signal transduction pathway.⁴ A *ptpn11* knockout allele in heterozygosity results in a higher prevalence and increased severity of thickened aortic and pulmonary valve leaflets.¹

According to the previous reports of Japanese NS patients, pulmonary valvular stenosis (PS) and atrial septum defect (ASD) were frequently, and hematological abnormalities were exclusively present in mutation-positive patients.^{3,5,6} Since our patient was not complicated with PS or ASD and had no hematological abnormality, his clinical features were not incompatible of PTPN11 mutation-negative NS. Curiously, however, his cardiac defect was DORV, not hypertrophic cardiomyopathy that has been frequently associated with PTPN11 mutation-negative NS. Recently, cardiac genes for human conotruncal heart malformations, the *EGF-CFC* (Cripto, Frll, and Cryptic) gene family

and TBX (T-BOX1) gene, have been identified. *Cfcl* is one of the four known EGF-CFC family members and this CFC1 gene is located on chromosome 2.

Goldmuntz et al. identified *CFCL* mutations in 2 DORV patients among 86 sporadic patients without heterotaxy.⁷ TBX1 gene was mapped to the center of DiGeorge syndrome-responsible area (del22q11.2) and the mutation of this gene is attributed to major phenotypes of DiGeorge syndrome.⁸ Although he had DORV and cleft velum, as seen in DiGeorge syndrome, he did not have other features of conotruncal face syndrome such as ocular hypertelorism, low nasal bridge and hypocalcemia. Therefore, although we could not perform fluorescence in situ hybridization for a region of 22q11.2, DiGeorge syndrome would not be unlikely for our case.

Congenital rectal atresia is a rare malformation manifested as a part of dysmorphic syndromes,⁹ such as CHARGE syndrome, Ehlers-Danlos syndrome type IV¹⁰ and EEC (ectodactyly-ectodermal dysplasia-clefting) syndrome.¹¹ Since Harris et al.¹² concluded that CHARGE syndrome should be restricted to infants with multiple malformation and choanal atresia and/or coloboma combined with other cardinal malformation (heart, ear, and genital) and with a total of at least three cardinal malformation, our patient who did not have choanal atresia and coloboma could not be regarded as CHARGE syndrome.

Ehlers-Danlos syndrome and EEC syndrome are not likely diagnosis, either.

Our patients fulfilled clinical criteria for NS but had rare complications such as DORV and congenital rectal atresia. Very few malformation syndrome manifest both of the above two conditions, however, none of them is consistent with our patient.

Furthermore, DORV and rectal atresia has never been associated with each other from molecular and cytogenetic aspects. Accumulation and investigation of similar cases from clinical, molecular and cytogenetic aspects will be needed for better understanding of possible association of NS-like phenotypes with DORV and rectal atresia.

References

1. Tartaglia M, Kalidas L, Shaw A, et al. *PTPN11* mutations in Noonan syndrome: Molecular spectrum, Genotype-phenotype correlation, and phenotypic heterogeneity. *Am J Hum Genet* 2002; 70:1555-1563
2. van der Burgt I, Berends E, Lommen E, van Beersum S, Hamel B, Mariman E. Clinical and molecular studies in a large Dutch family with Noonan syndrome. *Am J Med Genet* 1994; 53:187-191
3. Yoshida R, Hasegawa T, Hasegawa Y, et al. Protein-tyrosine phosphatase, nonreceptor type 11 mutation analysis and clinical assessment in 45 patients with Noonan syndrome. *J Clin Endocrinol Metab* 2004; 89:3359-3364
4. Qu C-K, Yu W-M, Azzarelli B, et al. Genetic evidence that Shp-2 tyrosine phosphatase is a signal enhancer of the epidermal growth factor receptor in mammals. *Proc Natl Acad Sci USA* 1999; 96:8528-8533
5. Kosaki K, Suzuki T, Muroya K, et al. *PTPN11* (Protein-tyrosine phosphatase, nonreceptor type 11) mutations in seven Japanese patients with Noonan syndrome. *J Clin Endocrinol Metab* 2002; 87:3529-3533
6. Niihori T, Aoki Y, Ohashi H, et al. Function analysis of PTPN11/SHP-2 identified in Noonan syndrome and childhood leukemia. *J Hum Genet* 2005;50:192-202

7. Goldmuntz E, Bamford R, Karkera JD, et al. CFC1 mutation in patients with Transposition of the Great Arteries and Double-Outlet Right Ventricle. *Am J Hum Genet* 2002; 70:776-780
8. Chieffo C, Garvey N, Gong W, et al. Isolation and characterization of gene from DiGeorge chromosomal region homologous to the mouse Tbx1 gene. *Genomics* 1997; 43:267-277
9. Endo A, Hayashi A, Ishihara I, et al. Analysis of 1,992 patients with anorectal malformations over the past to decades in Japan. *J Pediatr Surg* 1999; 34: 435-441
10. Fuchs JR, Fishman SJ. Management of spontaneous colonic perforation in Ehlers-Danlos syndrome Type IV. *J Pediatr Surg* 2004; 39 (Suppl 3):E13
11. Mjewski F, Goecke T. Rectal atresia as rare manifestation in ECC syndrome. *Am J Med Genet* 1996; 63:190-192
12. Harris J, Robert E, Kallen B. Epidemiology of choanal atresia with special reference to the CHARGE association. *Pediatrics* 1997; 99:363-367

Figure legends

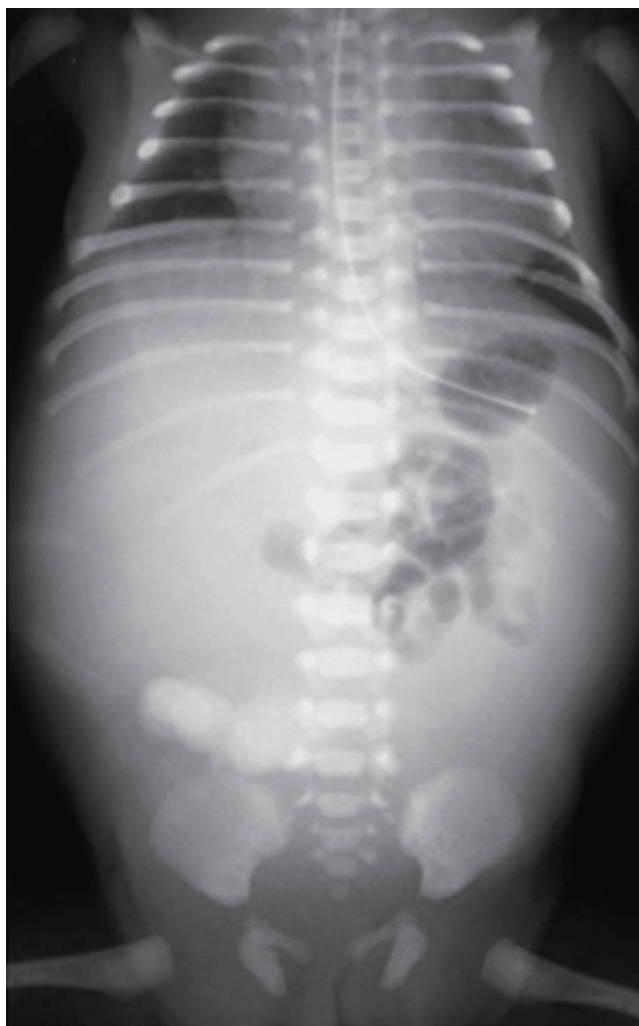


Fig.1 Plain X-lay of the chest and the abdomen, showing widening of cardiac shadow with normal pulmonary blood flow, and small amount of digestive tract air with no gass in the pelvic region.

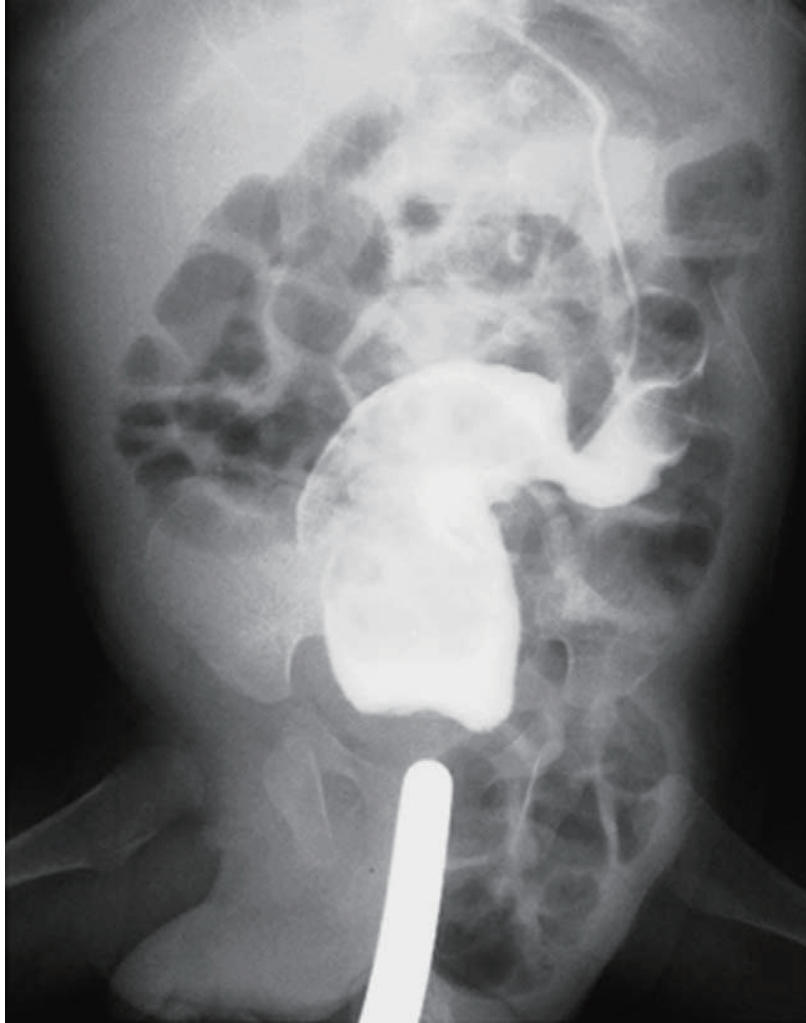

Fig.2 Barium contrast fluoroscopy examination revealing thick septum of the middle rectum (white arrow).

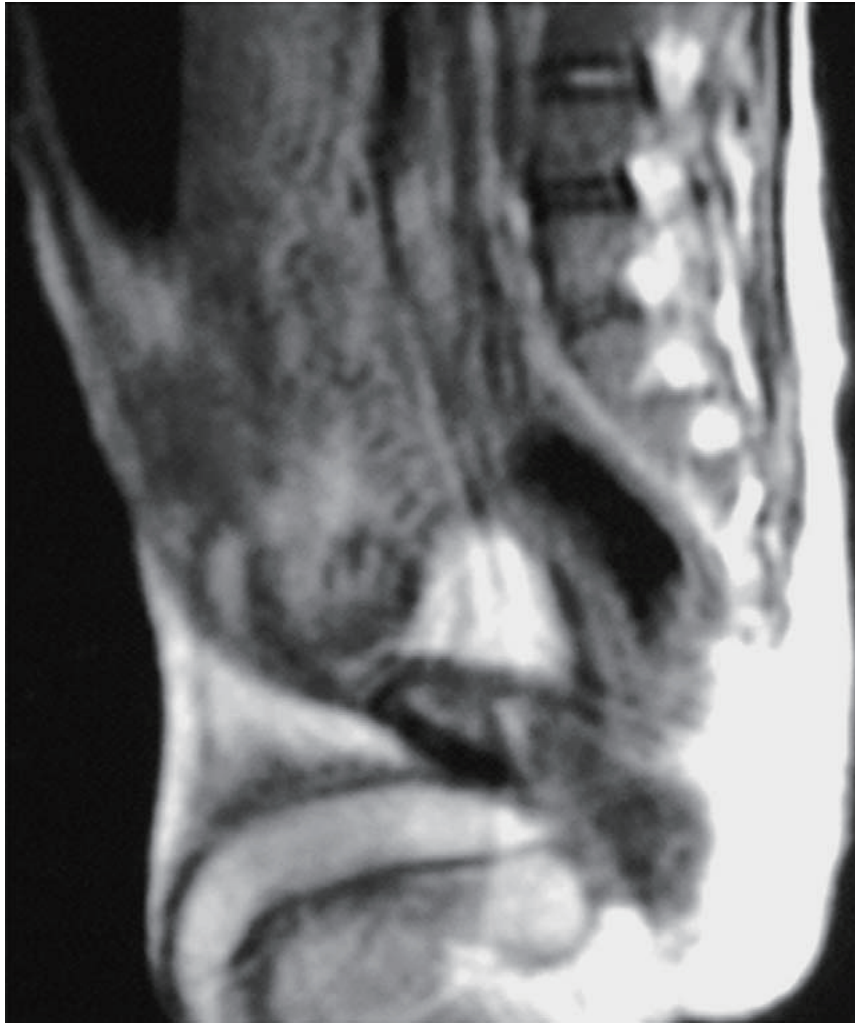

Fig.3 MRI showing neither masses nor tumors around anorectal region. There were no abnormal findings in the sacrococcygeal region.