

Original Paper:

Two-Staged Living Donor Liver Transplantation for Fulminant Hepatic Failure

Running title: Two-staged living donor liver transplantation

Katsuhiko Yanaga MD, FACS^{1,2} *Susumu Eguchi MD, FACS*^{1,3} *Mitsuhisa Takatsuki MD*¹ *Sadayuki Okudaira MD*¹ *Yoshitsugu Tajima MD, FACS*¹, *Takashi Kanematsu MD, FACS*¹

From ¹the Department of Surgery, Nagasaki University Graduate School of Medical Sciences, Nagasaki, JAPAN

²the Department of Surgery, Jikei University School of Medicine, Tokyo, JAPAN

³ co-first-authors: Katsuhiko Yanaga and Susumu Eguchi

Key words: two-staged, liver transplantation, living-related, hepatectomy

Address correspondence and proofs to:

Susumu EGUCHI, MD, FACS

Department of Surgery

Nagasaki University Graduate School of Medical Sciences

Nagasaki, 852-8501, JAPAN

Phone: 81-95-819-7316, FAX: 81-95-819-7319

E-mail: sueguchi@nagasaki-u.ac.jp

Abbreviations

FHF = fulminant hepatic failure

LDLT = living donor liver transplantation

CHDF = continuous hemodiafiltration

Abstract

We report a first successful and life-saving two-staged living-related liver transplantation for a patient with imminent brain death due to fulminant hepatic failure that otherwise had to be performed after a pre-treated and scheduled blood-type incompatible liver transplantation. The patient was anhepatic for 6 hr 34 min, and continuous hemodiafiltration was given throughout the operation. The patient woke up quickly and was extubated within 24 hr after transplant. This two-staged procedure is useful for emergency living-related liver transplantation that needs to be performed when the operating room is busy with other emergency or scheduled surgical procedures, and may allow clearance of toxic metabolites during the anhepatic period.

INTRODUCTION

For fulminant hepatic failure (FHF), liver transplantation is an established and effective therapy (1). Nevertheless, the therapeutic window is narrow, and the procedure needs to be performed as an emergency operation. If the allograft is to be obtained from a live donor, two emergency operations need to be performed simultaneously and in a coordinated fashion at a single institution (2). Such a circumstance is demanding not only for the surgeons but also for the anesthesiologists, operating room personnel and facility as well as for the blood bank. We were confronted with an instance in which we had to perform two living-related liver transplants at the same time, i.e., an emergency living donor liver transplantation (LDLT) for a patient with imminent brain-death due to FHF and a scheduled blood-type incompatible LDLT after full preparatory treatment with repeated plasma exchange to reduce serum isoagglutinin titer. We report our experience with a two-staged LDLT, i.e., total hepatectomy and temporary portocaval shunting which was followed by allograft implantation to prevent brain stem herniation for a patient with FHF in such a difficult situation.

CASE REPORT

A 34-year-old woman suffered from fulminant hepatic failure due to

hepatitis B and was transferred to our hospital on May 7, 2001. In spite of plasma exchange and continuous hemodiafiltration (CHDF), she developed grade IV coma (responsive only to painful stimuli) with the prothrombin time below 12% and serum ammonia of 176 microgm/ml. She was judged to require emergency liver transplantation in the evening of May 10, 2001, when her father, 67-years-old and blood type identical, volunteered to be a donor. His preoperative work-up and informed consent was completed by the end of the same day.

In the mean time, an 11 month-old-girl with biliary atresia, status-post Kasai's operation was scheduled and being prepared for blood-type incompatible (A to O) LDLT from her mother the next morning. She had undergone two courses of preoperative plasma exchange under general anesthesia to reduce the serum anti-A isoagglutinin titer. The family of the infant was extremely reluctant to postpone their transplant and became nervous about any negative influence on their transplant from the emergency liver transplantation for FHF. We therefore considered performing emergency LDLT immediately after the elective LDLT. Nevertheless, the woman with FHF started to exhibit decerebrate posture in spite of CHDF and plasma exchange, and computed tomography revealed brain edema, which suggested imminent brain death. We were confronted with the need to perform two LDLT at the same time.

For this difficult clinical situation, we decided to perform after donor

operation for the blood-type incompatible transplant a total hepatectomy and end-to-side portocaval shunting for the patient with FHF, and then to implant the allograft after the first elective blood-type incompatible LRLT was finished (Fig. 1). This modification would prevent the development of brain stem herniation or hemodynamic instability, while allowing the already set LDLT as scheduled.

After the native total hepatectomy with preservation of the inferior vena cava, the patient was anhepatic for 6 hr 34 min, during which she was placed on an end-to-side portocaval shunt. The shunt flow was 462ml/min by Doppler ultrasound, and splanchnic decompression was adequate with no signs of mesenteric petechiae or intestinal edema. CHDF was given throughout the operation, and her blood ammonia and lactate levels were lowered even during the anhepatic period (Fig. 1). The donor right lobe weighed 750gm, with the graft weight/estimated liver volume of 66.3%. The explant liver weighed 520gm and exhibited massive necrosis. The operation for the recipient took 19hr 8min, and the estimated blood loss was 2,300gm.

For postoperative immunosuppression, tacrolimus and steroids were given. The patient's postoperative course was uneventful, and she woke up on the first postoperative day, when she was extubated. She recovered without neurological deficits and was transferred to the medical service on postoperative day 30 with normal liver function and stable blood tacrolimus

level. At 12 months post-transplant, she is on tacrolimus 1mg b.i.d. only and remains well with normal liver function and without any restriction as a housewife. The child who received a blood-type incompatible liver from her mother was discharged 39 days after transplant and remains well with normal liver function without immunosuppression.

DISCUSSION

Keeping a patient with FHF alive and as a liver transplant candidate can be a challenging problem because of the narrow therapeutic window. The concept of two-staged liver transplantation was first reported as a desperate attempt by Ringe et al. (3) in 1988 for patients with primary graft non-function of the liver allograft or for intractable hemorrhage during hepatic resection. They later added severe hepatic trauma and FHF as indications for such a procedure (2,3). The rationale for such a procedure for FHF is based on a clinical observation that the presence of a necrotic liver causes cardiovascular instability and renal as well as respiratory insufficiency which is described as 'toxic liver syndrome'. Husberg et al. (6) in 1991 described hepatic devascularization rather than total hepatectomy for three patients with FHF and noted improvement in the acidosis with diuresis after isolation of the failing liver. Rozga et al. (7) in 1993 reported combination of hypothermia, plasma exchange, and extracorporeal liver support with total hepatectomy. Their patient was anhepatic for 14 hr but

recovered completely after two liver transplants. In our patient, we used CHDF throughout the anhepatic period. As compared to other 5 patients with FHF in our institution, our patient woke up much faster after LDLT. This may be in part due to the clearance of toxic metabolite during the anhepatic period by CHDF. In this regard, intentional anhepatic preconditioning by early total hepatectomy of the failing liver in combination with CHDF or artificial liver support before allograft implantation may facilitate recovery from acute liver failure.

A controversial issue in performing the two-staged liver transplantation for FHF has been the uncertainty with the availability of liver allografts and rather poor outcome (8). In LDLT, however, a viable graft can certainly be obtained at any given time, provided that the donor is willing, medically suitable for donation, and mentally supported.

Furthermore, although liver transplantation for FHF itself is a life-saving procedure, the influence of this procedure on the surgical practice at a hospital level is significant, especially if donor operation is also performed at the same time. We believe that for low-volume transplant centers, the two-stage LDLT for FHF can be performed in combination with emergency surgical procedures.

REFERENCES

1. **Williams R, Wendon J.** Indications for orthotopic liver transplantation in fulminant hepatic failure. *Hepatology* 1994; 20: 5S.
2. **Matsunami H, Makuuchi M, Kawasaki S, et al.** Living-related liver transplantation in fulminant hepatic failure. *Lancet* 1992; 340: 1411.
3. **Ringe B, Pichlmayr R, Lubbe N, Bornscheuer A, Kuse E.** Total hepatectomy as temporary approach to acute hepatic or primary graft failure. *Transplant Proc* 1988; 20: 552.
4. **Ringe B, Pichlmayr R, Ziegler H, et al.** Management of severe hepatic trauma by two-stage total hepatectomy and subsequent liver transplantation. *Surgery* 1991; 109: 792.
5. **Ringe B, Lubbe N, Kuse E, Frei U, Pichlmayr R.** Management of emergencies before and after liver transplantation by early total hepatectomy. *Transplant Proc* 1993; 25: 1090.
6. **Husberg BS, Goldstein RM, Klintmalm GB, et al.** A totally failing liver may be more harmful than no liver at all: three cases of total hepatic devascularization in preparation for emergency liver transplantation. *Transplant Proc* 1991; 23: 1533.

7. **Rozga J, Podesta L, LePage E, et al.** Control of cerebral oedema by total hepatectomy and extracorporeal liver support in fulminant hepatic failure. *Lancet* 1993; 342: 898.

8. **Lee WM.** Total hepatectomy for acute liver failure: don't take out my liver! *Gastroenterology* 1994; 107: 894.

Legend for the Figure

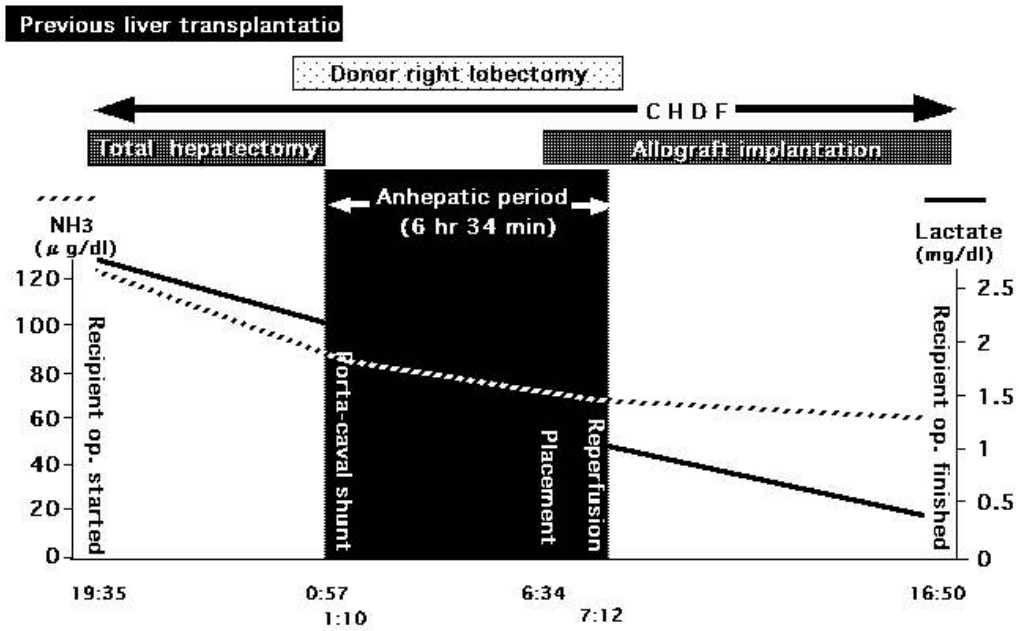


Fig. 1: Operative course of the two-staged living-related liver transplantation for a patient with fulminant hepatic failure.