

Title:

Putty lung: pulmonary parenchymal calcification due to tuberculosis

Authors:

¹Kuniaki Hayashi, MD, ²Kazuto Ashizawa MD, ³Masaaki Fukuda MD, ⁴Mayumi Ohtsubo MD,

Address of the authors:

¹Department of Radiology, Nagasaki University, 1-7-1 Sakamoto, Nagasaki 852-8501, Japan

² Clinical Oncology Center, Nagasaki University Hospital, 1-7-1 Sakamoto, Nagasaki 852-8501, Japan

Departments of ³Internal Medicine and ⁴Radiology, Japanese Red Cross Nagasaki Genbaku Hospital, 3-15 Morimachi, Nagasaki 852-8511, Japan

Corresponding author:

Kazuto Ashizawa, MD

Clinical Oncology Center, Nagasaki University Hospital

1-7-1 Sakamoto, Nagasaki 852-8501, Japan

Tel.: + 81-95-819-7778

Fax: + 81-95-819-7776

E-mail: ashi@nagasaki-u.ac.jp

Type of manuscript: Letter to the editor

Letter to the editor

A 71-year-old woman came to the hospital for regular check up. She had no symptoms. Past history revealed that her right kidney was removed approximately 30 years before. No detail of the removed kidney was available.

Posteroanterior and lateral chest radiographs showed two round opacities in the medial portion of the right lower lung field, simulating mediastinal tumors (Figs. 1, 2). The right hilum was low in height and the right lung appeared slightly radiolucent. Chest CT was then obtained and this showed two white masses (Fig. 3). The intermediate bronchus was completely occluded, and there were calcifications in its wall. We immediately came to the diagnosis of right middle and lower lobes collapse that were calcified. The appearance of chest CT closely resembles that of “putty kidney”.

“Putty kidney” refers to the densely calcified kidney. It represents the state of autonephrectomy resulting from renal parenchymal destruction and caseation due to renal tuberculosis. Associated with tuberculous ureteric stricture, the urine is negative for *Mycobacterium tuberculosis*. This is considered to be some self-defense mechanism to confine the organisms in the kidney.

We concluded that the patient had pulmonary and bronchial tuberculosis, and no bacteriological or histological confirmation was necessary. We speculated that she might

also have suffered from right renal tuberculosis.

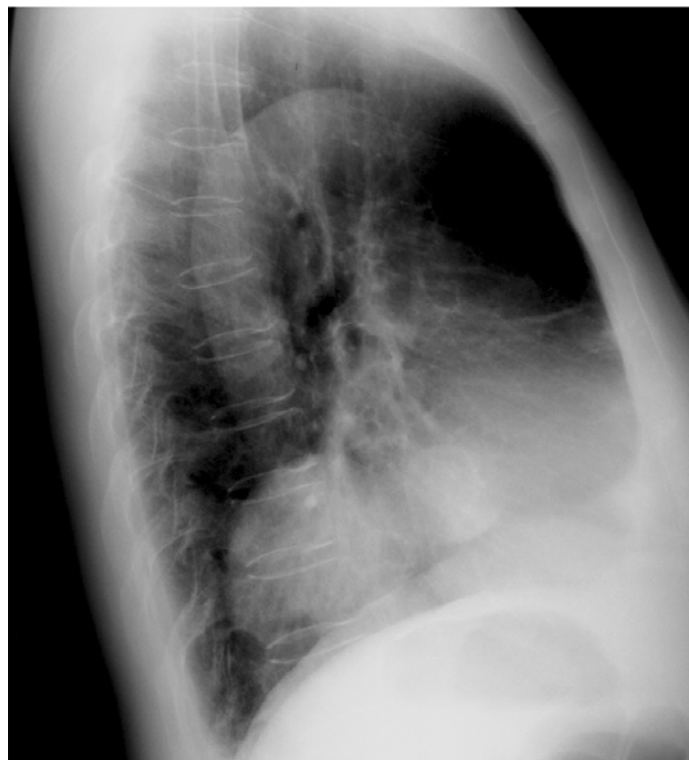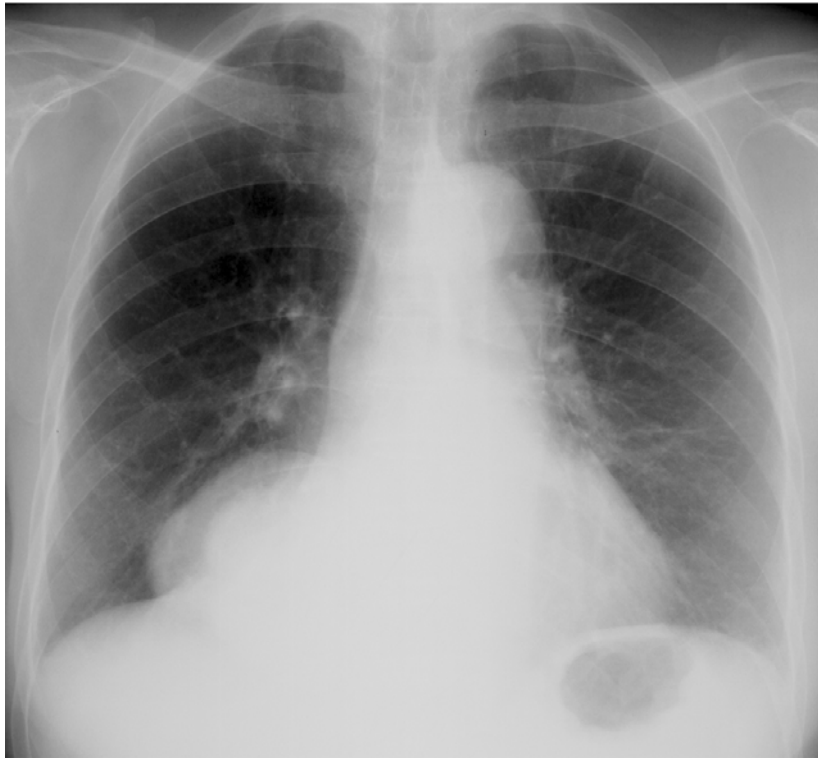
We would like to dub the chalky white CT appearance of the lung as “putty lung”.

Even a term “autopneumonectomy” may also be justified.

References

1. Dyer RB, Chen MY, Zagoria RF. Classic Signs in Uroradiology. *RadioGraphics* 2004; 24:S247-S280.
2. Kollins SA, Hartman GW, Carr DT, Segura JW, Hattery RT: Roentgenographic findings in urinary tract tuberculosis. *AJR Am J Roentogenol* 1974;121:487-499

Figure legends



Figs. 1 and 2: PA and lateral chest radiographs showing two round opacities in the right lower lung field, simulating mediastinal tumors.

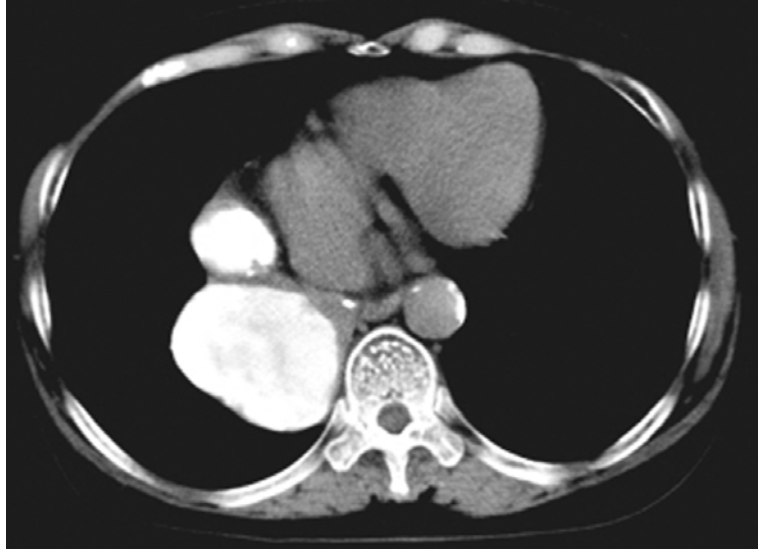

Fig. 3: Chest CT showing two white masses.