

Reversible visual disturbance due to cryptococcal uveitis in a non-HIV individual

Shigeki NAKAMURA¹⁾, * Koichi IZUMIKAWA¹⁾, Masafumi SEKI¹⁾, Kyoko FUJIMOTO³⁾, Kazuaki MISHIMA³⁾, Hiroshi KAKEYA¹⁾, Yoshihiro YAMAMOTO¹⁾, Katsunori YANAGIHARA¹⁾²⁾, Yohei MIZUTA¹⁾, Takashi KITAOKA³⁾, and Shigeru KOHNO¹⁾⁴⁾

¹⁾Second Department of Internal Medicine, ²⁾Department of Laboratory Medicine, and

³⁾Department of Ophthalmology, Nagasaki University Graduate School of Biomedical Sciences

⁴⁾Division of Molecular & Clinical Microbiology, Department of Molecular Microbiology & Immunology, Nagasaki University Graduate School of Medical Science, Nagasaki

Corresponding author:

Koichi IZUMIKAWA, M.D., Ph.D.

Second Department of Internal Medicine, Nagasaki University School of Medicine

1-7-1 Sakamoto, Nagasaki 852-8501, JAPAN

Phone: +81-95-849-7276, Fax: +81-95-849-7285

Summary

A 52-year-old man without underlying diseases visited the local hospital with symptoms of memory deficit and mild headache. Radiological examination of the brain with computed tomography (CT) revealed hydrocephalus. Etiology was not revealed by cerebrospinal fluid (CSF) analysis, and a ventricular-atrial (V-A) shunt was installed. The patient had congestion and dacryorrhea of the right eye and diagnosed uveitis three months after placement of the V-A shunt. The serum cryptococcal antigen (**CrAg**) tested positive at a titration of 64 times. Additionally, the right eye anterior chamber aqueous humor (ACAH), cerebrospinal fluid (CSF) and prostate fluid were positive for Cryptococcus antigen at a titration of 128 times; and *Cryptococcus neoformans var. grubii* was isolated from the peripheral blood, CSF and ACAH, resulting in a diagnosis of disseminated cryptococcosis. Fluconazole (FLCZ) at 800 mg/day was administered for the first two days, followed by a 400 mg /day maintenance dose. After six months of treatment, his visual power recovered. This is a rare disseminated cryptococcosis with uveitis case, successfully treated by FLCZ. Disseminated cryptococcosis should be considered in cases with mild symptoms, and V-A shunt installation for hydrocephalus.

Key Words

Cryptococcal uveitis, V-A shunt, disseminated cryptococcosis, non-HIV individual,
Fluconazole loading dose.

Introduction

Cryptococcus neoformans can infect not only HIV-positive patients and non-HIV-infected immunocompromised patients, but also apparently immunocompetent patients. Cryptococcal infection is a common deep mycosis, and 10% of all pulmonary cryptococcus infections cause non-symptomatic meningoencephalitis. Cryptococcal endophthalmitis in non-immunosuppressed patients is rare, and the visual disturbance frequently causes a loss of visual power. We succeeded in treating a patient with disseminated cryptococcosis with severe endophthalmitis by using a loading dose of fluconazole (FLCZ) and flucytosine (5-FC).

Case Report

A 52-year-old man, who was a roofer and had previously been healthy, visited the local hospital in July 2003 complaining of memory deficit and mild headache. Radiological examination by brain CT revealed an enlargement of the lateral ventricle. The analysis of cerebrospinal fluid (CSF) including appearance, cell counts and measurement of total protein and glucose showed no abnormality, but there was an increased opening pressure of 210 mm H₂O. The etiology of hydrocephalus, such as bacteria, tuberculosis, viral infection, and malignant diseases were excluded by culture,

PCR, and antibody test.

Although the definite etiology was not known, corticosteroids were administered, but the results were ineffective. Neurosurgical intervention, with a ventricular-peritoneal shunt (V-P shunt), was then performed to relieve the hydrocephalus. Symptoms and CSF pressure improved soon afterward. Three months later, the patient's symptoms re-appeared due to decreased function of the shunt. The V-P shunt was replaced with a Ventricular-atrial shunt (V-A shunt).

Three months after installation of the V-A shunt, the patient had congestion and dacryorrhea of the right eye. He was diagnosed with uveitis by an ophthalmologist. A fundus examination revealed bilateral multiple white spots on the fundus oculi, with more serious findings in the right eye (Figure 1). His visual acuity in the right eye was 20/500, and in the left eye, it was 20/10. He was treated with dexamethasone injected directly into the subconjunctival space for seven days; however, the lesion enlarged. Intraocular hemorrhage occurred in the white spots and vitreous opacities were observed, and the patient's eyesight declined significantly. An infectious uveitis was expected because of the rapid exacerbation.

The patient was referred to the infectious diseases department for further management, and to confirm the diagnosis. On admission, laboratory findings showed a

slightly elevated serum concentration of C-reactive protein (CRP) and a high erythrocyte sedimentation rate. The patient's immune status was normal. A tuberculin skin test was positive, and the responses of peripheral blood T cells to mitogens were normal. Although eosinophilic cryptococcal meningoencephalitis has been shown to occur especially in patients with hematological malignancies, no eosinophilia was observed in our case [1]. Cryptococcal infection was suspected because of the patient's history of hydrocephalus of unknown origin, with no symptoms other than memory deficit. The serum cryptococcal antigen (CrAg) test was positive at a titration of 64 times. Additionally, the right eye anterior chamber aqueous humor (ACAH), CSF, and prostate fluid were positive for *Cryptococcus* antigen at a titration of 128 times. Yeast-like cells with a thick capsule were observed with India ink stain in both the ACAH and CSF. *Cryptococcus neoformans* var. *grubii* (the serotype was determined by using a Crypto Check serotyping kit from Iatron Laboratories, Tokyo, Japan) was isolated on Sabouraud dextrose agar from the patient's peripheral blood, CSF and ACAH, resulting in the diagnosis of disseminated cryptococcosis. A drug susceptibility test was performed according to the M27-A2 protocol of CLSI [2], and the minimum inhibitory concentrations (MICs) were as follows: amphotericin-B (AMPH-B) 0.5µg/ml; fluconazole (FLCZ) 2µg/ml; itraconazole 0.125µg/ml; flucytosine (5-FC)

4.0µg/ml. It was reported that the antifungal drug susceptibility to *C. neoformans* was determined as follows [3]: FLCZ: SDD (susceptible-Dose Dependent) 2-8µg/ml; 5-FC: S 2-8µg/ml. FLCZ and 5-FC had good susceptibility in our case.

As a roofer, he had opportunities to come in contact with pigeons' nests.

C. neoformans is often found in soil enriched with bird droppings. The patient's immune status and general status were normal. We administered FLCZ at 800 mg/day for the first two days, followed by a 400 mg /day maintenance dose. FLCZ trough levels were 33.5 µg/ml and 15.8 µg/ml in the ACAH and serum respectively, which indicated excellent FLCZ penetration to the eye tissue. The patient's visual acuity gradually improved, but the vitreous opacities remained, so we added oral 5-FC (6 g/day) 29 days after the initiation of FLCZ.

His eyesight returned to 20/30 after thirty days of FLCZ treatment, which is what it was before the illness began. The cryptococcus antigen levels in the serum, ACAH, and CSF decreased to $\times 16$, $\times 64$, and $\times 8$, respectively. Bilateral multiple white spots on the fundus oculi almost resolved 6 months after antifungal treatment. Since the pathogen was not detected in the India ink stain and was not isolated by culture 6 months after initiation of treatment (Cryptococcus antigen levels in CSF maintained $\times 2$), antifungal agents were discontinued and no recurrence was observed.

Discussion

Deep seated fungal infections caused by *Candida* spp., *Aspergillus* spp. and *C. neoformans* are on the rise despite recent medical advances. *C. neoformans* is recognized as the third most common fungal pathogen in autopsied cases in Japan, and is a worldwide, ubiquitous fungus found particularly in soil contaminated by pigeon or chicken droppings. In particular, cryptococcal infection occurs not only in immunocompromised patients such as those with AIDS, transplant recipients, or hematological malignancies and those receiving corticosteroids, but also in healthy individuals. Cryptococcal meningoencephalitis is the most common life-threatening, opportunistic fungal meningitis. Despite the advent of new antifungal drugs and modern imaging techniques, mortality and morbidity rates of cryptococcal meningoencephalitis remain high. Hydrocephalus is an occasional complication of cryptococcal meningoencephalitis. Delays in the diagnosis and treatment of hydrocephalus are directly related to poor outcome, including various degrees of residual neurological sequelae [4]. In addition, cryptococcal endophthalmitis is rare [4]. According to a review from Crump et al [5], only 27 cases have been reported over the last 23 years, and almost half of these had no underlying diseases. Only six (27%) out of 22 patients with central nervous system (CNS) involvement had ocular lesions before developing

symptomatic meningitis. Cryptococcal endophthalmitis frequently results in severe visual loss, and return of normal vision following treatment is uncommon.

In this case, cryptococcal meningitis might have existed prior to installation of the V-A shunt although an antigen test of CSF was not performed, and the shunt might be the major cause of disseminated cryptococcosis, including uveitis. Early shunt replacement for hydrocephalus is recommended to avoid irreversible neurological complications [6]. Tang also reported the efficacy of the V-A shunt for cryptococcal meningitis, and an active stage of cryptococcal meningitis does not contraindicate the necessity of shunting. Premedication with antifungal drugs is unnecessary [7]. There are eight reports regarding cryptococcal ventricular shunt infection [8-12]. Seven of the eight cases had clinical syndromes consistent with reactivation of an endogenous infection between 10 days and 12 months after placement of the shunt. Although treatment regimens included AMPH-B and 5-FC in all cases, cryptococcal shunt infection had poor outcomes; four of the eight patients died.

In our case, we administered FLCZ because clinical symptoms were mild, there was evidence of effectiveness for the treatment of cryptococcal meningitis [13,14], there was good penetration into the CNS and eye tissue [15,16,], and it is less toxic than AMPH-B.

This resulted in better compliance for long-term usage of FLCZ. We successfully treated disseminated cryptococcosis, including uveitis, with this drug.

Recently, fungal infections and formation of biofilms affecting intravascular devices are well known, particularly *Candida* species. *C. neoformans* is also reported to form biofilm on polystyrene plates [17] and prosthetic medical devices, including ventriculoatrial shunt catheters [8]. Biofilm formation is associated with persistent infection, since biofilm increases resistance against host immune systems and antimicrobial or antifungal therapy by constituting a physical barrier, so it could be correlated with poor outcome. Martinez et al investigated the efficacy of antifungal agents to cryptococcus biofilm in vitro, and reported that *C. neoformans* cells and preformed biofilm were susceptible to AMPH-B and caspofungin [18]. In our case, the possibility that biofilm formed in the V-A shunt is less likely since no recurrence was confirmed after discontinuation of treatment, and without removing the V-A shunt.

In conclusion, cryptococcal meningitis often progresses slowly and gradually, with mild symptoms [19], compared with meningoencephalitis due to other pathogens, such as herpes virus, bacteria or tuberculosis. Delayed diagnosis and initiation of treatment often result in disseminated disease and poor outcome. When we evaluate patients with

hydrocephalus and mild, slowly progressing symptoms, we should consider the possibility of cryptococcal meningitis and perform the cryptococcal antigen test. In addition, shunt-induced, disseminated cryptococcal infection should also be considered when a V-A shunt is installed in the patient with cryptococcal meningitis.

References

1. Grosse P, Schulz J, Schmierer K. Diagnostic pitfalls in eosinophilic cryptococcal meningoencephalitis. *Lancet Neurol* 2003; **8**: 512.
2. National Committee for Clinical Laboratory Standards. Reference Method for Broth Dilution Antifungal Susceptibility Testing of Yeasts—Second Edition: Approved Standard M27-A2 (2002) Wayne, PA, USA: NCCLS.
3. Rex JH, Pfaller MA, Galgiani JN, et al. Development of interpretive breakpoints for antifungal susceptibility testing: conceptual framework and analysis of in vitro-in vivo correlation data for fluconazole, itraconazole, and candida infections. Subcommittee on Antifungal Susceptibility Testing of the National Committee for Clinical Laboratory Standards. *Clin Infect Dis* 1997; **24**: 235-247.
4. Denning DW, Armstrong RW, Eishman M, Stevens DA. Endophthalmitis in a patient with disseminated cryptococcosis and AIDS who was treated with itraconazole. *Rev Infect Dis* 1991; **13**: 1126-1130.
5. Crump JR, Elnor SG, Elnor VM, Kauffman CA. Cryptococcal endophthalmitis: case

report and review. Clin Infect Dis 1992; **14**: 1069-1073.

6. Park MK, Hospenthal DR, Bennett JE. Treatment of hydrocephalus secondary to cryptococcal meningitis by use of shunting. Clin Infect Dis 1999; **28**: 629-633.

7. Tang LM. Ventriculoperitoneal shunt in cryptococcal meningitis with hydrocephalus. Surg Neurol 1990; **33**: 314-319.

8. Magham D, Gerding DN, Peterson LR, Sarori GA. Fungal meningitis presenting as hydrocephalus. Arch Intern Med 1983; **143**: 728-731.

9. Walsh TJ, Schlegel R, Moody MM, Costerton JW, Salzman M. Ventriculoatrial shunt infection due to *Cryptococcus neoformans*: an ultrastructural and quantitative microbiological study. Neurosurgery 1986; **18**: 373-375.

10. Crum CP, Feldman PS. Cryptococcal peritonitis complicating a ventriculoperitoneal shunt in unsuspected cryptococcal meningitis. Human pathology 1981; **12**: 660-663.

11. Yadav SS, Perfect J, Friedman AH. Successful treatment of cryptococcal ventricular shunt infection with systemic therapy alone. *Neurosurgery* 1988; **23**: 372-373.

12. Ingram CW, Haywood HB 3rd, Morris VM, Allen RL, Perfect JR. Cryptococcal Ventricular-Peritoneal Shunt Infection: Clinical and Epidemiological Evaluation of Two Closely Associated Cases. *Infect Control Hosp Epidemiol* 1993; **14**: 719-722.

13. Hossain MA, Mukherjee PK, Reyes G, Long L, Ghannoum MA. Effects of fluconazole singly and in combination with 5-fluorocytosine or amphotericin B in the treatment of cryptococcal meningoencephalitis in an intracranial murine model. *J Chemother* 2002; **14**: 351-360.

14. Mayanja-Kizza H, Oishi K, Mitarashi S, et al. Combination therapy with fluconazole and flucytosine for cryptococcal meningitis in Ugandan patients with AIDS. *Clin Infect Dis* 1998; **26**: 1362-1366.

15. Mian UK, Mayers M, Garg Y, et al. Comparison of fluconazole pharmacokinetics in serum, aqueous humor, vitreous humor, and cerebrospinal fluid following a single dose

and at steady state. *J Ocul Pharmacol Ther* 1998; **14**: 459-471.

16. Abbasoglu OE, Hosal BM, Sener B, Erdemoglu N, Gursel E. Penetration of topical fluconazole into human aqueous humor. *Exp Eye Res* 2001; **72**: 147-151.

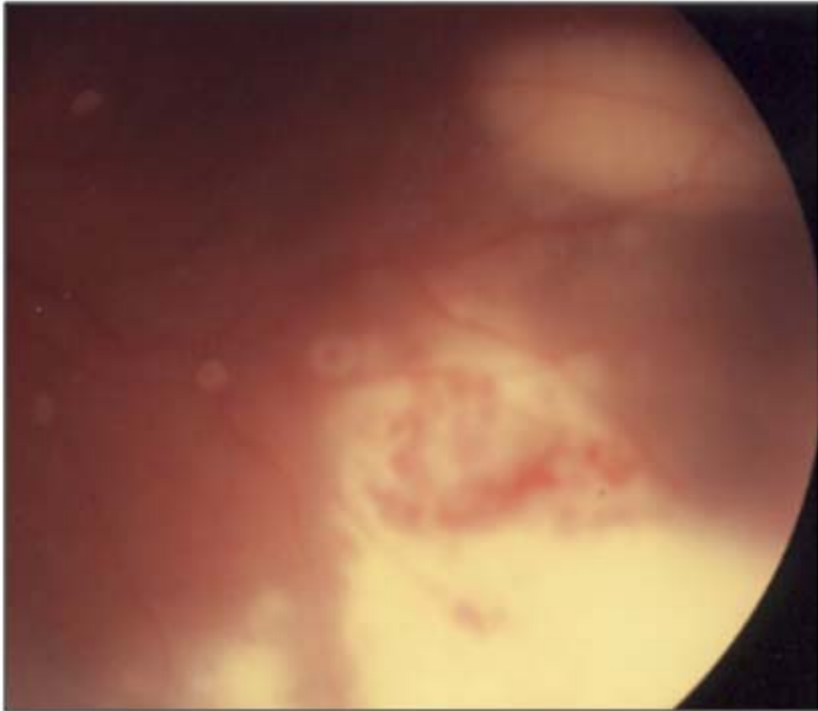
17. Yadav SS, Perfect J, Friedman AH. Successful treatment of cryptococcal ventricular shunt infection with systemic therapy alone. *Neurosurgery* 1988; **23**: 372-373.

18. Martinez LR, Casadevall A. Susceptibility of *Cryptococcus neoformans* biofilms to antifungal agents in vitro. *Antimicrob Agents Chemother* 2006; **50**: 1021-1033.

19. Kwon-Chung KJ, Polacheck I, Bennett JE. Cryptococcosis. In Kwon-Chung KJ, Bennett JE, eds. *Medical Mycology*. Philadelphia: Lea & Febiger, 1992: 397-446.

Figure legends

Figure 1.



Cryptococcal uveitis

Multiple white spots are shown in the right ocular fundus.