

Paroxysmal Thyroid Swelling. A Forgotten Clinical Finding of Pheochromocytoma

Kan Nakamura,* Mariko Ogata,* Takao Ando, Toshiro Usa, and Atsushi Kawakami

Unit of Translational Medicine, Nagasaki University Graduate School of Biomedical Sciences, Nagasaki 852-8501, Japan

A 29-yr-old woman was admitted to our hospital because of visible paroxysmal thyroid swelling (PTS) (Fig. 1) that developed 1 yr before. She had additional symptoms including palpitations, shortness of breath, and headaches that occurred every few days. Because she was found to have a left adrenal tumor, pheochromocytoma was suspected. Plasma catecholamine levels were unremarkable when she was asymptomatic. During symptomatic spells, she was hypertensive (180/100 mm Hg) and tachycardic (100 bpm) with high plasma epinephrine (417 pg/ml; <100 pg/ml) and norepinephrine (2665 pg/ml; 100 to 450 pg/ml). An ultrasound showed a transient (<15 to 60 min) thickening of the thyroid (Fig. 2). We also found that multiple intrathyroidal hypoechoic areas were reproducibly seen only during the spells, and some hypoechoic areas showed blood flow but others did not, suggesting edema, in the Doppler study (data not shown). The thyroid function tests (TSH, free T₃, and free T₄) taken before, during, and the day after the spell were unremarkable. The left adrenal tumor showed a positive ¹²³I-metaiodobenzylguanidine accumulation, confirming pheochromocytoma. The patient underwent left adrenalectomy, and the histological finding was consistent with pheochromocytoma. Her symptom of PTS disappeared thereafter.

PTS in pheochromocytoma, first described in 1937 (1), has been scarcely reported and was forgotten for nearly 30 yr (2, 3). The cases of pheochromocytoma showing PTS, including ours, are norepinephrine-secreting, and it has been shown that the thyroid gland was enlarged upon iv injection of norepinephrine, but not of epinephrine (4). We have clearly shown that PTS was manifested as a thickening of the thyroid caused by multiple edemas associated with increased blood flow.

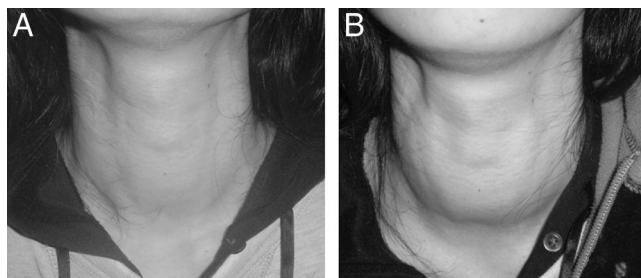


FIG. 1. Overt paroxysmal thyroid swelling. Photos of the patient taken without swelling (A) and during a spell (B). Note that the thyroid gland swelling is apparent during the spell.

The physical finding of PTS seems unique to predominantly norepinephrine-producing pheochromocytoma. Although PTS is a rare manifestation of pheochromocytoma, it can be an important clue to the diagnosis. Therefore, physicians should be aware of this rare sign of the disease and look for it when performing a workup for pheochromocytoma.

Acknowledgments

Address all correspondence and requests for reprints to: Takao Ando, M.D., Ph.D., Unit of Translational Medicine, Nagasaki University Graduate School of Biomedical Sciences, 1-7-1 Sakamoto, Nagasaki, Nagasaki 852-8501, Japan. E-mail: takaoando@gmail.com.

We thank Dr. Yaron Tomer, Mount Sinai Medical Center, New York, for his critical suggestions to our manuscript.

Disclosure Summary: The authors have nothing to disclose.

References

1. Howard JE, Barker WH 1937 Paroxysmal hypertension and other clinical manifestation associated with benign chromaffin cell tumor (phaeochromocytoma). *Bull Johns Hopkins Hosp* 61:371–410

* K.N. and M.O. contributed equally to the report.
Abbreviation: PTS, Paroxysmal thyroid swelling.

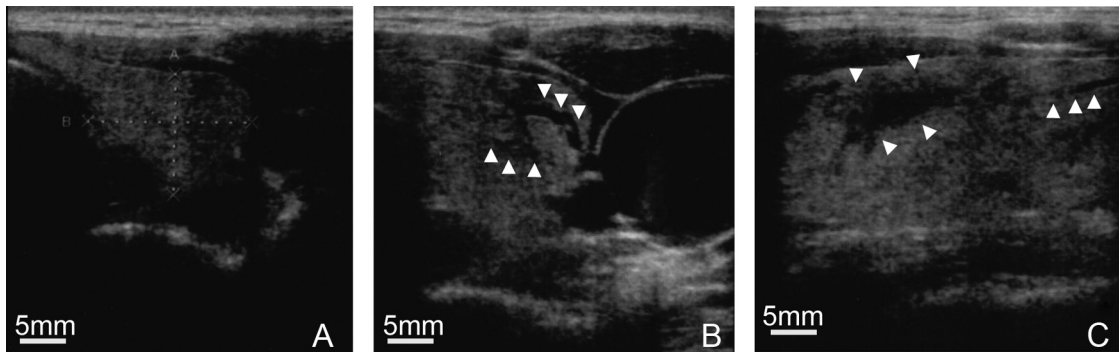


FIG. 2. Paroxysmal thyroid swelling detected by ultrasound. The left thyroid lobe thickened from 12.5 mm (A) to 20.2 mm during a spell (B). Hypoechoic areas, indicated by *arrowheads*, are apparent during a spell (B and C).

2. **Buckels JA, Webb AM, Rhodes A** 1983 Is paroxysmal thyroid swelling due to phaeochromocytoma a forgotten physical sign? *Br Med J (Clin Res Ed)* 287:1206–1207
3. **Bauer J, Belt E** 1947 Paroxysmal hypertension with concomitant swelling of the thyroid due to pheochromocytoma of the right ad-renal gland; cure by surgical removal of the pheochromocytoma. *J Clin Endocrinol Metab* 7:30–46
4. **Barnett A, Blacket R, Depoorter A, Sanderson P, Wilson G** 1950 The action of noradrenaline in man and its relationship to phaeochromocytoma and hypertension. *Clin Sci* 9:151–179



**Earn CME Credit for
“Approach to the Patient” articles in *JCEM*!**

www.endo-society.org