

Surgical Technique

Single-incision laparoscopic distal pancreatectomy

Tamotsu Kuroki, Tomohiko Adachi, Tatsuya Okamoto, Takashi

Kanematsu

Running title: Single-incision laparoscopic distal
pancreatectomy.

Department of Surgery, Nagasaki University, Graduate School of
Biomedical Sciences, 1-7-1 Sakamoto, Nagasaki 852-8501, Japan

Correspondence to: Tamotsu Kuroki, Department of Surgery,
Nagasaki University, Graduate School of Biomedical Sciences,
1-7-1 Sakamoto, Nagasaki 852-8501, Japan.

E-mail: tkuroki-gi@umin.ac.jp

Telephone: +81-95-8197316

Fax: +81-95-8197319

Abstract

Single-incision laparoscopic surgery (SILS) is a novel area of minimally invasive surgery, and rapidly evolving in the field of abdominal surgery. However, SILS is not a common procedure for pancreatic surgery. We describe our first experience with a SILS approach in a patient with a metastatic pancreatic tumor. We performed a SILS distal pancreatectomy (SILS-DP) using 3 trocars placed through a single port at an umbilical incision. In our case, the most important surgical technique was the stomach-hanging method to obtain a favorable laparoscopic view of the pancreas. Although SILS-DP is a safe and feasible procedure, further studies are required to determine the advantages of this procedure in comparison with the standard laparoscopic method.

Key words: Single-incision laparoscopic surgery, distal pancreatectomy, minimally invasive surgery, stomach-hanging method.

Introduction

Laparoscopic distal pancreatectomy (Lap-DP) has already become one of the standard operative methods of pancreatectomy (1-3). On the other hand, single-incision laparoscopic surgery (SILS) has recently drawn attention for its minimally invasiveness (4-6). SILS was developed to minimize postoperative pain, reduce surgical invasiveness, and improve the cosmetic outcome. Recently, this approach has been most commonly described for cholecystectomy and appendectomy (7-11). Herein, we describe a surgical technique of SILS distal pancreatectomy (SILS-DP), especially our devices and techniques for achieving a suitable surgical field and laparoscopic view.

Patient and operative technique

A 79-year-old man was admitted to our department for operation based on the diagnosis of metastatic pancreatic tumor from a thyroid carcinoma in August, 2010. The patient underwent total thyroidectomy by a diagnosis of thyroid carcinoma six months ago. Abdominal CT revealed a 15-mm-diameter mass in the pancreatic body, and it showed strong staining on contrast-enhanced CT imaging (Fig.

1).

Under general anesthesia, the patient was placed in the reverse Trendelenburg position. The operating surgeon stood to the right of the table, with the assistant surgeon and laparoscopist to the left. Two video monitors were positioned near the head of the table. A 25-mm longitudinal incision was made through the center of the umbilicus, and the natural umbilical defect was used to access the peritoneum. The SILS™ port (Covidien, Inc., Norwalk, CT, USA) was inserted through this incision, and the pneumoperitoneum was set at 8 mm Hg. We used two 5-mm working trocars for standard 5-mm laparoscopic instruments. A third trocar was used for the 5-mm flexible laparoscope (Olympus, Tokyo, Japan). First, the gastrocolic ligament was divided using a 5-mm LigaSure V vessel sealing instrument (Covidien) and the pancreas was exposed. Next, it was important to obtain a sufficient working space and to ensure an adequate laparoscopic view. To maintain the exposure of the pancreas, the body of the stomach was taped using a Penrose drain. Both ends of the Penrose drain were ligated by a 2-0 nylon thread with a straight needle. To put a Penrose drain through the posterior of the stomach, the lesser omentum

was cut, and then the stomach was pulled by the Penrose drain, and a straight needle was then passed extracorporeally through the abdominal wall in the left subcostal area finally, the stomach was fixed to the abdominal wall (Fig. 2). We called this method of retraction of the stomach during SILC the "stomach-hanging method". The location of the pancreatic tumor was confirmed directly by a laparoscopic ultrasonography from the anterior surface of the pancreas. The retroperitoneum was incised along the superior and inferior borders of the pancreas, and then the margin of the pancreas was exposed and mobilized. To conserve the splenic artery and vein, the branches of the splenic artery and vein were divided by LigaSure V. The extent of the pancreatic resection was determined by a laparoscopic ultrasonography. Then, the pancreatic parenchyma was transected 1cm proximal to the tumor with an endoscopic linear stapler (EndoGIA-II 60-4.8; Covidien). A 2-mm loop-type retractor (Mini-loop retractor II; Covidien) was inserted directly at the abdominal left upper quadrant then the stump of the pancreas was tightened with the Mini-loop retractor II (Fig. 3). The stump of the pancreas was then retracted laterally away from the splenic vessels and the retroperitoneum. The

pancreatic tail was mobilized by the medial-to-lateral approach, and a tunnel was created at the splenic hilum. Then, the pancreatic tail without splenic vessels was divided with a linear stapler (EndoGIA-II 60-2.5; Covidien). The specimen was placed in an endoscopic bag retrieval system (Endo-catch II; Covidien) through an umbilical incision. Spleen and splenic vessels were preserved. The SILS™ Port was removed, and then the defect in the fascia was repaired with a 0-Vicryl (Ethicon, Brunswick, NJ, USA) suture, and the skin was closed with a subcuticular 4-0 PDS-II (Ethicon) suture. No drain was inserted. The operating time was 285 minutes, and blood loss was 20 ml. The patient's postoperative course was uneventful. He was discharged home on the 11th postoperative day.

Discussion

Recently, SILS has been performed for a wide variety of surgical procedures (4-14). However, SILS is not a common surgical method in pancreatic surgery because of technical difficulties.

Especially, it is difficult to ensure a suitable laparoscopic surgical view and a favorable expansion of the operative field because there is a limit to the number of the laparoscopic instruments in SILS. In our procedure, we used the stomach-hanging method to obtain a favorable laparoscopic view of the pancreas. This method is simple and easy and requires no special surgical instruments, not even the laparoscopic forceps. On the other hand, it is important to lift up the stump of the pancreas to obtain the optimal tension for the dissection along the pancreatic tail by the medial-to-lateral approach. We used a Mini-loop retractor II for tightening and lifting up the stump of the pancreas. This loop-type retractor was useful for SILS-DP, as it allowed the tail of the pancreas to be adequately mobilized without adding laparoscopic ports.

The SILS-DP approach remains a challenging alternative to conventional laparoscopic procedures. It is unknown whether the

SILS-DP is less invasive than the conventional procedure. However, SILS-DP may offer the advantage of better esthetic results because the skin incision for the SILS-DP is made in the umbilicus and as such is virtually scarless.

The SILS port we selected allowed for the use of three laparoscopic instruments simultaneously through the umbilicus (7, 15). Another surgical procedure that is useful in SILC involves the insertion of multiple trocars via separate fascial punctures through the same incision at the umbilicus. However, a recent report has described that the pneumoperitoneum leaks from the side of each port and intraperitoneal pressure cannot be maintained (14, 15). One of the advantages of the SILS port is reducing the loss of pneumoperitoneum due to the high airtightness (7, 15). Following a single transumbilical incision, SILS-DP using the SILS port could be performed with an appropriate laparoscopic surgical view and field using the innovative technique described here. Further studies are required to evaluate the specific benefits of SILS-DP.

References

1. Nakamura Y, Uchida E, Aimoto T, et al.: Clinical outcome of laparoscopic distal pancreatectomy. *J Hepatobiliary Pancreat Surg* 2009; 16:35-41.
2. Kooby DA, Gillespie T, Bentrem D, et al.: Left-sided pancreatectomy: a multicenter comparison of laparoscopic and open approaches. *Ann Surg* 2008; 248:438-446.
3. Matsumoto T, Shibata K, Ohta M, et al.: Laparoscopic distal pancreatectomy and open distal pancreatectomy: a nonrandomized comparative study. *Surg Laparosc Endosc Percutan Tech* 2008; 18:340-343.
4. Chamberlain RS, Sakpal SV: A comprehensive review of single-incision laparoscopic surgery (SILS) and natural orifice transluminal endoscopic surgery (NOTES) techniques for cholecystectomy. *J Gastrointest Surg* 2009; 13:1733-1740.
5. Froghi F, Sodergren MH, Darzi A, et al.: Single-incision laparoscopic surgery (SILS) in general surgery: a review of current practice. *Surg Laparosc Endosc Percutan Tech* 2010; 20:191-204.
6. Romanelli JR, Earle DB: Single-port laparoscopic surgery: an

overview. *Surg Endosc* 2009; 23:1419-1427.

7. Ito M, Asano Y, Horiguchi A, et al.: Cholecystectomy using single-incision laparoscopic surgery with a new SILS port. *J Hepatobiliary Pancreat Sci* 2010; 17:688-691.

8. Ponsky TA: Single port laparoscopic cholecystectomy in adults and children: tools and techniques. *J Am Coll Surg* 2009; 209:e1-6.

9. Rivas H, Varela E, Scott D: Single-incision laparoscopic cholecystectomy: initial evaluation of a large series of patients. *Surg Endosc* 2009; 24:1403-1412.

10. Oltmann SC, Garcia NM, Ventura B, et al.: Single-incision laparoscopic surgery: feasibility for pediatric appendectomies. *J Pediatr Surg* 2010; 45:1208-1212.

11. Romanelli JR, Roshek III TB, Lynn DC, et al.: Single-port laparoscopic cholecystectomy: initial experience. *Surg Endosc* 2009; 24:1374-1379.

12. Vestweber B, Alfes A, Paul C, et al.: Single-incision laparoscopic surgery: a promising approach to sigmoidectomy for diverticular disease. *Surg Endosc* 2010;

DOI 10.1007/s00464-010-1090-2.

13. Mohiuddin SS, Anderson CE: A novel application for

single-incision laparoscopic surgery (SILS): SIL jejunostomy feeding tube placement. *Surg Endosc* 2010; DOI 10.1007/s00464-010-1168-x.

14. Tacchino RM, Greco F, Matera D: Laparoscopic gastric banding without visible scar: a short series with intraumbilical SILS. *Obes Surg* 2010; 20:236-239.

15. Tunca F, Senyurek YG, Terzioglu T, et al.: Single-incision laparoscopic left adrenalectomy. *Surg Laparosc Endosc Percutan Tech* 2010; 20:291-294.

Figure legends

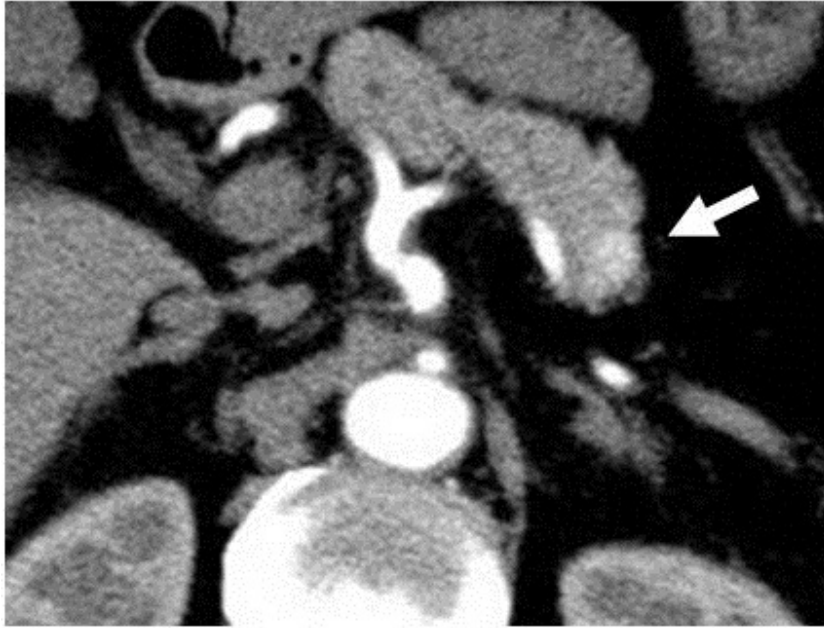

Figure 1. Contrast-enhanced CT scan of the 15-mm-diameter mass of the pancreatic body (arrow).

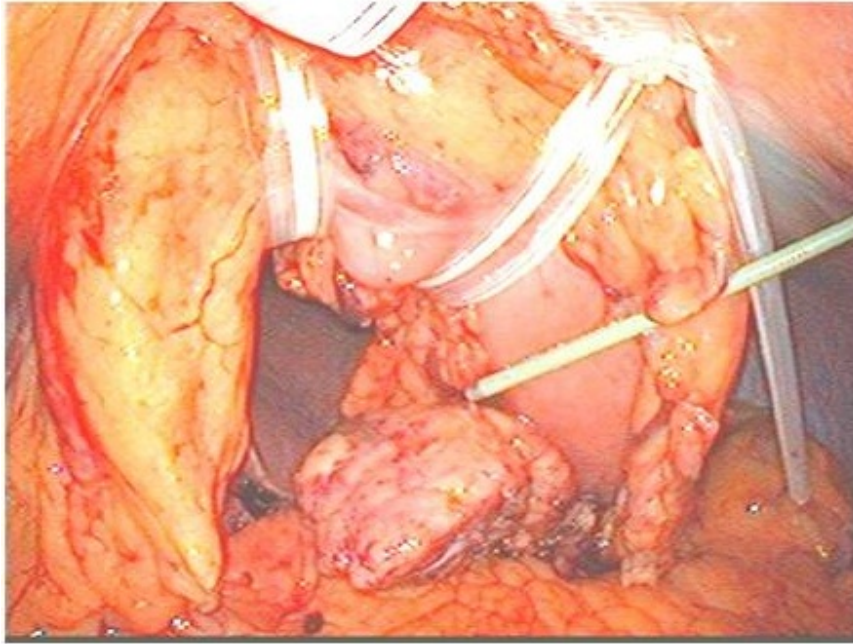


Figure 2. To expose the pancreas, the body of the stomach was fixed to the abdominal wall. We called this the stomach-hanging method.

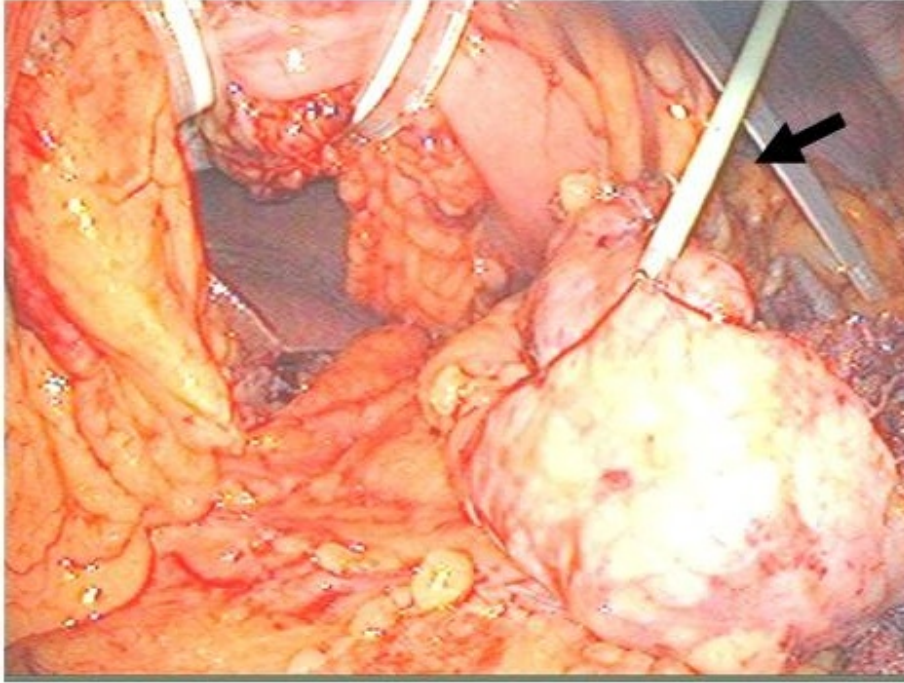


Figure 3. To retract the stump of the pancreas, it was tightened with the Mini-loop retractor II. The arrow indicates the Mini-loop retractor II.