

**Are there any similarities in the hepatic vascular anatomy among blood relatives?**

SATOSHI INOUE, SUSUMU EGUCHI, MITSUHISA TAKATSUKI, MASA AKI HIDA KA,

AKIHIKO SOYAMA, TETSUO TOMONAGA, IZUMI MURAOKA, and TAKASHI KANEMATSU

Department of Surgery, Nagasaki University Graduate School of Biomedical Sciences

1-7-1 Sakamoto, Nagasaki 852-8501, Japan

Tel: 81-95-819-7316, Fax: 81-95-819-7319, Email: [sueguchi@nagasaki-u.ac.jp](mailto:sueguchi@nagasaki-u.ac.jp)

*Offprint requests to:* Susumu Eguchi

Department of Surgery, Nagasaki University Graduate School of Biomedical Sciences

1-7-1 Sakamoto, Nagasaki 852-8501, Japan

E-mail: [sueguchi@nagasaki-u.ac.jp](mailto:sueguchi@nagasaki-u.ac.jp)

## **Abstract**

*Background/Purpose.* Whether or not similarities exist in the hepatic vascular anatomy among blood relatives (BR) has never been studied before. Since in living donor liver transplantation (LDLT), the donor may be a BR, an opportunity is available to assess whether there are similarities in the hepatic vascular anatomy among BR.

*Methods:* We conducted an analysis of 61 LDLT during the period from January 2004 to August 2008. Based on preoperative multidetector computed tomography data and in reference to the intraoperative findings, the hepatic arteries (HA) were classified into 4 groups, the portal vein (PV) was classified into 2 groups, and the right hepatic vein (RHV) was classified into 2 groups. The data of each group were then compared between BR (n=47) and NBR (n=14).

*Results:* With regard to the HA anatomy, 30 cases (68%) of the BR donor matched that of the recipient and 9 cases (69%). The PV anatomy was matched in 41 cases (87%) of BR donor and

11 cases (79%) in the NBR donor. The anatomy of the RHV was matched in 25 cases (53%) in the BR donor and 9 cases (64%) in NBR donor. There was no significant difference in all contexts.

*Conclusions:* No similarities were therefore observed in the hepatic vascular anatomy among

BR.

**Key words :** hepatic artery, anatomy, liver transplantation, consanguinity

## **Introduction**

There were several reports regarding the anatomy of hepatic vessels for safe hepatectomy or liver transplantation<sup>1-5</sup>. The question of whether there are similarities in hepatic vascular anatomy among blood relatives (BR) has never been studied before. In living donor liver transplantation (LDLT), the donor may be a blood relative (BR), such as a parent or a sibling, or a non-blood relative (NBR), such as a spouse. Therefore, this provides an opportunity for assessing whether there are similarities in hepatic vascular anatomy among BR. In this study, we took the opportunity to assess whether there are similarities in hepatic vascular anatomy among BR.

## **Methods**

We conducted an analysis of 61 LDLT that had been performed at the Department of Surgery, Nagasaki University Graduate School of Biomedical Sciences, during the period from January 2004 to August 2008 (age range: 11–68 years; mean: 46 years).

Of these 61 cases, 47 cases (77%) constituted transplantations between BR, with the breakdown as follows: 36 cases (59%) between a parent and a child; 9 cases (15%) between siblings; and 2 cases (3%) between cousins. Another 14 cases (23%) were between NBR. Based on the data of preoperative MDCT (multidetector computed tomography) and in reference to the intraoperative findings, the hepatic arteries were classified into 4 groups (Aa: normal with the left and right hepatic arteries diverging from the common hepatic artery; Ab: the left hepatic artery diverging from the left gastric artery; Ac: the right hepatic artery diverging from the superior mesenteric artery; Ad: any other divergence abnormalities) (Fig.1), the portal veins were classified into 2 groups (Pa: normal with absence of precocious bifurcation into posterior branches ; Pb: the presence of precocious bifurcation into posterior branches) (Fig.2), and the

right hepatic veins were classified into 2 groups (Va: the absence of neither an inferior right hepatic vein nor a right middle hepatic vein; Vb: the presence of either an inferior right hepatic vein or a right middle hepatic vein [larger than 5mm in diameter]) (Fig.3). The data of each group were then compared between BR and NBR in order to compare and assess any similarities in the vascular anatomy. The data regarding BR were also compared between first-degree BR and second- or other-degree BR.

## **Results**

### ***Hepatic Arteries(Table 1)***

With regard to transplantations between BR, there were 28 cases (59.6%) in Group Aa, 0 cases in Group Ab, 2 cases in Group Ac (4.2%), and 0 cases in Group Ad in which the hepatic arterial anatomy of the BR donor matched that of the recipient. With regard to transplantations between NBR, there were 9 cases in Group Aa (64.3%), 0 cases in Group Ab, 0 cases in Group Ac, and 0

cases in Group Ad in which the hepatic arterial anatomy of the NBR donor matched that of the recipient. With 30 cases (68%) in which the hepatic arterial anatomy of the BR donor matched that of the recipient and 9 cases (69%) in which the hepatic arterial anatomy of the NBR donor matched that of the recipient, there was no significant difference in the similarity of the hepatic arterial anatomy between BR and NBR ( $p=0.83$ ).

The comparison between BR showed that, with regard to transplantations between first-degree BR, there were 20 cases in Group Aa, 0 cases in Group Ab, 2 cases in Group Ac, and 0 cases in Group Ad in which the hepatic arterial anatomy of the first-degree BR donor matched that of the recipient. With regard to transplantations between second- or other-degree BR, there were 8 cases in Group Aa, 0 cases in Group Ab, 0 cases in Group Ac, and 0 cases in Group Ad in which the hepatic arterial anatomy of second- or other-degree blood relative donors matched that of the recipient. With 22 cases (65%) in which the hepatic arterial anatomy of the first-degree BR donor matched that of the recipient and 8 cases (72%) in which the

hepatic arterial anatomy of the second- or other-degree BR donor matched that of the recipient, there was no significant difference in similarities in hepatic arterial anatomy in terms of the difference in the degrees of BR ( $p=0.73$ ).

***Portal Vein (Table 2)***

There were 41 cases in Group Pa and 0 cases in Group Pb in which the portal venous anatomy of the BR donor matched that of the recipient. There were 11 cases in Group Pa and 0 cases in Group Pb in which the portal venous anatomy of the NBR donor matched that of the recipient. With 41 cases (87%) in which the portal venous anatomy of the BR donor matched that of the recipient and 11 cases (79%) in which the portal venous anatomy of the NBR donor matched that of the recipient, there was no significant difference in the similarities in portal venous anatomy between BR and NBR ( $p= 0.41$ ).

The comparison between BR showed that, with regard to transplantations between first-degree BR, there were 32 cases in Group Pa and 0 cases in Group Pb in which the portal



venous anatomy of the first-degree BR donor matched that of the recipient. With regard to LDLT between second- or other-degree BR, there were 9 cases in Group Pa and 0 cases in Group Pb in which the portal venous anatomy of the second- or other-degree BR donor matched that of the recipient. With 32 cases (89%) in which the portal venous anatomy of the first-degree BR donor matched that of the recipient and 9 cases in which the portal venous anatomy of the second- or other-degree BR donor matched that of the recipient, no significant difference was found in similarities in portal venous anatomy in terms of the difference in degrees of BR ( $p=0.61$ ).

***Right Hepatic Vein (Table 3)***

There were 20 cases in Group Va and 5 cases in Group Vb in which the anatomy of the RHV of the blood relative donor matched that of the recipient. There were 8 cases in Group Va and 1 case in Group Vb in which the anatomy of the right hepatic vein of the NBR donor matched

that of the recipient. With 25 cases (53%) in which the anatomy of the right hepatic vein of the blood relative donor matched that of the recipient and 9 cases (64%) in which the anatomy of the right hepatic vein of the NBR donor matched that of the recipient, there was no significant difference in the similarities in the anatomy of the right hepatic vein between BR and NBR ( $p: 0.67$ ).

The comparison between BR showed that, with regard to transplantations between first-degree BR, there were 13 cases in Group Va and 5 cases in Group Vb in which the anatomy of the right hepatic vein of the first-degree BR donor matched that of the recipient.

With regard to transplantations between second- or other-degree BR, there were 7 cases in Group Va and 0 cases in Group Vb in which the anatomy of the right hepatic vein of the second- or other -degree BR donor matched that of the recipient. With 18 cases (50%) in which the anatomy of the RHV of the first-degree blood relative donor matched that of the recipient and 7 cases (64%) in which the anatomy of the RHV of the second- or other-degree BR donor

matched that of the recipient, no significant difference was found in similarities in the anatomy of the RHV in terms of the difference in degrees of BR ( $p= 0.65$ ).

## **Discussion**

According to ontogeny, nutrition develops in 3 stages: (1) from the yolk sac, (2) from a mother via the umbilical vein, and (3) through the digestive tract via portal and hepatic veins. The liver has 2 blood inflows: one from the portal vein and the other from the umbilical vein. Hepatic veins later develop as part of an outflow route<sup>6</sup>.

The hepatic artery develops, after the creation of a portal vein, along the bile duct as a blood vessel that supplies the bile duct, and as such, it presents a clinical picture that is similar to that of a bile duct<sup>6,7</sup>. In the development of a hepatic artery, early in fetal life, the left hepatic artery is formed from the left gastric artery, the middle hepatic artery is formed from the celiac artery, and the right hepatic artery is formed from the superior mesenteric artery. It is believed that in most cases, the left, middle, and right hepatic arteries flow into the left outer region, the left and right paramedian regions, and the right outer region, respectively, and that the left and right hepatic arteries eventually atrophy and only the middle hepatic artery remains.

During the development of the portal vein, the dorsal communicating branch of the mesenteric vein of the left and right ovarian bursae eventually become the main portal vein. The point of connection between the main portal vein and the umbilical vein becomes the left portal vein. A factor that plays a decisive role in the distribution of the portal veins is the position of the main portal venous lacuna. It is believed that, when the main portal venous lacuna is found in the portal vein bifurcation or in the left portal vein, there is a high degree (90.32%) of abnormality in right portal vein bifurcation<sup>6</sup>.

With regard to hepatic veins, in most cases, the right hepatic vein develops from the shank of the mesenteric veins of the right ovarian bursa. The caudal section of the inferior vena cava, as well as the left hepatic vein and middle hepatic vein, develop from the descending branch of the right lateral lobe hepatic vein. Thereafter, as compensation for a short right hepatic vein, extra-wide right inferior and middle hepatic veins may develop along the inferior vena cava, which is a variation of the right hepatic vein<sup>6</sup>.

It is therefore believed that an anatomical variation could be explained from the perspective of ontogeny with respect to which blood vessel remains without atrophying<sup>1</sup>. In our study, we did not observe the similarity of hepatic vessels among blood relatives. LDLT is an opportunity available to assess whether there are similarities in the hepatic vascular anatomy among BR. The reason why our hypothesis did not reach any significant difference was unclear at this moment.

Each of the blood vessels is a variation that occurs during the process of development, possibly due to individual differences. It is therefore unlikely that consanguinity is involved in any observed similarities in the hepatic vascular anatomy. In conclusion, no similarities were observed in the hepatic vascular anatomy among blood relatives.

## References

1. Hiatt JR, Gabbay J, Busuttil RW. Surgical anatomy of the hepatic arteries in 1000 cases. *Ann Surg.* 1994;220:50-2.
2. Kishi Y, Imamura H, Sugawara Y, Sano K, Kaneko J, Kokudo N, et al. Evaluation of donor vasculobiliary anatomic variations in liver graft procurements. *Surgery.* 2009 Oct 29. (E-pub ahead of print)
3. Varotti G, Gondolessi GE, Goldman J, Wayne M, Florman SS, Schwartz ME, et al. Anatomic variations in right liver living donors. *J Am Coll Surg.* 2004;198:577-82.
4. Duffy JP, Hong JC, Farmer DG, Ghobrial RM, Yersiz H, Hiatt JR, et al. Vascular complications of orthotopic liver transplantation: experience in more than 4,200 patients. *J Am Coll Surg.* 2009; 208:896-903.
5. Chaib E, Bertevello P, Saad WA, Pinotti HW, Gama-Rodrigues J. The main hepatic anatomic variations for the purpose of split-liver transplantation. *Hepatogastroenterology.* 2007;54:688-92.

6. Couinaid C. Surgical anatomy of the liver revisited, Igaku-Shoin Ltd., Tokyo.

7. Lassau JP. L'organogénèse du foie. Contribution à l'étude de l'angioarchitecture hépatique.

Thèse, Paris 1966 hépatique. Thèse, Paris.



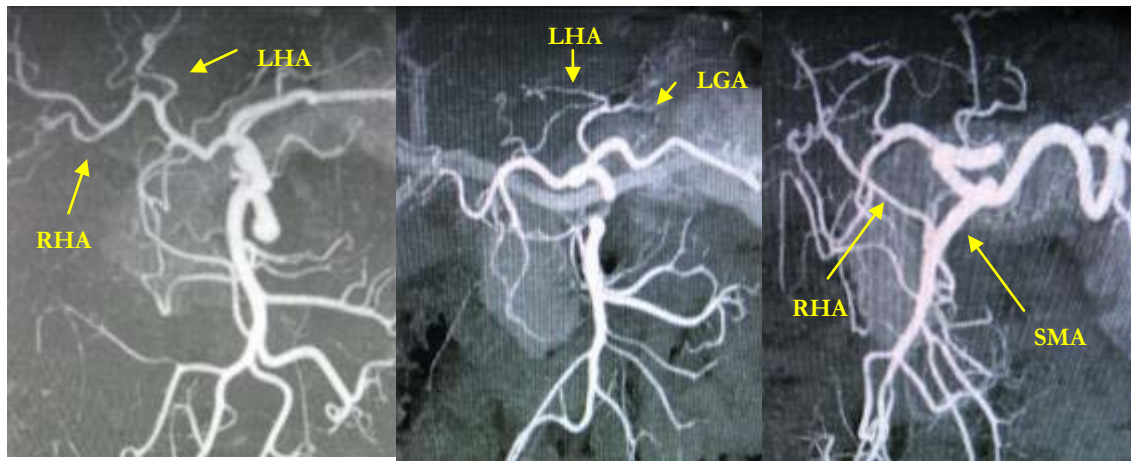
**Figure legend**

**Fig. 1.** Typical classification of hepatic arteries.

**Fig. 2.** Typical classification of portal veins.

**Fig. 3.** Typical classification of hepatic veins.

Fig.1 Classification of the hepatic artery



Left (Aa)

: normal type (Left and Right hepatic artery diverge from common hepatic artery)

Middle (Ab)

: Left hepatic artery (LHA) diverge from left gastric artery(LGA)

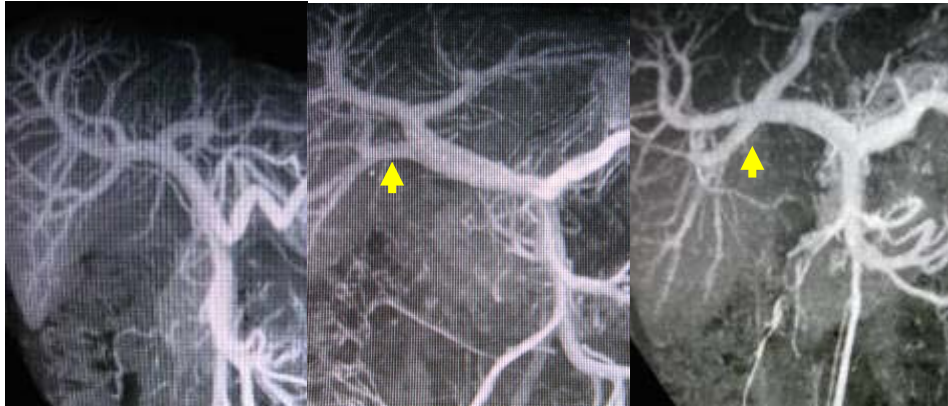Right (Ac)

: Right hepatic artery(RHA) diverge from superior mesenteric artery (SMA)

Any other (Ad )

: other than those above

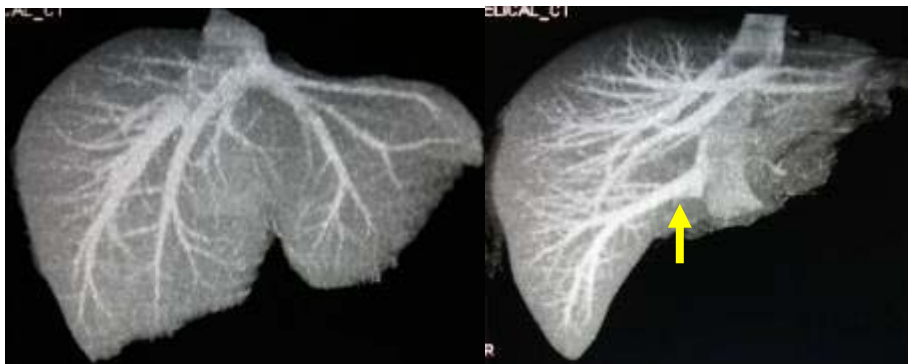
Fig.2 Classification of the portal vein



Left (Pa) : normal type

Middle & Right (Pb) : The presence of precocious bifurcation of posterior branch

Fig.3 Classification of the hepatic vein



Left (Va) : The absence of neither the inferior nor the middle right hepatic vein

Right (Vb) : The presence of either the inferior or the middle right hepatic vein

Table.1 Comparison of the hepatic artery anatomy

「Result」

related		donor				unrelated		donor			
		Aa	Ab	Ac	Ad			Aa	Ab	Ac	Ad
recipient	Aa	28	1	1	2	recipient	Aa	9	0	0	0
	Ab	2	0	0	0		Ab	1	0	0	0
	Ac	5	3	2	0		Ac	2	0	0	0
	Ad	1	0	0	0		Ad	0	0	1	0

「Comparison of the match of the hepatic artery anatomy with or without blood relationship」

	matched	unmatched	
related	30	15	P=0.87
unrelated	9	4	

「Comparison of the match of the hepatic artery anatomy among blood relationship」

	matched	unmatched	
relation in the first	22	12	P=0.73
relation over the second	8	3	

n : group

It shows no significant differences in the hepatic artery anatomy regardless of blood relationship

Table.2 Comparison of the portal vein anatomy

「Result」

		donor				donor	
		Pa	Pb			Pa	Pb
related	Pa	41	5	unrelated	Pa	11	1
	Pb	1	0		Pb	2	0

「Comparison of the match of the portal vein anatomy with or without blood relationship」

	matched	unmatched	
related	41	6	P=0.42
unrelated	11	3	

「Comparison of the match of the portal vein anatomy among blood relationship」

	Matched	unmatched	
relation in the first	32	4	P=0.61
relation over the second	9	2	

n : group

It shows no significant differences in the portal vein anatomy regardless of blood relationship

Table.3 Comparison of the hepatic vein anatomy

「Result」

		donor				donor	
		Va	Vb			Va	Vb
related	recipient Va	20	18	unrelated	recipient Va	8	4
	recipient Vb	4	5		recipient Vb	1	1

「Comparison of the match of the hepatic vein anatomy with or without blood relationship」

	matched	unmatched	
related	25	22	P=0.67
unrelated	9	5	

「Comparison of the match of the hepatic vein anatomy among blood relationship」

	matched	unmatched	
relation in the first	18	18	P=0.65
relation over the second	7	4	

n : group

It shows no significant differences in the hepatic vein anatomy regardless of blood relationship