

Case Report

Endovascular Treatment of a Carotid Artery Pseudoaneurysm in a Contaminated Wound: Report of a Case

Nimpei YAMAGUCHI,¹ Kenichi KANEKO,¹ Tetsu IWANAGA,² Satoru KOMURO,³ Haruo TAKAHASHI¹

¹Department of Otolaryngology - Head and Neck Surgery, Nagasaki University Graduate School of Biomedical Sciences

²Department of Otorhinolaryngology Head and Neck Surgery, Nagasaki Municipal Hospital

³Komuro Otorhinolaryngology Clinic

We herein report a case of carotid artery pseudoaneurysm following intensive treatment for hypopharyngeal carcinoma. An 81-year-old male had undergone surgery and concurrent chemoradiotherapy to treat hypopharyngeal carcinoma (T4aN1M0). This treatment led to a complete response, but pseudoaneurysms were formed at the external carotid artery in a contaminated wound. One of the pseudoaneurysms was located close to the bifurcation and thus caused intractable hemorrhaging. We performed endovascular treatment to achieve hemostasis. One year after the embolization, surgical removal of the endovascular devices from the infected area was performed. Three years have passed since the removal, and the patient is still alive without any complications. Primary endovascular treatment of an infected pseudoaneurysm could be an effective option for the treatment of acute lethal hemorrhaging.

ACTA MEDICA NAGASAKIENSIA 57: 65 - 68, 2012

Keywords: Pseudoaneurysm; carotid artery

Introduction

The formation of a carotid artery pseudoaneurysm is a rare, potentially lethal complication after intensive treatment for head and neck cancer. A pseudoaneurysm without infection is currently treated by endovascular intervention with a stent and detachable coils. To date, few reports on the endovascular management of infected carotid artery pseudoaneurysm have been documented.

In this article, we describe a rare case that was successfully treated by transcatheter arterial embolization of an infected carotid artery pseudoaneurysm.

Case Report

An 81-year-old male had undergone a right neck dissection to treat hypopharyngeal carcinoma (T4aN1M0). Concurrent chemoradiotherapy (total dose of 60 Gy and 100 mg of docetaxel) had been performed after the surgery, which had led to complete response. However, the tumor recurred in the hypopharynx. The patient consequently underwent a total pharyngolaryngectomy and reconstruction with a microvascular jejunal graft. After the surgery, the anterior skin of neck had become necrotic. Therefore, reconstruction with a left pectoral major musculocutaneous flap (PMMF) was performed. Postoperatively, a minor salivary fistula had formed around the PMMF. It took 2 months to close the fistula by means of local conservative treatment, and thereafter he

Address correspondence: Nimpei Yamaguchi, Department of Otolaryngology - Head and Neck Surgery, Nagasaki University Graduate School of Biomedical Sciences 1-7-1, Sakamoto, Nagasaki 852-8501, Japan
Phone: +81-95-819-7349, Fax: +81-95-819-7352, E-mail: y-nimpei@nagasaki-u.ac.jp

Received March 15, 2012; Accepted April 3, 2012

was successfully discharged.

One week after leaving the hospital, the patient was readmitted with occult hemorrhaging in the mouth. Pharyngoscopy revealed a pharyngeal hemorrhage from an unknown origin. A pulsatile mass was recognized through the thick PMMF. Three-dimensional CT demonstrated two pseudoaneurysms of the right external carotid artery (ECA) that measured 3 cm and 1.5 cm in diameter (Figure 1). The proximal one was located close to the bifurcation.

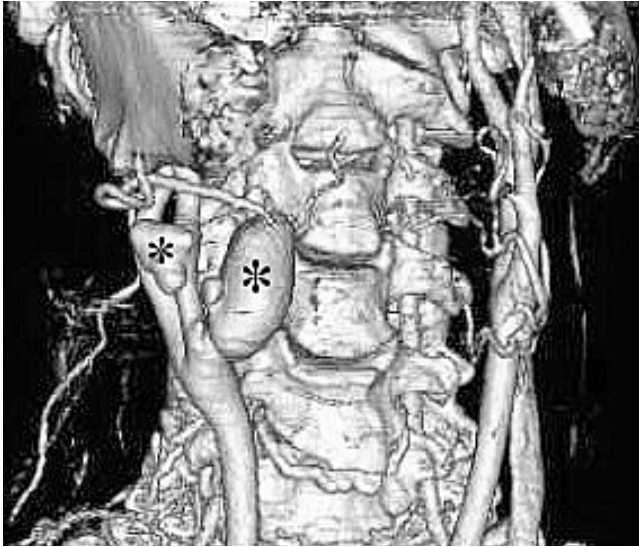


Figure 1. A three-dimensional CT image of two pseudoaneurysms (asterisk) located in the right external carotid artery (ECA).

After the CT, the patient suddenly developed intractable hemorrhaging from the hypopharynx and went into hypovolemic shock. An angiographic examination revealed that the proximal larger pseudoaneurysm had ruptured into the hypopharynx. A 9×35 mm wire braided stent (Wallstent RP) was placed between the right internal carotid artery (ICA) and common carotid artery (CCA) to prevent migration of the coils to the right ICA. 41 detachable coils (Vortex $3 \times 5\sim 40$ mm, Tornade 4~8 mm, IDC 7~20 \times 20 mm, GDC 7~8 \times 30 mm, Nestor 6 \times 14 mm) were then inserted into the aneurysm sac and the right ECA through the stent. A part of the coil remained in the ICA. A 10×20 mm wire braided stent (Wallstent RP) was placed in the former stent to exclude the remaining part of the coil. After this series of procedures, the ECA and pseudoaneurysm were completely embolized. The arterial flow in the right ICA was well preserved (Figure 2).

One day after the embolization, minor hemorrhage to the neck appeared again. Compression hemostasis was not effective. Three days after the embolization, a balloon carotid occlusion test was performed and showed that he could

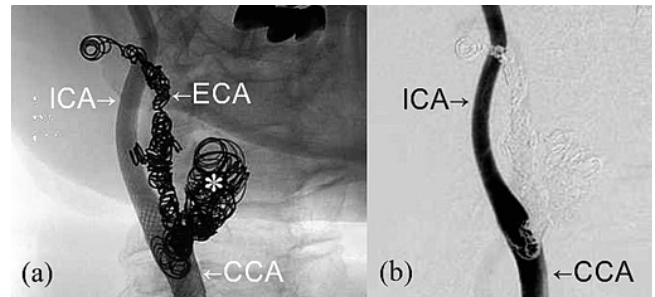


Figure 2. An angiographic image of the right carotid system. (a) Unsubtracted view shows a mesh stent was placed between the common carotid artery (CCA) and the internal carotid artery (ICA). Detachable coils were placed at the aneurysm sac (asterisk), the external carotid artery (ECA). (b) Subtracted view shows the arterial flow in the right ICA was well preserved.

tolerate permanent carotid occlusion. Because of the severe tissue adhesion due to previous irradiation and surgery, we attempted a transcatheter embolization of the right CCA and ICA instead of their surgical ligation. 25 detachable coils (Trufill 6~7 mm, Nestor 6 \times 14 mm, Vortex 3 \times 5~7 mm, Tornade 4~8 mm) were then placed from the right CCA to the ICA (Figure 3). Finally, complete hemostasis was achieved without any neurological deficits. As the pseudoaneurysm had already ruptured into the hypopharynx, there was significant potential for a secondary infection to develop around any endovascular devices. The patient therefore received intravenous injection of 4.5g/day of sultamicillin tosilate and 1200 mg/day of clindamycin for two weeks to control secondary infections. Three months after being readmitted to the hospital, he was discharged without any complications.

However, a cervical infection subsequent to transcatheter

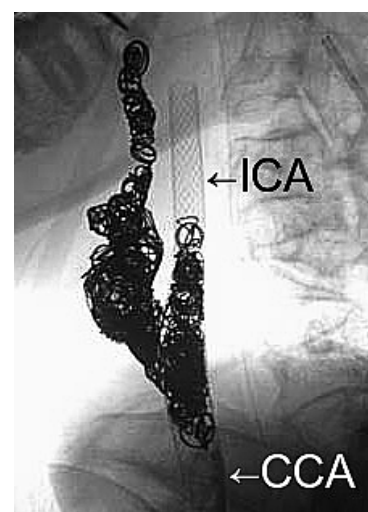


Figure 3. An angiographic image of the post-occluded right carotid system. Detachable coils were placed at the aneurysm sac, the external carotid artery, the common carotid artery (CCA) and the internal carotid artery (ICA).

embolization could not be controlled, and recurred. Ten months after leaving the hospital, secretion of the pus from the former bleeding point of the neck appeared. MRI revealed abscess formation around the endovascular devices (Figure 4). Culture of the pus showed *Pseudomonas aeruginosa*. Antibiotic therapy was not effective. We performed surgical removal of infected devices and ligation of the right CCA, ICA and ECA. We could not remove the distal part and proximal part of the stent because of a high risk of re-bleeding. Surgical wound healing was prevented by the tissue ischemia produced from the previous irradiation. We used hyperbaric oxygen therapy for two weeks to activate the healing process, but failed to induce sufficient healing. Therefore, reconstruction surgery with a right PMMF was performed one month after the surgery. Finally, the wound healed after the operation. As of the three year follow-up examination, the patient has remained tumor free without any further complications.

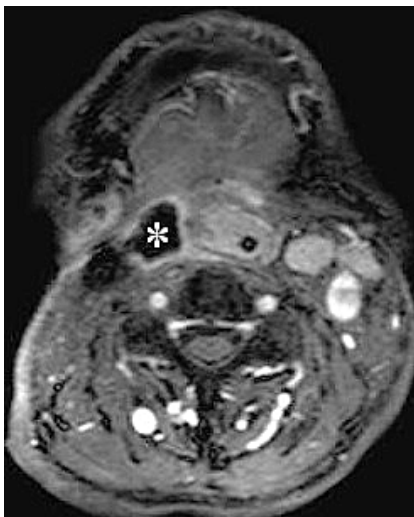


Figure 4. A contrast-enhanced MRI image fourteen months after the embolization shows abscess formation (asterisk) with ring-enhancement.

Discussion

A pseudoaneurysm of the carotid artery is one of the serious complications of intensive treatment for head and neck cancers, including chemoradiotherapy and surgery. Since such intensive measures have recently become one of the established treatments for advanced head and neck carcinomas, mainly since they allow for organ preservation, the incidence of such pseudoaneurysms of carotid artery have thus been observed to occur with an increasing frequency. Radiation therapy induces vascular injury and damages the

ability of the tissue to heal from injury spontaneously.¹ As endovascular treatment is effective for controlling acute lethal bleeding of pseudoaneurysms without sacrificing the internal carotid artery, it is therefore sometimes utilized to treat non-infected carotid aneurysms. However, no generalized strategy has yet been established to treat infected carotid artery aneurysms. The major problem associated with these aneurysms is the difficulty in controlling the infection around the endovascular devices, and the presence of such infection is a risk factor for re-bleeding.² It is known that the parent artery of the aneurysm has to be isolated to prevent rebleeding. However, performing the primary embolization of the common or internal carotid artery without evaluating the collateral cerebral circulation can result in major neurologic morbidity and mortality.

In the current case, the pseudoaneurysm was thought to have developed as a result of infection through the minor salivary fistula formed after the previous surgery. For the initial endovascular treatment, we could not select embolization of the CCA and ICA without performing the balloon carotid occlusion test. We achieved hemostasis, however, by carrying out two staged endovascular treatments.

We judged a surgical reconstruction of the carotid system to be extremely hazardous and thus instead chose endovascular occlusion. Another method to stop bleeding without interruption of the carotid artery (CA) flow is to place a covered stent on the diseased CA. However, Chang et al reported that the mean duration of stent graft patency was just 3.0 ± 2.6 months.³ In the current case, we could not use a covered stent because it was not approved by the Japanese Health Insurance System and there was no available device.

The infection around the endovascular devices was not controlled by the antibiotic therapy. We had performed hyperbaric oxygen therapy and reconstruction by a well-vascularized flap following the removal of the infected devices. Goddard et al. recommended direct surgery rather than endovascular treatment of infected pseudoaneurysm.⁴ However, in the current case, treatments that were performed on infected pseudoaneurysms, including primary endovascular management, were able to prevent carotid blow out. Primary endovascular treatment of an infected pseudoaneurysm may therefore be an effective option therapeutic modality in cases of acute lethal hemorrhaging.

Acknowledgements

Nothing

References

1. Okamura H, Kamiyama R, Takiguchi R, et al. Histopathological examination of ruptured carotid artery after irradiation. *ORL* 64: 226-228, 2002
2. James C, Lonel R. Contemporary management of carotid blowout. *Curr Opin Otolaryngol Head Neck Surg* 12: 110-115, 2004
3. Chang FC, Lirng JF, Luo CB, et al. Patients with head and neck cancers and associated postirradiated carotid blowout syndrome: Endovascular therapeutic methods and outcomes. *J Vasc Surg* 47: 936-945, 2008
4. Goddard AJ, Lenthall RK, Bradley PJ. Endovascular management of infected carotid artery pseudoaneurysm complicating pharyngolaryngectomy: complete occlusion followed by early recurrence and rebleeding. *J Laryngol Otol* 118: 991-995, 2004