

Case Report

Laparoscopic Repair of a Ventral Hernia Using Composix E/X Dual Mesh at a Single Institution.

Shinichiro ONO, Yujo KAWASHITA, Kengo KANETAKA, Tohru IWATA

Department of Surgery, Nagasaki Rosai Hospital

Introduction: Although abdominal ventral hernias are common, there is still no consensus regarding the most appropriate technique to be used for surgical repair. We herein present our initial experiences of laparoscopic ventral herniorrhaphy to repair abdominal ventral hernias.

Patients: From April 2007 to March 2009, four patients were assigned to receive laparoscopic ventral hernia repair. The operative technique was demonstrated. Additionally clinical factors, including operative time, length of hospital stay, complications, and recurrence rates, were evaluated.

Results: All of the patients were successfully treated laparoscopically without conversion to open laparotomy. The median operative time was 107.5 (range 75 - 130) minutes and the mean length of hospital stay was 13 (range 5 -19) days. There were no significant complications or hernia recurrences during a follow-up period of 36 months (median, 28 - 42).

Conclusion: Laparoscopic repair of abdominal ventral hernias may therefore be a feasible option with a great potential to both improve treatment outcomes and reduce surgical morbidity.

ACTA MEDICA NAGASAKIENSIA 57: 49 - 52, 2012

Keywords: ventral hernia, laparoscopic ventral hernia repair

Introduction

Abdominal ventral hernias are common complications following abdominal surgery. In long-term follow-up studies, primary ventral hernias occurred in 11% to 20% of cases¹. The optimal method of hernia repair is one of the most analyzed and debated topics; however, there is no consensus regarding the most appropriate surgical technique. Although a wide variety of open surgical techniques have been performed, it has been proven that the use of mesh is superior to direct suture methods².

Laparoscopic surgery was initially established as a treatment for cholecystectomy. Since then, improvements in laparoscopic instruments and surgeons' skills have expanded

the use of laparoscopic surgery to various fields, including ventral hernias.

In the present report, we describe the efficacy of laparoscopic repair of abdominal ventral hernias using dual mesh comprised of two membranes based on experiences in our institution.

Patients and methods

Patients

From April 2007 to March 2009, four patients with abdominal incisional hernias underwent laparoscopic repair using mesh. Those patients with hernias concomitantly having either

Address correspondence: Shinichiro Ono

Department of Surgery, Nagasaki Rosai Hospital, 2-12-5 Setogoshi, Sasebo city, Nagasaki, Japan, Zipcode: 857-0134

Tel: +81-956-49-2191, Fax:+81-956-49-2358, E-mail: shinichi0320_com@yahoo.co.jp

Received February 14, 2012; Accepted May 23, 2012

Table 1. Summary of patient's characteristics

Case	1	2	3	4
gender	M	F	F	M
age	51	78	86	80
first surgery	distal gastrectomy	hysterectomy	ileocecal resection	choledocholithotomy
hernia size (cm)	8 × 10cm	6 × 6cm	5 × 5cm	8 × 9cm
location	epigastrium	hypogastrium	right flank	epigastrium
BMI	25.2	26.4	21.5	22.4
operation time (min.)	230	75	140	75
wound pain	slight	slight	slight	slight
complication	none	none	none	none
hospital stay	5	12	14	19
recurrence	none	none	none	none
follow up period (month)	26	17	24	31

intestinal obstruction or extremely complicated intestinal adhesions were excluded from the consideration for this procedure. The characteristics of the patients are summarized in Table 1.

Operative procedure

The patients were placed in a supine position and given general anesthesia. They received prophylactic antibiotics (cephalosporin) prior to surgery. A camera port was created as far as possible laterally from the hernial edge using an open abdominal access technique. Two other ports were inserted under direct visualization using a 30-degree angle scope, as part of forming a coaxial set up. The first surgical

step was lysis of the adhesions using ultrasonic surgical shears (Sonosurg[®], Olympus) and monopolar scissors (Fig. 1). The hernial contents were removed in order to identify the exact margin of the defects (Fig. 2). A suitable size of mesh (Bard[®] composix E/X[®] mesh) was selected by examining the size of the hernial defect. Bard composix E/X mesh is composed of different materials on two side. One side is made of polypropylene to promote tissue ingrowth, and the other side is composed of sub-micronic ePTFE to minimize adhesions to the prosthesis. The mesh was rolled, inserted into the peritoneal cavity, and placed on the hernial defect (Fig. 3). After the mesh was positioned, it was fixed to the peritoneum and posterior fascia using Protak titanium spiral tackers (Autosuture Protak[®] 5 mm; Tyco Healthcare,

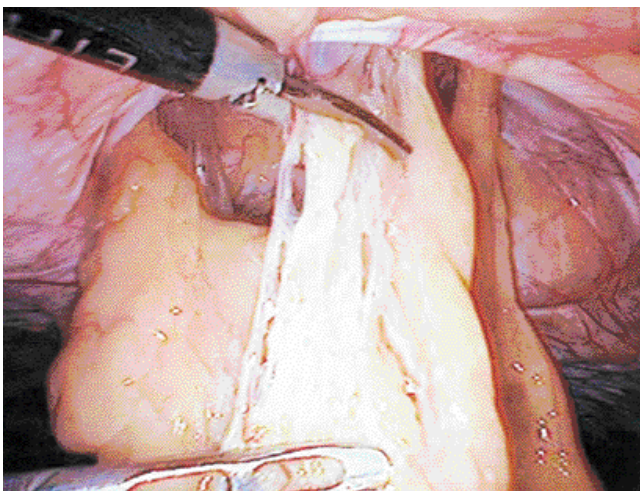


Figure 1. Lysis of adhesions of the greater omentum using ultrasonic surgical shears.(Sonosurg[®], Olympus)

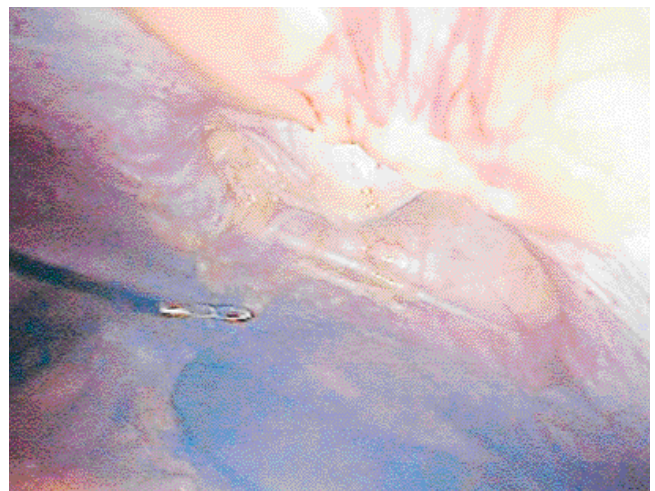


Figure 2. The hernial contents were removed. We confirmed the exact margin of the defects.

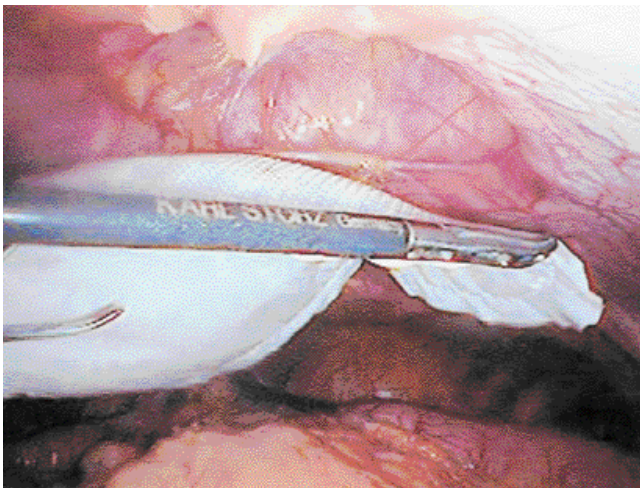


Figure 3. We used a suitable size of mesh (Bard[®] composix E/X[®] mesh) that coordinated with the size of the defects. The mesh was rolled, inserted into the peritoneal cavity, and placed on the hernial defects.

Norwalk, Conn., USA). The space between each tacker measured 1cm. (Fig. 4). Drains were not inserted. The median operative time was 107.5 (range, 75 - 130) minutes. The operation time depended on the degree of adhesion. Intraoperative blood loss was negligible in all cases.

Post-operative course

The post operative course for each patient was uneventful and without any significant wound pain or early recurrence. All patients resumed a normal diet and were able to walk comfortably on the first day after the operation. The median hospital stay was 13 (range, 5 -19) days. There were no significant complications and no hernia recurrences during a follow-up period of 36 (median, 28 -42) months.

Discussion

This study shows the benefits, based on our experience, of laparoscopic repair of abdominal ventral hernias using composix dual mesh. In particular, this study emphasize the method's simplicity, low invasiveness, and possibly low rate of postoperative complications, such as infection or recurrence.

In this study we employed a transabdominal laparoscopic approach due to the difficulty of dissecting the extraperitoneal space so that the mesh can be placed in a suitable position. Transabdominal laparoscopic repair of ventral hernias has already been performed with favorable outcomes by several

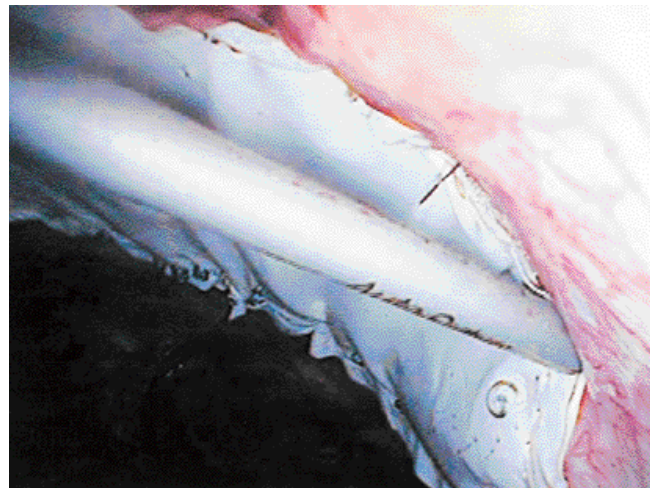


Figure 4. We fixed the mesh to the peritoneum and posterior fascia using spiral tackers (Protac[®], Tyco. Healthcare Japan). Tackers were placed 1cm apart.

medical centers^{3,4,5}, however, there is no consensus regarding the choice of a standard procedure for repairing abdominal ventral hernias. The lack of consensus is likely related several factors, including the technical difficulty of performing adhesiolysis using laparoscopic approach, the high cost of instruments, and uncertainty regarding long-term results. Direct suture repair of hernial defects will create significant tension around the edges that leads to a high rate of recurrence^{6,7}. In contrast, laparoscopic mesh repair is completely free of tension, which results in lower recurrence rates².

Compared with the direct suture method, the laparoscopic approach seems to have significant advantages, including: (1) the exact location of the hernia can be confirmed based on direct observation of the abdominal cavity, (2) the defect can be repaired with mesh transabdominally, (3) lysis of the fascia is not needed, (4) there is less risk of surgical site infection, (5) patients experience less wound pain, and (6) a quick return to normal daily life is possible.

The degree of difficulty of this procedure largely depends on the extent of adhesion between the bowel and abdominal wall, making the technique of adhesiolysis important. Since bowel injury makes the use of artificial materials difficult, it is desirable that adhesiolysis be performed by skilled laparoscopic surgeons. Additionally, patients should be selected after an intensive assessment of the intestinal adhesion using ultrasonography and/or computed tomography^{8,9}. However, no such assessment was performed in the present study. Another concern regarding the use of mesh involves biocompatibility with alloplastic prostheses. Although complications, such as infections, seromas, or recurrence, were

not documented in the present study, the risk of complications needs to be evaluated with further study.

To avoid postoperative complications, patients with intestinal obstruction and/or extremely complicated intestinal adhesions should be excluded from receiving laparoscopic repair. The mesh should be fixed properly, otherwise hernia recurrence, bowel obstruction due to adhesion, or detachment of the mesh can develop. Another postoperative complication that can occur is wound pain. We used 5mm spiral tackers to fix the mesh to the hernia cavity. Several studies have reported that tacker fixation requires shorter operation time compared with suture fixation; however patients who receive tacker fixation have significantly higher pain^{10,11,12}. The most common sequelae was early seroma formation¹³. In this study, patients experienced no postoperative pain or seroma formation. This may be due to the small number of cases included. We think that it is necessary to collect additional cases.

In conclusion, laparoscopic repair using composix mesh could be a feasible option for abdominal incisional hernias due to the simplicity of methods, lower incidence of pain, and favorable outcomes in selected patients.

References

1. Mudge M, Hughes LE. Incisional hernia: a 10 year prospective study of incidence and attitudes. *Br J Surg* 72: 70-1, 1985
2. Luijendijk RW, Hop WC, van den Tol MP et al. A comparison of suture repair with mesh repair for incisional hernia. *N Engl J Med* 343: 392-8, 2000
3. Chan JW, Chiu PW, Ng EK. Simultaneous laparoscopic totally extraperitoneal repair for concurrent ipsilateral spigelian and indirect inguinal hernia. *Surg Laparosc Endosc Percutan Tech* 18: 414-6, 2008
4. Bartsich SA, Schwartz MH. Deepithelialization of a complex ventral hernia for completely extraperitoneal Rives-Stoppa herniorrhaphy. *Hernia* 9: 280-3, 2005
5. Chowbey PK, Sharma A, Khullar R, Soni V et al. Laparoscopic ventral hernia repair with extraperitoneal mesh: surgical technique and early results. *Surg Laparosc Endosc Percutan Tech* 13: 101-5, 2003
6. Read RC, Yoder G. Recent trends in the management of incisional herniation. *Arch Surg* 124: 485-8, 1989
7. Anthony T, Bergen PC, Kim LT et al. Factors affecting recurrence following incisional herniorrhaphy. *World J Surg* 24: 95-100, 2000
8. Donckier V, Closset J, Van Gansbeke D et al. Contribution of computed tomography to decision making in the management of adhesive small bowel obstruction. *Br J Surg* 85: 1071-4, 1998
9. Hsu WC, Chang WC, Huang SC et al. Visceral sliding technique is useful for detecting abdominal adhesion and preventing laparoscopic surgical complications. *Gynecol Obstet Invest* 62: 75-8, 2006
10. Virinder Kumar Bansal, Mahesh C. Misra, Subodh Kumar et al. A prospective randomized study comparing suture mesh fixation versus tacker mesh fixation for laparoscopic repair of incisional and ventral hernias. *Surg Endosc* 25: 1431-8, 2010
11. Ivan Arteaga-Gonzalez, Antonio Martin-Malagon, Endaldo Miguel Lopez-Tomassetti Fernandez et al. Which patients benefit most from laparoscopic ventral hernia repair? A comparative study. *Surg Laparosc Endosc Percutan Tech* 20: 391-4, 2010
12. Vrinder Kumar Bansal, Mahesh C. Mirsa, Subodh Kumar et al. A prospective randomized study comparing suture mesh fixation versus tacker mesh fixation for laparoscopic repair of incisional and ventral hernias. *Surg Endosc* 25: 1431-38, 2011
13. A. Sharma, M. Mehrotra, R. Khullar et al. Laparoscopic ventral/incisional hernia repair: a single centre experience of 1,242 patients over a period of 13 years. *Hernia* 15: 131-9, 2011