

Original Paper

Experience of Surgical Resection for

Hilar Cholangiocarcinomas at a Japanese Single Cancer Institute

Atsushi Nanashima¹, Syuuichi Tobinaga¹, Takafumi Abo¹, Ryusuke Machino¹,

Hiroaki Takeshita¹, Takashi Nonaka¹, Shigekazu Hidaka¹, Kenji Tanaka¹,

Masaki Kunizaki¹, Terumitsu Sawai¹, Toru Yasutake¹, Takeshi Nagayasu¹

¹Division of Surgical Oncology, Department of Translational Medical Sciences, Nagasaki University Graduate School of Biomedical Sciences, 1-7-1 Sakamoto, Nagasaki 852-8501, Japan

Running title: Hepatectomy in hilar cholangiocarcinoma

Corresponding and reprint requests to: Atsushi Nanashima, M.D.

Division of Surgical Oncology, Department of Translational Medical Sciences,

Nagasaki University Graduate School of Biomedical Sciences,

1-7-1 Sakamoto, Nagasaki 852-8501, JAPAN

Tel.: +81-95-819-7304 , Fax: +81-95-819-7306

E-mail: a-nanasm@nagasaki-u.ac.jp

ABSTRACT

Background/Aims: Surgical resection is a radical treatment option for hilar bile duct carcinoma (HBDC); however, it is still difficult to cure and postoperative morbidity is high at this stage.

Methodology: We examined the demographics, surgical records and outcome in 38 patients with hilar cholangiocarcinoma undergoing operation.

Results: Five patients (13%) underwent probe laparotomy because of peritoneal dissemination or liver metastasis. Of 33 patients, extended hemi-hepatectomy was performed in 32 patients. Postoperative complications were observed in 46% including hepatic failure in 3, and hospital death was observed in 4 patients. Advanced tumor stage more than stage III was observed in 23 patients. Curability of operation was A in 5 patients, B in 17, and C in 11 and postoperative adjuvant chemotherapy was administered in 24% including photodynamic therapy in 3. Tumor recurrence was observed in 41% of HBDC patients. The 3- and 5-year tumor-free survival was 38% and 10%, respectively and 3- and 5-year overall survival was 48% and 32%, respectively. By comparison with tumor stage or final curability, survival rates were not significantly different between groups.

Conclusions: Surgical resection is still the only curative treatment option to improve patient survival even in advanced stage HBDC.

KEYWORDS: hepatectomy, pancreatoduodenectomy, hilar bile duct carcinoma radical resection

ABBREVIATIONS: Hilar bile duct carcinomas (HBDC), hepatopancreatoduodenectomy (HPD), percutaneous transhepatic biliary drainage (PTBD), preoperatively portal vein embolization (PVE), percutaneous biliary drainage tube (PTBD), endoscopic retrograde biliary drainage tube (ERBD),

INTRODUCTION

Surgical resection is the only curable treatment for hilar bile duct carcinomas (HBDC), and concurrent extended hepatectomy or hepatopancreatoduodenectomy (HPD) is necessary to accomplish complete (R0) resections, which may be associated with good patient prognosis (1-4). The resectability of hepatobiliary malignancies has markedly improved with the improvement of operative techniques and the introduction of preoperatively portal vein embolization (PVE) (5, 6). However, physical stress in patients is relatively severe and postoperative morbidity and mortality rates are still not low (1, 3, 6-8). Therefore, the indication of operation for HBDC should be carefully decided. In the present report, we examined our series of HBDC in 38 patients at a Japanese single cancer institute and discuss the clinical status and problems.

METHODOLOGY

Patients

We analyzed 38 patients with HBDC who underwent operation in the Division of Surgical Oncology, Department of Translational Medical Sciences, Nagasaki University Graduate School of Biomedical Sciences (NUGSBS) between 1997 and 2008. The study design was approved by the Human Ethics Review Board of our institution. Informed consent for data collection was obtained by each patient during this period. Anesthetic and patient data were retrieved in the NUGSBS database. Tumor stage and curability was

followed by the *Classification of Biliary Tract Carcinoma by the Japanese Society of Biliary Surgery* (9).

Operative indications, procedures and follow-up

Extended hepatectomy is a basic surgical option for HBDC with Bismuth type III and IV. Hepatopancreaticoduodenectomy (HPD) is necessary in cases where HBDC is widely extended to the bile duct in the pancreatic head. Even in cases with remarkable metastatic lymph node at para-aortic lesion, complete (=radical) resection with extended lymphadenectomy was performed. In cases with liver metastasis, peritoneal dissemination, or more distant metastasis, radical operation was avoided. In cases with good general conditions and liver function, radical operation was carried out but the border of patient age was not decided. Right or left hemi-hepatectomy was a basic option, which included resection of the total caudate lobe and extra-hepatic bile duct.

Extension of carcinoma along the bile duct was preoperatively diagnosed by precise cholangiography via percutaneous biliary drainage tube (PTBD) or endoscopic retrograde biliary drainage tube (ERBD), contrast multi-detector row computed tomography, and magnetic resonance cholangiography. In liver resection, the volume to be resected was estimated preoperatively based on the results of indocyanine green retention rate at 15 minutes using Takasaki's formula (10). The liver volume, excluding tumor volume (cm³), was measured by CT volumetry (11). We routinely clamped the hepatoduodenal ligament to occlude total inflow to the liver during transection. We also

routinely used the forceps fracture method (12) and an ultrasonic dissector (USU MH-207, Olympus, Tokyo, Japan) for the transection of liver parenchyma. Since 2004, we have determined liver function by ^{99m}-technetium galactosyl serum albumin (GSA) liver scintigraphy and functional liver volume by single photon emission computed tomography (SPECT)-CT fusion image (13). In patients needing pancreatic resection, pancreatoduodenectomy (PD) was usually performed in case of HPD. Pancreatic functions were not considered as operative indications.

After discharge from hospital, the patient status, laboratory data, and disease recurrence were carefully checked every 3 months. Minimum follow-up period after operation was 12 months.

RESULTS

Patients included 6 men and 5 women with a mean age of 67.5 ± 8.0 years (\pm SD, range, 44-83 years). Male-female ratio was 23 vs. 15. Preoperative PVE was performed in 9 patients (24%) for right hepatectomy or right trisectionectomy.

Five patients (13%) underwent probe laparotomy due to peritoneal dissemination in 4 patients and liver metastasis in 1. The remaining 33 patients underwent left hepatectomy in 15 patients, right hepatectomy in 6, right HPD in 3, left HPD in 3, right trisectionectomy in 3, left trisectionectomy in 2 and resection of segment 4a and segment 5 in 1. Postoperative complications were observed in 18 patients (46%) including bile leak at hepaticojejunostomy in 5, hepatic failure in 3, wound infection in 3, long-term hyper-bilirubinemia in 2, long-term ascites in 2, pancreatic fistula at pancreaticojejunostomy in 1, hepatic arterial thrombosis in 1, and severe pneumonia in 1. Hospital death was observed in 4 patients (12%) due to hepatic failure in 3 and hepatic arterial thrombosis in 1.

Final tumor stage was I in 1, II in 9, III in 8, IVa in 11 and IVb in 4. Final curability of operation was A in 5 patients, B in 17, and C in 11 (due to positive cancer margin at proximal (hepatic) cut end in 5 patients, at distal (bile duct) cut end in 2, and at dissected periductal structures in 4. Postoperative adjuvant chemotherapy was performed in 8 patients (24%) including photodynamic therapy at proximal (hepatic) cut end in 3 patients.

Except patients with hospital death, in 12 of 29 patients (41%), tumor recurrence was observed, which included peritonitis carcinomatosa in 5 patients, liver metastasis in 4, local recurrence in 4, and para-aortic lymph node metastasis in 1. Eighteen patients died after operation, which included cancer-related death in 11 (33%), other disease in 2, and portal thrombosis at 3 months in 1.

Figures 1 and 2 show the tumor-free and overall survival after operation in 29 patients without hospital death. Mean tumor-free survival was 29 months, and 3- and 5-year survival was 38% and 10%, respectively. By comparison with tumor stage, 3-year tumor-free survivals were not significantly different between stages (100% in I, 27% in II, 33% in III, 44% in IVa and b, $p=0.64$). By comparison with final curability, 3-year tumor-free survivals were not significantly different between groups either (50% in A, 35% in B, 66% in C, $p=0.38$). Mean tumor-related overall survival was 40 months, and 3- and 5-year survival was 48% and 32%, respectively. By comparison with tumor stage, 3-year tumor-related overall survival was not significantly different between stages (100% in I, 49% in II, 53% in III, 38% in IVa and b, $p=0.85$). By comparison with final curability, 3-year tumor-related overall survival was not significantly different between groups either (80% in A, 55% in B, 43% in C, $p=0.32$).

DISCUSSION

Nowadays, aggressive surgical exploration for HBDC combined with hepatic resection, resection of total caudate lobe, and extrahepatic bile duct is usually performed (1-4). As the techniques and perioperative management have remarkably improved, we have actively performed major hepatic resections for complete tumor resections (R0) during the last 15 years. Based on previous reports, the usefulness of R0 resection for HBDC has been reported since the 1990s (1-4, 14-16).

In our series, the mean age of HBDC patients was similar to that in other reports (1,4, 17) and, as a modern trend, many patients were older than 70 years. Other reports showed that patients over 80 years can undergo this major surgery if the patient has no serious complications and a strong performance status (18, 19). Our series included an 83-year-old patient, and she had a good operative course. Preoperative PVE for a large volume of hepatectomy such as right hepatectomy or trisectionectomy has been widely applied, particularly in Japanese institutes at this stage (5, 6, 20, 21). By introduction of PVE, hepatic failure after major hepatectomy in HBDC patients significantly decreased, and our previous results also showed a good prognosis in patients who underwent right hepatectomy after PVE (22). A study of functional liver reserve in such patients showed the theoretical usefulness of preoperative PVE (23, 24).

Although resectability of HBDC has been improved, advanced carcinomas were still found at laparotomy (2,4,7), and 13% of HBDC patients were inoperable, despite the detailed preoperative image examinations in our series. PTBD might be one of the causes

of peritoneal dissemination and, therefore, ERBD is preferable for biliary drainage before surgery (25). In Western countries, preoperative biliary drainage jeopardized operative safety (26); however, non-drained liver showed remarkable deterioration of functional liver reserve (27). Therefore, the safety of hepatectomy must be examined, as well as patient safety. At this stage, extended hemihepatectomy might be predominantly performed because perioperative management has been improved and operative safety has been accomplished (7, 15, 16). In our series, most cases underwent major hepatectomy and limited hepatectomy was performed in only one case. Postoperative complications, particularly liver failure and mortality rate, occurred frequently in our series. Particularly in cases with vascular anastomosis of the hepatic artery, the operative indication must be carefully considered preoperatively. Although severe complications were considerable in cases of arterial infiltration, radical operation might be valuable (3). We attempted to evaluate functional liver volume by ^{99m}Tc galactosyl serum albumin liver scintigraphy (23, 27). More reliable evaluation of liver function and improvement of surgical technique or devices would be necessary to reduce postoperative complication rates. Cases with widely intramural extensions of bile duct carcinoma between the intra-hepatic bile duct and intra-pancreatic bile duct can be completely resected by HPD (7). Although HPD is still a high-level operation, HPD was performed to accomplish curative operation. At this stage, eventually, longer prognosis would be expected in bile duct carcinomas with wide extension by complete and aggressive resection.

By histological examinations, advanced tumors such as final stage III and IV were dominant in our series, as well as other reports (4,5,7,8,15,16). According to this result, radical operation as curability A was not common. In cases with remnant cancer cells at the surgical cut end, additional local treatment is necessary to avoid tumor relapse. In 3 patients with positive cancer margin at hepatic cut end, photodynamic therapy, which is a cancer-specific treatment (28), was performed after the operation and local tumor recurrence has not been observed in these patients. Recently, anti-cancer chemotherapy has been effective for unresectable HBDC (29, 30) and effectiveness of adjuvant chemotherapy can be expected. In our series, TS-1 (Taiho Pharmaceutical Company, Tokyo, Japan), a novel oral fluoropyrimidine anticancer drug for gastric carcinomas (31), was used in stage IVa HBDC patients who had no tumor recurrence for 2 years, and the long-term administration was well tolerated. At this stage, tumor relapse was frequent despite aggressive resections in our series. Further long-term follow-up with adjuvant chemotherapy is necessary and development of effective anti-cancer drugs will be expected to improve patient survival.

In the present study, survival rate after hepatectomy was not satisfactory compared to the 50% survival rates in other reports (2, 32). Tumor stage and curability were not associated with patient survival in the present study. In advanced stage HBDC, 40% of patients achieved a 3-year survival. Therefore, even in cases of stage IVa and b, surgical resection would be promising and only a radical treatment option.

In conclusion, major surgical resection by major hepatectomy with caudate resection and extra-hepatic bile duct was performed in 33 patients with hilar bile duct carcinomas at a single cancer center over the past 15 years. Radical operation could be safely performed in many cases but 4 patients had hospital stay death at this stage. Although advanced stage HBDC and operations of low curability were not few, a relatively good prognosis could be obtained after surgery. Therefore, the indication of hepatectomy or hepatopancreaticoduodenectomy should be considered for widely extensive bile duct cancer for radical treatment. Surgical resection has been still only a curative option and newly effective adjuvant chemotherapy will be expected to improve patient survival.

REFERENCES

1. **Ito F, Cho CS, Rikkers LF, Weber SM:** Hilar cholangiocarcinoma: current management. *Ann Surg.* 2009;250:210-218.
2. **Jonas S, Benckert C, Thelen A, Lopez-Hänninen E, Rösch T, Neuhaus P:** Radical surgery for hilar cholangiocarcinoma. *Eur J Surg Oncol.* 2008;34:263-271.
3. **Miyazaki M, Kato A, Ito H, Kimura F, Shimizu H, Ohtsuka M, Yoshidome H, Yoshitomi H, Furukawa K, Nozawa S:** Combined vascular resection in operative resection for hilar cholangiocarcinoma: does it work or not? *Surgery.* 2007;141:581-588.
4. **Jarnagin WR, Fong Y, DeMatteo RP, Gonen M, Burke EC, Bodniewicz BS J, Youssef BA M, Klimstra D, Blumgart LH:** Staging, resectability, and outcome in 225 patients with hilar cholangiocarcinoma. *Ann Surg.* 2001;234:507-517.
5. **Yokoyama Y, Nagino M, Nishio H, Ebata T, Igami T, Nimura Y:** Recent advances in the treatment of hilar cholangiocarcinoma: portal vein embolization. *J Hepatobiliary Pancreat Surg.* 2007;14:447-454.
6. **Seyama Y, Makuuchi M:** Current surgical treatment for bile duct cancer. *World J Gastroenterol.* 2007;13:1505-1515.
7. **Kondo S, Takada T, Miyazaki M, Miyakawa S, Tsukada K, Nagino M, Furuse J, Saito H, Tsuyuguchi T, Yamamoto M, Kayahara M, Kimura F, Yoshitomi H, Nozawa S, Yoshida M, Wada K, Hirano S, Amano H, Miura F; Japanese Association of Biliary Surgery; Japanese Society of Hepato-Biliary-Pancreatic**

- Surgery; Japan Society of Clinical Oncology:** Guidelines for the management of biliary tract and ampullary carcinomas: surgical treatment. *J Hepatobiliary Pancreat Surg.* 2008;15:41-54.
8. **Baton O, Azoulay D, Adam DV, Castaing D:** Major hepatectomy for hilar cholangiocarcinoma type 3 and 4: prognostic factors and longterm outcomes. *J Am Coll Surg.* 2007;204:250-260.
 9. **Japanese Society of Biliary Surgery (JSBS).** In: Nagakawa T ed. *Classification of Biliary Tract Carcinoma.* Tokyo: Kanehara & Co., Ltd., 2004, p.11-50.
 10. **Takasaki T, Kobayashi S, Suzuki S, Muto H, Marada M, Yamana Y, Nagaoka T:** Predetermining postoperative hepatic function for hepatectomies. *Int Surg* 1980; 65:309-313.
 11. **Kubota K, Makuuchi M, Kusaka K, Kobayashi T, Miki K, Hasegawa K, Harihara Y, Takayama T:** Measurement of liver volume and hepatic functional reserve as a guide to decision-making in resection surgery for hepatic tumors. *Hepatology* 1997; 26:1176-1181.
 12. **Takayama T, Makuuchi M, Kubota K, Harihara Y, Hui AM, Sano K, Ijichi M, Hasegawa K:** Randomized comparison of ultrasonic vs clamp transection of the liver. *Arch Surg* 2001;136:922-928.
 13. **Nanashima A, Yamaguchi H, Shibasaki S, Morino S, Ide N, Takeshita H, Sawai T, Nakagoe T, Nagayasu T, Ogawa Y:** Relationship between indocyanine green test and technetium-99m galactosyl serum albumin scintigraphy in patients scheduled for

hepatectomy: Clinical evaluation and patient outcome. *Hepatol Res.*

2004;28:184-190.

14. **Otani K, Chijiwa K, Kai M, Ohuchida J, Nagano M, Tsuchiya K, Kondo K:**
Outcome of surgical treatment of hilar cholangiocarcinoma. *J Gastrointest Surg.*
2008;12:1033-1040.
15. **Neuhaus P, Jonas S, Bechstein WO, Lohmann R, Radke C, Kling N, Wex C, Lobeck H, Hintze R:** Extended resections for hilar cholangiocarcinoma. *Ann Surg.*
1999;230:808-818
16. **Nagino M, Kamiya J, Arai T, Nishio H, Ebata T, Nimura Y:** One hundred consecutive hepatobiliary resections for biliary hilar malignancy: preoperative blood donation, blood loss, transfusion, and outcome. *Surgery.* 2005;137:148-155.
17. **Tsalis K, Vasiliadis K, Kalpakidis V, Christoforidis E, Avgerinos A, Botsios D, Megalopoulos A, Haidich AB, Betsis D:** A single-center experience in the management of Altemeier-Klatskin tumors. *J Gastrointest Liver Dis.*
2007;16:383-389.
18. **Mansfield SD, Barakat O, Charnley RM, Jaques BC, O'Suilleabhain CB, Atherton PJ, Manas D.** Management of hilar cholangiocarcinoma in the North of England: pathology, treatment, and outcome. *World J Gastroenterol.*
2005;11:7625-7630.

19. **Mann CD, Neal CP, Pattenden CJ, Metcalfe MS, Garcea G, Dennison AR, Berry DP:** Major resection of hepatic colorectal liver metastases in elderly patients - an aggressive approach is justified. *Eur J Surg Oncol.* 2008;34:428-432.
20. **Parikh AA, Abdalla EK, Vauthey JN:** Operative considerations in resection of hilar cholangiocarcinoma. *HPB* 2005;7:254-258.
21. **Nagino M, Nimura Y, Kamiya J, Kondo S, Uesaka K, Kin Y, Kutsuna Y, Hayakawa N, Yamamoto H:** Right or left trisegment portal vein embolization before hepatic trisegmentectomy for hilar bile duct carcinoma. *Surgery.* 1995;117:677-681.
22. **Nanashima A, Sumida Y, Abo T, Nonaka T, Takeshita H, Hidaka S, Sawai T, Yasutake T, Sakamoto I, Nagayasu T:** Clinical significance of portal vein embolization before right hepatectomy. *Hepatogastroenterology.* 2009;56:773-777.
23. **Nanashima A, Yamaguchi H, Shibasaki S, Morino S, Ide N, Takeshita H, Tsuji T, Sawai T, Nakagoe T, Nagayasu T, Ogawa Y:** Relationship between CT volumetry and functional liver volume using technetium-99m galactosyl serum albumin scintigraphy in patients undergoing preoperative portal vein embolization before major hepatectomy: a preliminary study. *Dig Dis Sci.* 2006, 51:1190-1195.
24. **Uesaka K, Nimura Y, Nagino M:** Changes in hepatic lobar function after right portal vein embolization. An appraisal by biliary indocyanine green excretion. *Ann Surg.* 1996;223:77-83.

25. **Nagino M, Takada T, Miyazaki M, Miyakawa S, Tsukada K, Kondo S, Furuse J, Saito H, Tsuyuguchi T, Yoshikawa T, Ohta T, Kimura F, Ohta T, Yoshitomi H, Nozawa S, Yoshida M, Wada K, Amano H, Miura F; Japanese Association of Biliary Surgery; Japanese Society of Hepato-Biliary-Pancreatic Surgery; Japan Society of Clinical Oncology:** Preoperative biliary drainage for biliary tract and ampullary carcinomas. *J Hepatobiliary Pancreat Surg.* 2008;15:25-30.
26. **Ferrero A, Lo Tesoriere R, Viganò L, Caggiano L, Sgotto E, Capussotti L:** Preoperative biliary drainage increases infectious complications after hepatectomy for proximal bile duct tumor obstruction. *World J Surg.* 2009;33:318-25.
27. **Nanashima A, Sumida Y, Abo T, Sakamoto I, Ogawa Y, Sawai T, Takeshita H, Hidaka S, Nagayasu T:** Usefulness of measuring hepatic functional volume using Technetium-99m galactosyl serum albumin scintigraphy in bile duct carcinoma: report of two cases. *J Hepatobiliary Pancreat Surg.* 2009;16:386-393.
28. **Nanashima A, Yamaguchi H, Shibasaki S, Ide N, Sawai T, Tsuji T, Hidaka S, Sumida Y, Nakagoe T, Nagayasu T:** Adjuvant photodynamic therapy for bile duct carcinoma after surgery: a preliminary study. *J Gastroenterol.* 2004;39:1095-1101.
29. **Murakami Y, Uemura K, Sudo T, Hayashidani Y, Hashimoto Y, Nakamura H, Nakashima A, Sueda T:** Gemcitabine-based adjuvant chemotherapy improves survival after aggressive surgery for hilar cholangiocarcinoma. *J Gastrointest Surg.* 2009;13:1470-1479.

30. **Ueno H, Okusaka T, Ikeda M, Takezako Y, Morizane C:** Phase II study of S-1 in patients with advanced biliary tract cancer. *Br J Cancer* 2004;91:1769-1774
31. **Watanabe T, Hirono H, Hasegawa K, Soga K, Shibasaki K, Yoneoka Y:** Advanced gastric cancer patient with peritonitis carcinomatosa successfully treated with a combination therapy of paclitaxel and TS-1, but relapsed with multiple bone metastasis and died from rapidly progressive meningitis carcinomatosa--advanced gastric cancer with metachronous peritonitis carcinomatosa and meningitis carcinomatosa. *Intern Med.* 2009;48:151-156.
32. **Jonas S, Benckert C, Thelen A, Lopez-Hänninen E, Rösch T, Neuhaus P:** Radical surgery for hilar cholangiocarcinoma. *Eur J Surg Oncol.* 2008;34:263-271.

Figure legend

Figures 1. The tumor-free survival in patients with hilar cholangiocarcinoma who underwent hepatectomy.

Figure 2. Overall survival in patients with hilar cholangiocarcinoma who underwent hepatectomy.

Figure 1

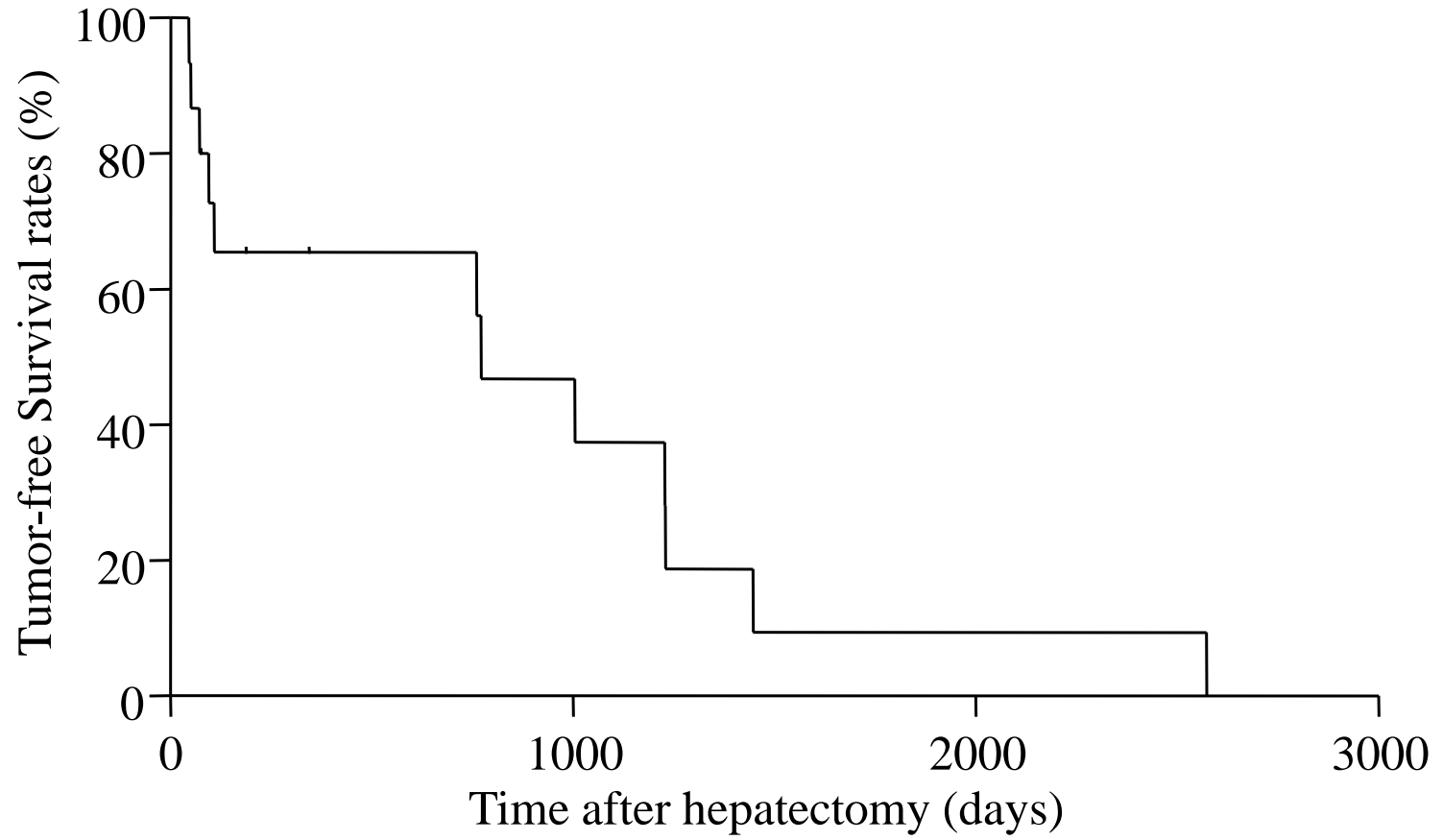


Figure 2

