

Prevention of gastric stasis by omentum patching after living donor left hepatectomy.

Ayaka Kinoshita, Mitsuhsa Takatsuki, Masaaki Hidaka, Akihiko Soyama, Susumu Eguchi,
Takashi Kanematsu

Department of Surgery, Nagasaki University Graduate School of Biomedical Sciences, Nagasaki,
Japan

Short running title: Omentum patching after living donor hepatectomy

Key words: liver transplantation, living donor, omentum

Address correspondence to:

Mitsuhsa Takatsuki, M.D.

Department of Surgery, Nagasaki University Graduate School of Biomedical Sciences,
1-7-1 Sakamoto, Nagasaki 852-8501, Japan

TEL: 81-95-819-7316

FAX: 81-95-819-7319

E-mail: takapon@net.nagasaki-u.ac.jp

Of 137 living liver donors from August 1997 to November 2010, 58 donated the left liver with or without the caudate lobe, and 4 of these (7%) developed gastric stasis after surgery (Figure 1), possibly due to dislocation of the stomach after hepatectomy and adhesion between the stomach and the cut surface of the liver. This complication is specific to left hepatectomy (1), and not life-threatening, but nonetheless is a symptomatic complication requiring endoscopic or surgical intervention to treat. Herein, we describe our technical invention to prevent this unpleasant complication.

Surgical procedures (Figure 2)

After left hepatectomy, there is a large cavity between the stomach and the cut surface of the liver (Figure 2A). A closed suction drain is generally placed at the cut surface via the dorsal route of the hepatoduodenal ligament. In our method, the omentum is then fully stretched (Figure 2B), and placed in this space, covering the hepatoduodenal ligament and cut surface of the liver (Figure 2C). Attention should be paid in order that the stomach and transverse colon are placed in natural positions. We simply leave the omentum in place without fixing by sutures (Figure 2D).

Patients with gastric stasis encounter frequent vomiting due to an enlarged stomach, as revealed in abdominal X-ray and/or computed tomography (Figure 1). Routine computed tomography is performed one month after surgery, mainly to check the regeneration of the liver.

In the 58 living donors who underwent left hepatectomy, omentum patching was performed in the last 45 cases. When compared to the first 13 cases without this procedure, the incidence of gastric stasis significantly decreased, from 23% (3/13) to 2% (1/45) ($P < 0.05$; Fisher's test). As shown in the computed tomography after surgery, the omentum remained in place between the stomach and the liver, preventing adhesion between them in all cases (Figure 3A) except one, which developed gastric stasis possibly due to dislocation of omentum. In all cases of gastric stasis without omentum patching, tight adhesion between the stomach and cut surface of the liver was observed (Figure 3B).

Gastric stasis is not life-threatening, but it is a significant complication that impairs the quality of life in living liver donors. In left hepatectomy, the stomach is twisted and falls into the space after

hepatectomy, and this also leads to adhesion between the stomach and the cut surface of the liver. In our series, no gastric stasis was observed in 62 right hepatectomies. Although all 4 cases that encountered gastric stasis are currently doing well, 3 had to undergo endoscopic repair, and 1 required surgical adhesiolysis to treat. There are few studies on the prevention of gastric stasis after left hepatectomy. Yoshida et al. proposed a procedure of fixing the greater omentum to the peritoneum, to prevent the stomach from falling into the space after hepatectomy (2). We introduced omentum patching, because it is very simple and requires no artificial materials. Currently, a sodium hyaluronate and carboxymethylcellulose membrane has been introduced as an effective material to prevent bowel obstructions due to adhesions (3,4), but it is not clear whether it can be applied to prevent adhesions between the cut surface of the liver and stomach. Besides the omentum, other possible intraabdominal materials might be intestines, but this might lead to bowel obstruction due to adhesion. We simply left the omentum without any plasties in the space between the stomach and the cut surface of the liver without fixing it by sutures. Even though the omentum was not fixed, computed tomography showed that the omentum remained in place between the stomach and the liver in majority of the cases. Omentum is widely used to prevent or treat various kinds of morbidities, including anastomotic leakage of the colon (5), perforation of duodenal ulcer (6), hepatic hydatid cyst (7), and some kinds of thoracic surgeries (8). In such cases, the omentum is generally used with some plasties, but we just place the omentum without any plasties, so that we called this procedure as “omentum patching”. This procedure cannot be applied when the omentum is not large enough in size to cover the cut surface of the liver, or when intraabdominal adhesion of the omentum is present due to a prior laparotomy. In our series, omentum patching was easily applied in all cases except one, which had previously undergone colectomy.

We believe that in living donor hepatectomy, omentum patching is generally available because the donors are healthy volunteers. This procedure is also useful for ordinary left hepatectomy for neoplasms, but even more applicable in living donor hepatectomy, in which any complications (even minor ones) should be avoided.

One possible disadvantage of this procedure is that the patients may tend to develop severe

peritonitis when some intraabdominal inflammations occurred (e.g., appendicitis) after surgery, because the general functions of the omentum include migration, covering, adhesion, mending the absorption against peritoneal injury or infection. So far, we have not experienced such adverse events with median follow-up period of 16 months (range, 1-42 months).

Another possible cause of adhesion between stomach and cut surface of the liver is bile leakage. It is essential to cut the bile duct with adequate point (9), and we had no cases with bile leakage which caused tight adhesion in our series, with our technical invention to cut the bile duct with optimal cutting point during donor surgery using C-arm cholangiography (10).

In conclusion, although a randomized study may be required to confirm the finding, omentum patching seemed effective at preventing gastric stasis after living donor left hepatectomy.

References

1. Taketomi A, Kayashima H, Soejima Y, Yoshizumi T, Uchiyama H, Ikegami T, Yamashita Y, Harada N, Shimada M, Maehara Y. Donor risk in adult-to-adult living donor liver transplantation: impact of left lobe graft. *Transplantation*. 2009;87:445-50.
2. Yoshida H, Mamada Y, Taniai N, Mizuguchi Y, Shimizu T, Kakinuma D, Ishikawa Y, Kanda T, Matsumoto S, Yokomuro S, Akimaru K, Tajiri T. Fixation of the greater omentum for prevention of delayed gastric emptying after left hepatectomy with lymphadenectomy for cholangiocarcinoma. *J Hepatobiliary Pancreat Surg*.2007;14:392-6.
3. Beck DE, Cohen Z, Fleshman JW, Kaufman HS, van Goor H, Wolff BG. Adhesion Study Group Steering Committee. : A prospective, randomized, multicenter, controlled study of the safety of Seprafilm adhesion barrier in abdominopelvic surgery of the intestine. *Dis Colon Rectum*.2003;46:1310-9.
4. Fazio VW, Cohen Z, Fleshman JW, van Goor H, Bauer JJ, Wolff BG, Corman M, Beart RW Jr, Wexner SD, Becker JM, Monson JR, Kaufman HS, Beck DE, Bailey HR, Ludwig KA, Stamos MJ, Darzi A, Bleday R, Dorazio R, Madoff RD, Smith LE, Gearhart S, Lillemoe K, Gohl J. Reduction in adhesive small-bowel obstruction by Seprafilm adhesion barrier after intestinal resection. *Dis Colon Rectum*.2006;49:1-11.
5. Hao XY, Yang KH, Guo TK, Ma B, Tian JH, Li HL. Omentoplasty in the prevention of anastomotic leakage after colorectal resection: a meta-analysis. *Int J Colorectal Dis*. 2008;23:1159-65.
6. Gypen BJ, Hubens GJ, Hartman V, Balliu L, Chapelle TC, Vaneerdeweg W. Perforated duodenal ulcer after laparoscopic gastric bypass. *Obes Surg*. 2008;18:1644-6.
7. Gourgiotis S, Stratopoulos C, Moustafellos P, Dimopoulos N, Papaxoinis G, Vougas V, Hadjiyannakis E. Surgical techniques and treatment for hepatic hydatid cysts. *Surg Today*. 2007;37:389-95.
8. Nosotti M, Cioffi U, De Simone M, Mendogni P, Palleschi A, Rosso L, Ciulla MM,

Santambrogio L. Omentoplasty and thoracoplasty for treating postpneumonectomy bronchopleural fistula in a patient previously submitted to aortic prosthesis implantation. *J Cardiothorac Surg.* 2009;4:38.

9. Igami T, Yokoyama Y, Nishio H, Ebata T, Sugawara G, Senda Y, Oda K, Abe T, Uehara K, Nagino M. A left hepatectomy and caudate lobectomy combined resection of the ventral segment of the right anterior sector for hilar cholangiocarcinoma--the efficacy of PVE (portal vein embolization) in identifying the hepatic subsegment: report of a case. *Surg Today.* 2009;39:628-32.
10. Takatsuki M, Eguchi S, Yamanouchi K, Hidaka M, Soyama A, Kanematsu T. Technical refinements of bile duct division in living donor liver surgery. *J Hepatobiliary Pancreat Sci.* 2011 Mar;18(2):170-5.

Figure legend

Figure 1

Gastric stasis after living donor left hepatectomy. Fluorescent imaging study showed enlarged stomach with no passage of radiofluorescence through the pylorus.

Figure 2

Surgical procedure of omentum patching. There is a large cavity between the stomach and the cut surface of the liver (A). The omentum is fully stretched (B) and placed over the hepatoduodenal ligament and cut surface of the liver (C). The omentum is left in place without fixing by sutures (D).

Figure 3

Computed tomography after surgery with (A) and without (B) omentum patching. The omentum remains in place between the stomach and the cut surface of the liver with omentum patching (arrows, A), while tight adhesion is observed in a case of gastric stasis without omentum patching (arrowheads, B).

Figure 1

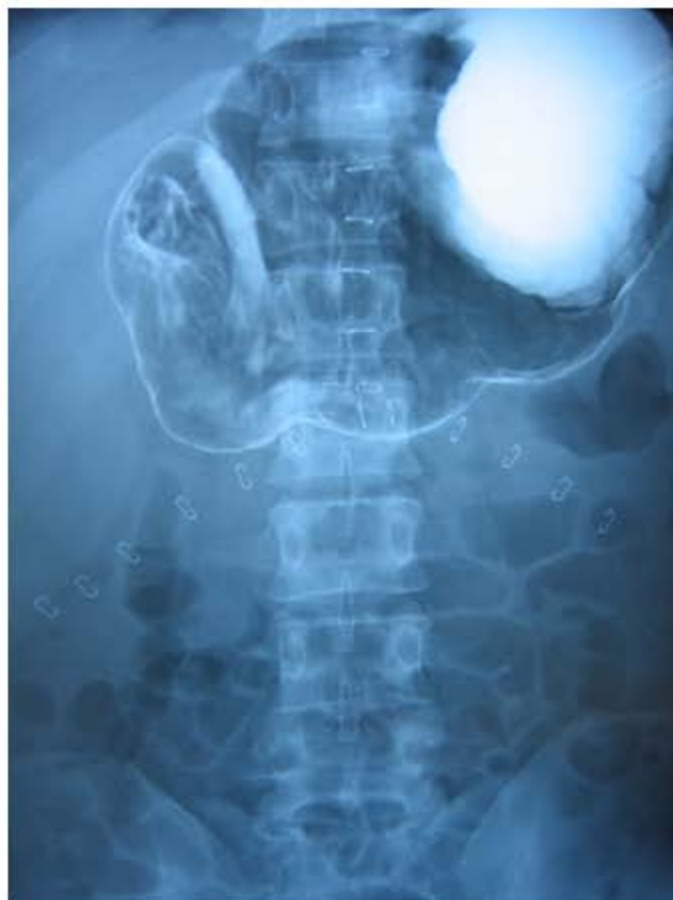

Figure 2

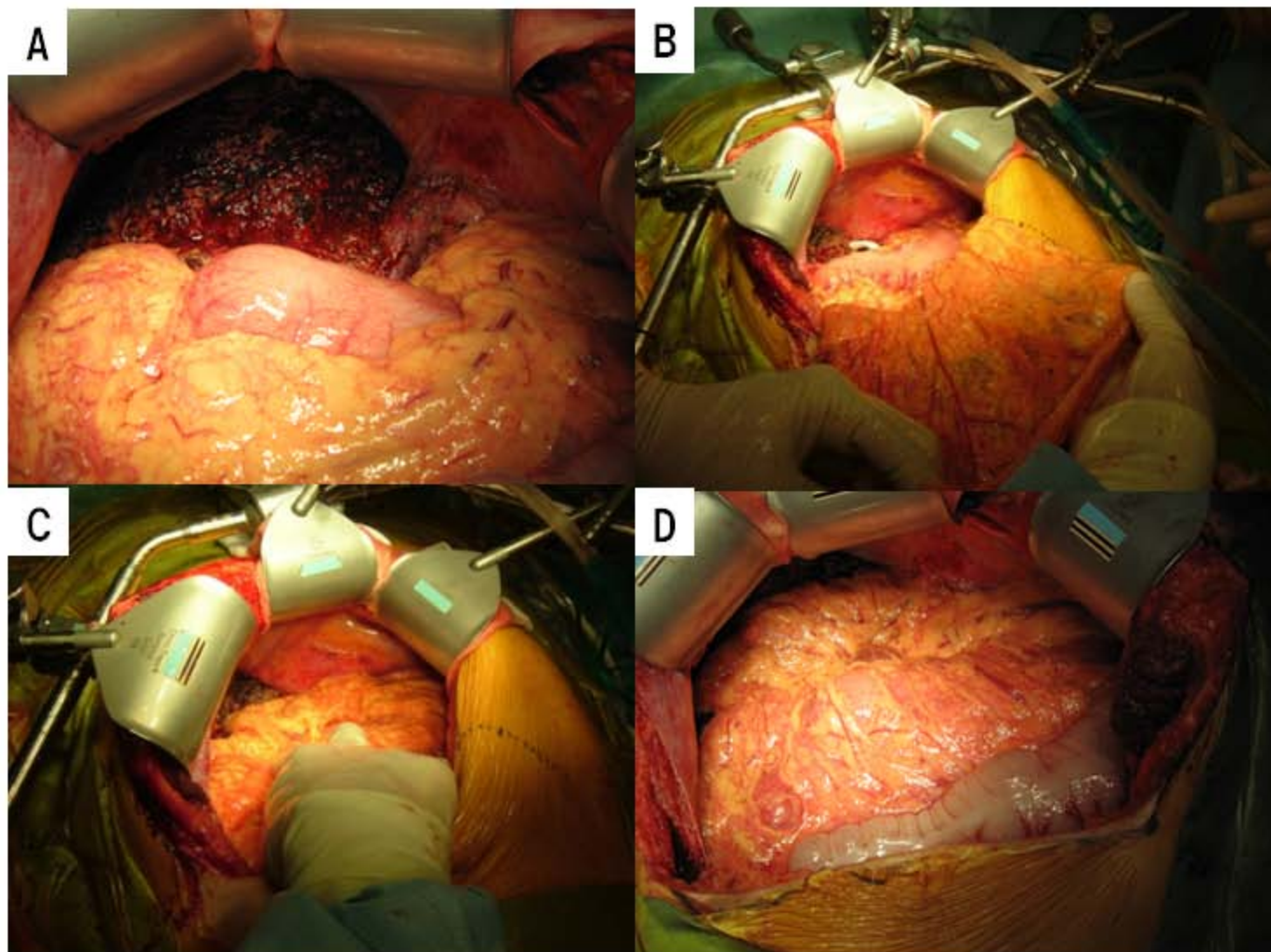


Figure 3

