

The nerves to the plantaris muscle and a bipennate part of the soleus muscle

Keishi Okamoto, Tetsuaki Wakebe, Kazunobu Saiki, Toshiyuki Tsurumoto

Department of Macroscopic Morphology, Unit of Basic Medical Sciences,
Graduate School of Biomedical Science, Nagasaki University, Nagasaki,
Japan

A short running title:

Plantaris muscle and its nerve

Address correspondence to:

Keishi Okamoto

Department of Macroscopic Morphology, Unit of Basic Medical Sciences,
Graduate School of Biomedical Science, Nagasaki University

1-12-4 Sakamoto, Nagasaki 852-8523, Japan.

Email: okamon@nagasaki-u.ac.jp

Fax: 095-819-7024

Tel. : 095-819-7022

Abstract

We performed nerve fiber analysis of the nerve to the plantaris muscle in 10 cases. Macroscopically, the nerve to the plantaris muscle has a tendency to branch off from the tibial nerve itself independent of the nerves to the gastrocnemius and soleus muscles (the triceps surae muscle). After removing the epineurium of the tibial nerve, it was revealed that, in all 10 cases, the nerve to the plantaris muscle formed a common funicular trunk with the nerve to a bipennate part of the soleus. This trunk is akin to the nerves to the deep muscles of the calf. In addition, in 5 of the 10 cases, the nerve to the plantaris muscle had another component which arose from the branch to the popliteus muscle. By removing the perineurium of the nerves concerned, it became clear that the elements of the nerve to the plantaris muscle and of the nerve to the bipennate part of the soleus had an intimate relation (inseparable). On the other hand, the elements of the nerve to the plantaris muscle and those to the popliteus were separable and they showed different routes proximally. Based on the present findings derived from nerve fiber analysis, we postulate that the plantaris muscle and bipennate part of the soleus muscle were probably derived from the deep muscle anlage of the calf in spite of their topographical closeness to the superficial muscles of the calf.

Key words

Plantaris muscle, soleus muscle, tibial nerve, muscles of the leg, nerve fiber analysis

Introduction

In humans, the plantaris muscle is a small muscle in the calf and it sometimes has a defect. In several mammals, however, the plantaris is relatively bigger and its insertion usually continues to the plantar aponeurosis, as its name implies. Topographically, the plantaris muscle is classified into the superficial group of the calf muscles together with the triceps surae muscle. Its origin is very close to that of the lateral head of the gastrocnemius muscle; hence, most anatomists consider without doubt that the plantaris originates from the lateral head of the gastrocnemius. Only Schmacher et al. (1973) pointed out that the plantaris is an independent muscle rather than a part of the lateral head of the gastrocnemius. However, when we examine the nerve supply of these muscles, the relation seems to be reconsidered. The plantaris usually receives its nerve supply from the tibial nerve independently, whereas the nerves to the gastrocnemius and soleus have a tendency to form a common trunk when they arise from the tibial nerve. In the forearm, Homma (1980) and Yamada (1986) classified the muscle groups based on the branching patterns of the median nerve, with Yamada proposing a new interpretation of the formation of the forearm flexor muscles. In the leg, Kudoh and Sakai (2007) studied the branching pattern of the common peroneal nerve. They clarified the branching pattern by removing the epineurium with teasing examination. To repeat the macroscopical observation mentioned above and in order to determine to which muscle group the plantaris belongs, we also performed teasing examination of the tibial nerve.

Materials and Methods

In total, 10 lower limbs were examined. Nine cases were obtained from 8 Japanese adult cadavers, used for medical students' dissection at Nagasaki University School of Medicine (7 cases) and Kanazawa University School of Medicine (2 cases). One case was obtained from a 5-month male fetus among specimens of Kanazawa Univ. Sch. of Med.

At first the gluteal, posterior femoral, and posterior crural regions were studied macroscopically and the sacral plexus, sciatic, and tibial nerves were recorded by drawings and photographs. Then, a specimen of these nerves was removed for subsequent teasing examination (nerve fiber analysis), together with the posterior crural muscles. Nerve fiber analysis was performed under a stereomicroscope, with the specimen immersed in water. First, the epineurium was removed with fine forceps along almost the entire course from the sacral plexus to the muscular branches of the posterior crural muscles. The findings were recorded by drawings and photographs. Next, the perineurium of relevant nerves was carefully removed to trace the constituents of the nerve to the plantaris muscle.

The protocol for the present research did not include any specific issue that required approval from the Ethics Committees of our institutions. The present work conformed to the provisions of the Declaration of Helsinki in 1995 (as revised in Edinburgh 2000).

Findings

I . Macroscopic observation

The branch to the triceps surae muscle and the medial sural cutaneous nerve arise from the tibial nerve within the popliteal fossa as a common trunk or as independent branches. There is a tendency whereby the branches to the lateral head of the gastrocnemius and the soleus form a common trunk and the branch to the medial head of the gastrocnemius and the medial sural cutaneous nerve also form a common trunk. The muscular branch to the plantaris, however, always arises independently from the tibial nerve beside or below the branch to the lateral head of the gastrocnemius (Fig. 1a). The muscular branch to the popliteus emerges from the tibial nerve further below the branch to the plantaris. Around the tendinous arch of the soleus the muscular branches to the deep flexor muscles branch off from the tibial nerve. The nerve to a bipennate part of the soleus is included there (Fig. 2). The bipennate part of the soleus is usually observed at the deep surface of the soleus (Fig. 1b).

II . Observation under a stereomicroscope

1. In all ten cases, the branch to the plantaris had nerve fibers which formed a common funicular trunk with nerve fibers to the bipennate part of the soleus (Figs. 3-5). The common funicular trunk sometimes contained nerve fibers elements to the flexor hallucis longus. When we moved from the perineurium of the common funicular trunk and traced proximally, the nerve fibers were intermingled with each other; therefore, it was difficult to trace the nerve fibers element of the branch to the plantaris alone.

2. In five of the ten cases, the branch to the plantaris had another element of nerve fibers which formed a common funicular trunk with the branch to the popliteus (Figs. 3-5). However, these elements of nerve fibers could be separated from each other by removing the perineurium of the common

funicular trunk. When we traced these elements of nerve fibers proximally, the element to the plantaris and that to the popliteus showed different routes. In other words, they belonged to different constituents of nerve fibers.

3. Any way, these funicular trunks above-mentioned belonged to the nerve group to the deep posterior crural muscles (② in Figs. 3-5) rather than to the nerve groups to the superficial crural muscles (① in Figs. 3-5).

Discussion

An intimate relationship between the nerve to the plantaris and the nerve to the bipennate part of the soleus became apparent from the present study using nerve fiber analysis, although it is usually not grossly recognizable anatomically. The nerve funiculus of their nerve elements showed a close relationship with the nerve funiculi to the deep posterior crural muscles. Therefore, we consider that the plantaris and bipennate part of the soleus muscle may be derived from the anlage of the deep posterior crural muscles. The soleus may be a complex structure of two derivatives judging from its dual nerve supplies. The superficial main part is akin to the gastrocnemius, and the deep bipennate part is akin to the plantaris and flexor hallucis longus. Sekiya (1991) and Eldon Y Loh et al. (2003) studied muscle architecture and the nerve supplies of the soleus precisely. Sekiya states that the soleus may be a single derivative, although he refers to an idea that the soleus might be a hybrid structure. Jager and Mall (1951) seem to support the idea of the single derivative like Sekiya. On the other hand, several authors such as McMurrich (1905), Bardeen (1906), Frohse and Fränkel (1913), and Schultz M et al. (1973) seem to favor the idea of the hybrid structure of the soleus. Regarding this, there have been several reports on an accessory soleus muscle (Bergman et al., 1988; Kawai et al., 1993; Sekiya et al., 1994; Okamoto et al., 2009). This muscle detaches from a deep distal part of the soleus muscle and inserts to the calcaneus independently from the calcaneal tendon on its medial side. This muscle is very akin to the bipennate part of the soleus, both from a topographical relation and nerve supplies (fig. 6). Probably both muscles have the same origin and may be derived from the deep flexor muscle anlage. The accessory soleus muscle seems to suggest the process of fusion of the bipennate part of the soleus with the soleus proper. This supports the idea that the soleus is a complex structure of two derivatives.

In several mammals including primates, the soleus muscle is smaller than the human soleus muscle and it has no tibial origin (Nagashima(1980), Sekiya(1991), our own observation on a Japanese monkey and a rat). The tibial origin of the soleus may be a later expansion in humans. We speculate that the bipennate part of the soleus attached to and fused with the soleus proper in accordance with this expansion, judging from its dual nerve supply and the results of their nerve fiber analysis. According to Sekiya(1991) the existence of the bipennate part and its nerve is peculiar to human. In contrast, the muscle belly of the plantaris in primates and mammals seems to be relatively bigger and longer than that of humans, and the tendon of the plantaris is usually continuous over the heel with the plantar aponeurosis in several mammals. For example, in the Japanese monkey and the rat, we observed such a relation. According to Nagashima (1980), in primates, the nerve to the plantaris shows a tendency to form a common trunk with the nerves to the deep posterior crural muscles. This may support our idea that the plantaris is derived from the anlage of the deep posterior crural muscles.

The results of the present study in the calf are similar to those on a study of the forearm by Yamada (1986). According to his study, the palmaris longus and proximal part of the second finger of the superficial flexor muscle show a close relationship with the deep flexor muscle, judging from their supplying nerves, although, topographically, they are situated superficially. This resemblance is interesting, because the palmaris longus and plantaris possess several morphological similarities. For example, both muscles have slender tendons and these tendons continue to the palmar aponeurosis and plantar aponeurosis in most mammals, although, in humans, it ends on the calcaneus. Both muscles or either muscle sometimes show a defect. Probably, these defects are due to un-derivation from the deep flexor muscle primordium.

It is not clear why, in five of the ten cases, the nerve to the plantaris had

another element of nerve fibers which formed a common trunk with the nerve fibers to the popliteus. After removing the perineurium, the element was separated from that to the popliteus. The meaning of these findings should be clarified by further research.

Conflict of interest None

References

- Bardeen CR (1906) Development and variation of the nerves and the musculature of the inferior extremity and of the neighboring regions of the trunk in man. *Am J Anat* 6, 259-390.
- Bergman RA, Thompson SA, Afini AK, Saadeh FA (1988) *Compendium of human anatomic variation*. Urban & Schwarzenberg, Baltimore
- Eldon Y Loh, Anne M Agur, Nancy H Mckee (2003) Intramuscular innervations of the human soleus muscle: a 3D model. *Clin Anat* 16:378-382
- Frohse F and Fränkel M (1913) Die Muskeln des menschlichen Beines. In: Bardeleben K (ed) *Handbuch der Anatomie des Menschen*, Gustav Fischer, Jena, Vol 2, Apt 2, Teil 2:561-569
- Homma T (1980) Ramification pattern and distribution of muscular branches of the median nerve to flexor muscles of the forearm. *Acta Anat Nippon* 55:328-329
- Jagar KW and Mall J (1951) The development of the human triceps surae. *J Anat* 85:338-349
- Kawai K, Kodama K, Okamoto K (1993) M. soleus secundus and its nerve supply. *Acta Anat Nippon* 68:352
- Kudoh H and Sakai T (2007) Fascicular analysis at perineurial level of the human common peroneal nerve. *Anat Sci Int* 82(4):218-226
- Mcmurich JP (1905) The phylogeny of the crural flexors. *Am J Anat* 4:33-76
- Nagashima S (1980) Innervation of the superficial flexor muscles of the lower leg of the Formosan monkey: with special reference to the medial sural cutaneous nerve. *Okajimas Folia Anat Jpn* 57:97-114

- Okamoto K, Wakebe T, Saiki K (2009) An accessory soleus muscle (secundes) and its nerve supply. *Acta Anat Nippon* 84 (supplement):172
- Schmacher GH, Schultz M, Himstedt HW, Menning A, Ehler E (1973) Zur Topographie der muscularen Nervenaustritte, 1. Untere Extremität. *M. plantaris longus*. *Anat Anz* 133:239-247
- Schultz M, Himstedt HW, Schmacher GH, Menning A, Freund E (1973) Zur Topographie der muscularen Nervenaustritte, 3. Untere Extremität. *M. soleus*. *Anat Anz* 133:341-349
- Sekiya S (1991) Muscle architecture and intramuscular distribution of nerves in the human soleus muscle. *Acta Anat* 140:213-223
- Sekiya S, Kumaki K, Yamada TK, Horiguchi M (1994) Nerve supply to the accessory soleus muscle. *Acta Anat* 149:121-127
- Yamada TK (1986) Re-evaluation of the flexor digitorum superficialis. *Acta Anat Nippon* 61:283-298

Figure Legends

Fig. 1. **a**, right popliteal fossa of a 63-year-old Japanese male. The lateral and medial heads of the gastrocnemius (GC_l, GC_m) are reflected. Three nerves arise from the tibial nerve here. They are the nerves to the triceps surae with the medial sural cutaneous nerve (Sur), the nerve to the plantaris (Pla, ★), and the nerve to the popliteus (Pop, ☆). **b**, a case of the bipennate part of the soleus observed at deeper surface of the soleus.

Fig. 2. Macroscopic ramifying pattern of branches from the sacral plexus, the sciatic nerve, and tibial nerve. The same example as in Fig. 1. Line a-b at the bottom left continues to line a'-b' at the top right.

Fig. 3. Photograph (**a**) and drawing (**b**) of nerve fiber analysis on the tibial nerve. The same example as in Figs. 1, 2. The epineurium was removed from the sacral plexus to the popliteal region.

Fig. 4. Three cases of nerve fiber analysis of the tibial nerve (a1:77-year-old male, b1:63-year-old male, c1:78-year-old male). Macroscopic branching patterns are inserted (a2, b2, c2).

Fig. 5. Left popliteal fossa of a five-month male fetus. **a**, Both heads of the gastrocnemius (GC_l, GC_m) and the soleus (Sol) are reflected. The bipennate part of the soleus (Sol.bip) is clearly shown. **b**, The epineurium was removed. The branch to the plantaris (Pla) has two elements which formed common trunks with the branch to the bipennate part of the soleus and branch to the popliteus (Pop). These trunks formed a common trunk with other elements to the deep crural muscles (②). The branches to the triceps surae (GC + Sol) and medial sural cutaneous nerve (Sur) formed another trunk (①).

Fig. 6. **a**, a case of the accessory soleus (acc) observed at the right lower calf. **b**, the soleus is reflected to show the bipennate part of the soleus (bip) and the accessory soleus. Their supplying nerves (*, ✖) form a common funicular trunk at the arrow mark.

Abbreviations

Admg= adductor magnus muscle

Art= articular branch

BF= biceps femoris muscle

Cal= calcaneus

F(C) = common fibular nerve

FDL(D)= flexor digitorum longus

FHL(H)= flexor hallucis longus

GCl(G-l)= lateral head of gastrocnemius

GCm(G-m)= medial head of gastrocnemius

NPL & NPM= lateral and medial plantar nerves

PA= popliteal artery

Pla, (★) = plantaris

Pop, (☆) = popliteus

PV= popliteal vein

Sm= semimembranosus

Sol(So)= soleus

Sol.bip (*) = bipennate part of soleus

St= semitendinosus

Sur(Su) = sural nerve (medial sural cutaneous nerve)

T = tibial nerve

Tend= tendo calcaneus

TP= tibialis posterior muscle

①= nerve branches to the superficial muscles of the calf (colored blue in Figs. 3-4)

②= nerve branches to the deep muscles of the calf (colored green in Figs. 3-4)

Fig. 1


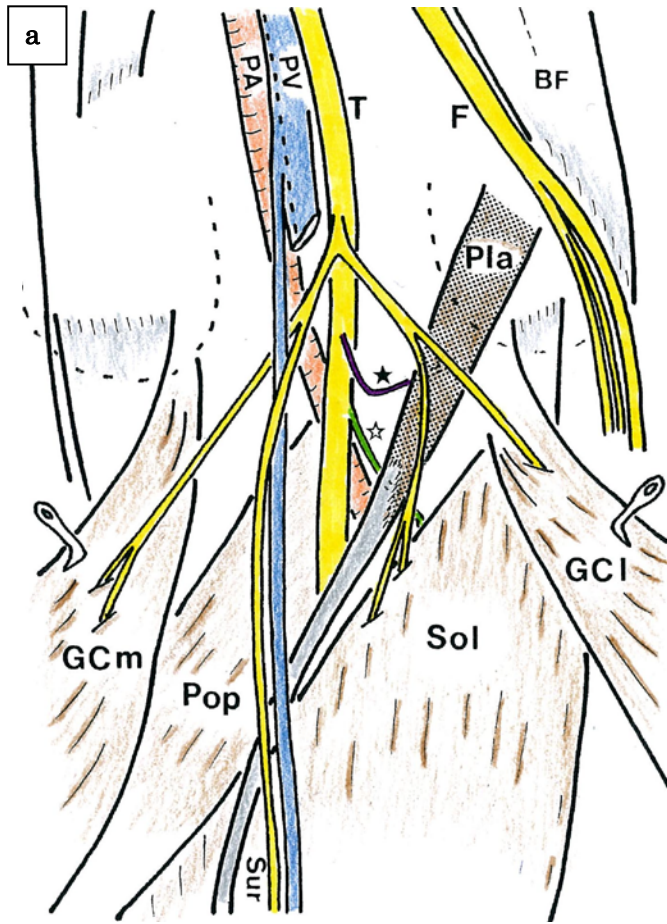


Fig. 2

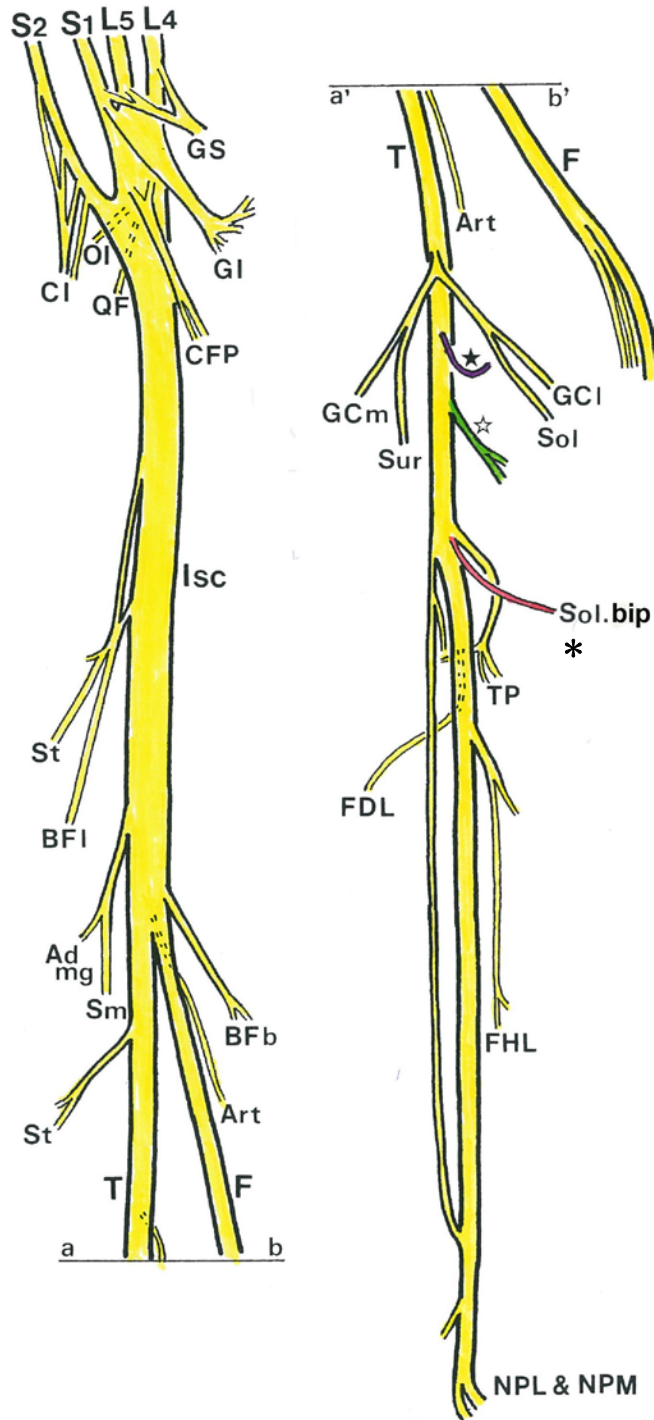


Fig. 3

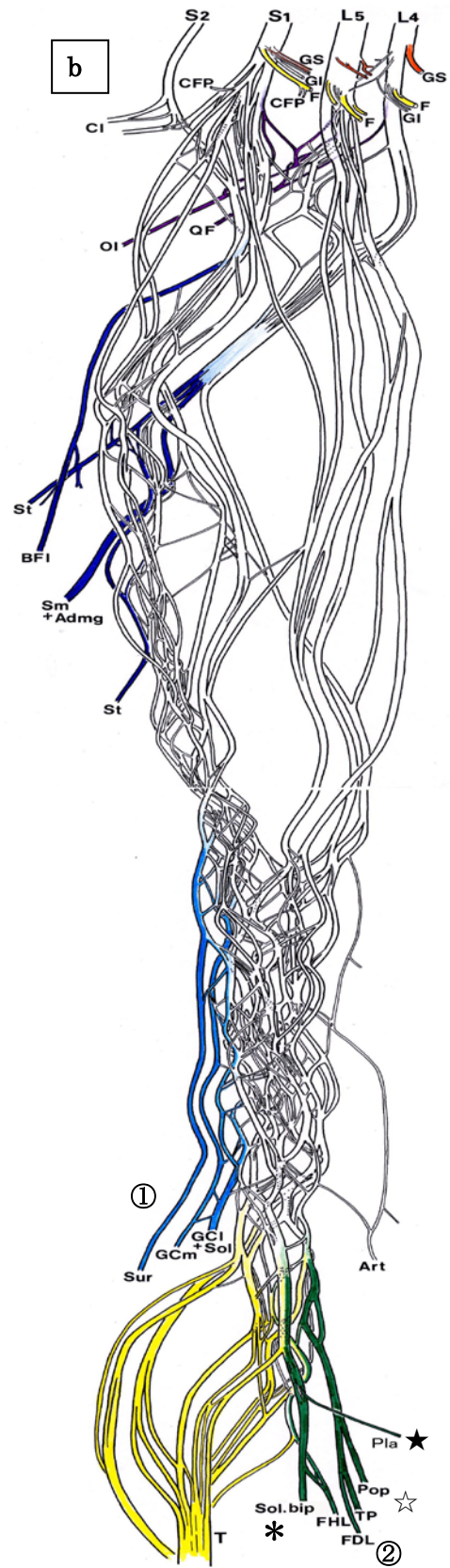
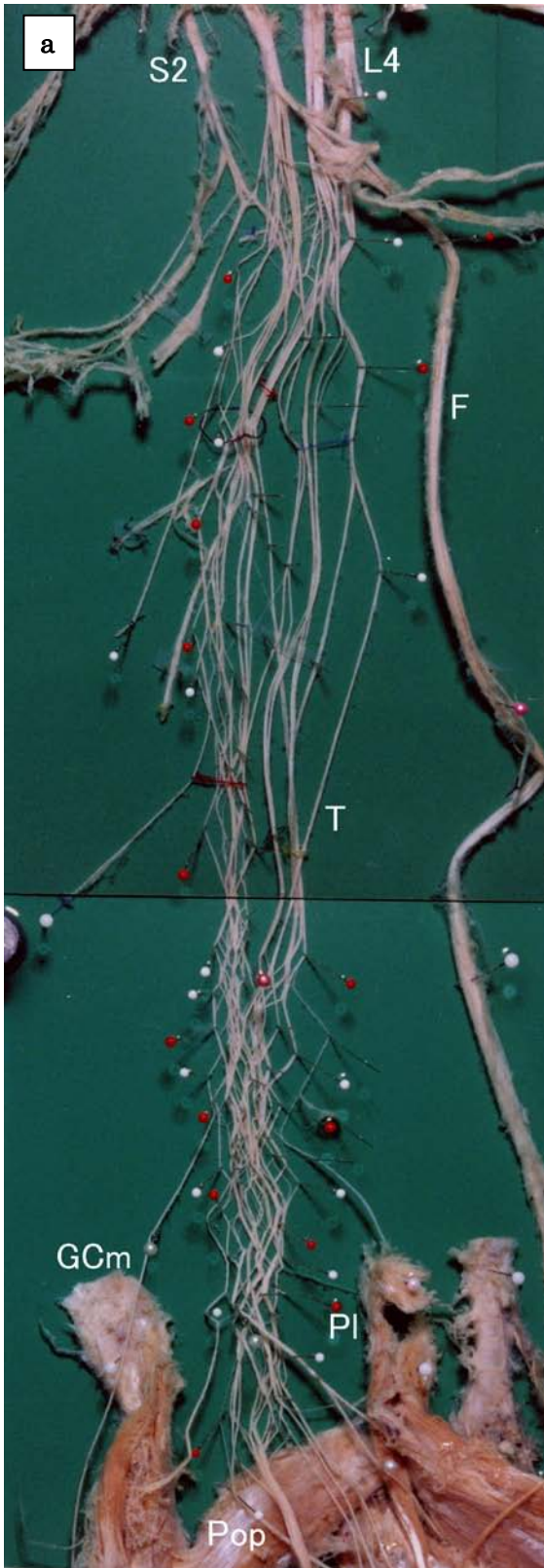


Fig.4

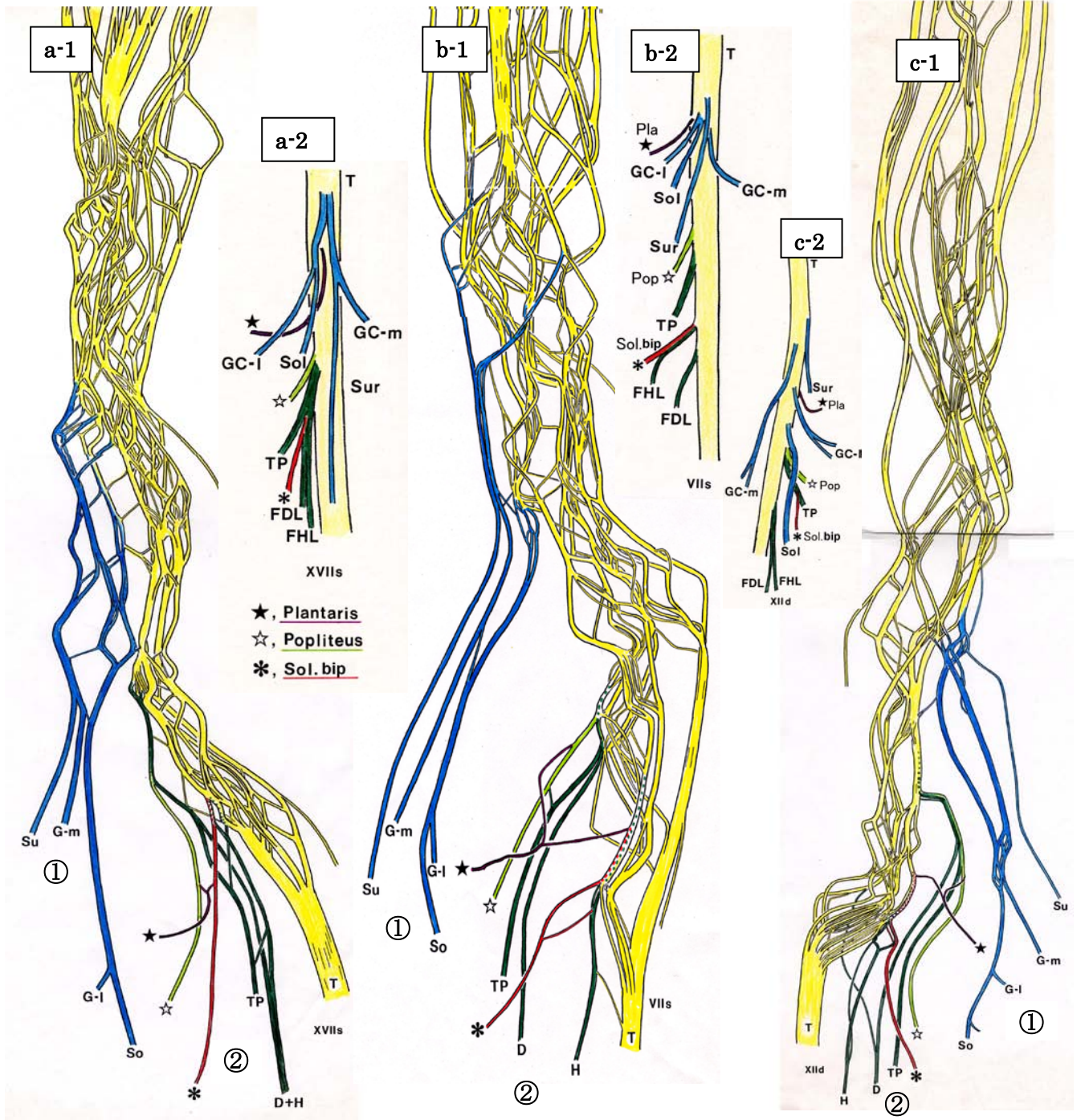


Fig. 5

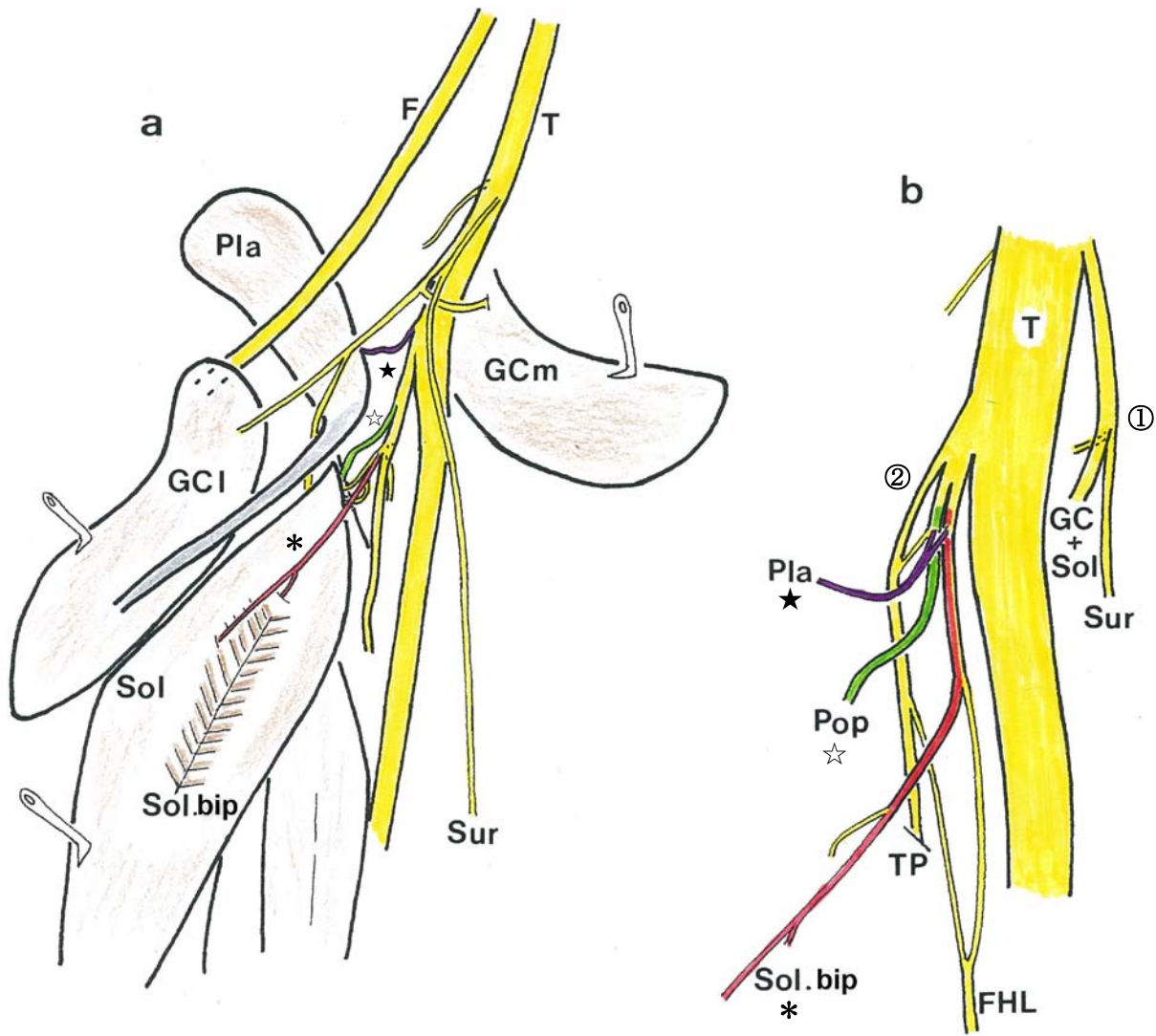


Fig. 6

