

**Efficacy of Aerosolized Liposomal Amphotericin B against Murine Invasive
Pulmonary Mucormycosis**

Tomo Mihara¹, Hiroshi Takeya¹, Koichi Izumikawa^{1,2}, Yoko Obata¹, Tomoya Nishino¹,
Takahiro Takazono¹, Kosuke Kosai², Yoshitomo Morinaga³, Shintaro Kurihara²,
Shigeki Nakamura¹, Yoshifumi Imamura¹, Taiga Miyazaki¹, Misuzu Tsukamoto²,
Yoshihiro Yamamoto¹, Katsunori Yanagihara³, Takayoshi Tashiro⁴, and Shigeru
Kohno¹

¹Department of Molecular Microbiology and Immunology, Nagasaki University

Graduate School of Biomedical Sciences,

²Nagasaki University Infection Control and Education Center, Nagasaki University

Hospital,

³Department of Laboratory Medicine, Nagasaki University Hospital,

⁴Department of Health Sciences, Nagasaki University Graduate School of Biomedical

Sciences, all in Nagasaki, JAPAN

Corresponding author:

Hiroshi TAKEYA, M.D., Ph.D.

Department of Molecular Microbiology and Immunology,

Nagasaki University Graduate School of Biomedical Sciences

1-7-1 Sakamoto, Nagasaki 852-8501, JAPAN

Phone: +81-95-819-7273, Fax: +81-95-849-7285

E-mail: akeya-ngs@umin.ac.jp

Words counts:

Abstract: 248 words

Manuscript: 2345 words

Abstract

Invasive pulmonary mucormycosis is a life-threatening fungal infection encountered in immunocompromised patients. An intravenous high-dose lipid formulation of amphotericin B, such as liposomal amphotericin B (L-AMB), is the recommended treatment. The efficacy of inhaled L-AMB against mucormycosis has not been evaluated.

We evaluated the efficacy of inhaled aerosolized L-AMB in murine invasive pulmonary mucormycosis. ICR female mice were immunosuppressed with cortisone acetate and cyclophosphamide and challenged on day 0 with 1×10^6 conidia of *Rhizopus oryzae* (TIMM 1327) intratracheally. Infected mice were assigned to one of the following 3 treatment groups: (i) control, (ii) treatment only (aerosolized L-AMB from day 1–5 after challenge), and (iii) prophylaxis followed by treatment (aerosolized L-AMB from day -2–5 before and after challenge). Survival was monitored until 12 days after challenge. For fungal-burden and histopathological examination, mice were sacrificed 4 h after treatment on day 3. Numbers of colony-forming units per lung were calculated. To study the distribution of AMB after inhalation of L-AMB, immunohistochemical studies using AMB antibody were performed.

Aerosolized L-AMB significantly improved survival rate and decreased fungal burden compared with control group, and histopathology findings were superior to those of control group. However, no significant differences were detected between the treatment-only and prophylaxis followed by treatment groups. Immunohistochemical analysis showed that L-AMB was promptly distributed in lung tissue after inhalation therapy.

Aerosolized L-AMB showed modest efficacy against *R. oryzae* infection in mice treated after fungal challenge. Prophylaxis with aerosolized L-AMB was not effective in this animal model.

Key words: aerosolized liposomal amphotericin B, mucormycosis, *Rhizopus oryzae*, prophylaxis, treatment

Introduction

Invasive pulmonary mucormycosis is associated with significant morbidity and mortality in immunocompromised patients with hematological disorders, malignancies, diabetes mellitus, and organ transplant recipients [1]. *Rhizopus* is the most common genus causing human mucormycetes infection, followed by *Mucor* and *Lichtheimia*. Recently, mucormycosis caused by unusual mucormycetes, (such as *Cunninghamella bertholletiae*, *Rhizomucor pusillus*, and *Apophysomyces elegans*) has been observed [2]. These less common mucormycetes also cause life-threatening mucormycosis.

Mucormycosis requires early and precise diagnosis, surgical debridement (if applicable), and prompt administration of antifungal agents to maximize the chances of achieving a good outcome. Polyens, rather than posaconazole, are the preferred therapeutic agents for mucormycosis [3, 4]. Liposomal amphotericin B (AmBisome, L-AMB) is formulated such that amphotericin B is contained within small unilamellar vesicles. L-AMB is less toxic than amphotericin B deoxycholate (D-AMB) [1]; however, intravenous L-AMB still may cause systemic toxicity, hypokalemia, renal toxicity, and other adverse events at certain levels.

The effectiveness and safety profiles of inhaled conventional amphotericin B in lung transplant patients have been reported by several investigators [5, 6]. Recently, use of the aerosolized lipid formulation of amphotericin B has been proposed for prophylaxis, with promising results [7]. Furthermore, nebulized L-AMB has been shown to be more effective and to have a longer half-life than conventional amphotericin-B (AMB) in animal pulmonary aspergillosis models [8, 9].

We previously reported that aerosolized L-AMB significantly improved survival, fungal burden, and histopathological findings in invasive murine pulmonary

aspergillosis. Furthermore, the combination of aerosolized L-AMB plus intraperitoneal micafungin was superior to either monotherapy. The concentration of AMB was found to be high in lung tissue, but extremely low in serum [10]. These results suggested that the systemic toxicity generally caused by AMB may be reduced when the drug is administered as L-AMB inhalation therapy, particularly when used long-term in the prevention of invasive filamentous fungal infections, including pulmonary mucormycosis and aspergillosis.

There are few clinical and experimental data on the prophylaxis and treatment of pulmonary aspergillosis, and little is known about the efficacy of L-AMB inhalation therapy against mucormycosis.

In the present study, we evaluated the efficacy of aerosolized L-AMB in a murine model of mucormycosis, and determined the distribution of L-AMB in the lungs after inhalation.

Materials and methods

Organism

R. oryzae TIMM 1327 was obtained from the Teikyo University Institute of Medical Mycology (Tokyo, Japan). The minimum inhibitory concentration (MIC) of AMB (Sigma, St. Louis, MO) was determined using the microdilution method in accordance with the Clinical Laboratory Standards Institute document M38-A2 [11].

Animals

Seven-week-old female ICR (imprinting control region) mice were purchased from Japan Charles River Breeding Laboratories (Shiga, Japan). All animals were housed in a pathogen-free environment and received sterile food and water in the Laboratory Animal Center for Biomedical Science at Nagasaki University (Nagasaki, Japan). The experimental protocols were approved by the Ethics Review Committee for Animal Experimentation at Nagasaki University.

Immunosuppression

Mice were immunosuppressed as previously described [12,13]. Briefly, mice received subcutaneous injection with cortisone acetate (Sigma, Tokyo, Japan) at 250 mg/kg of body weight, and intraperitoneal cyclophosphamide (Sigma) at 200 mg/kg on days -2 and 0 for the survival study. The cyclophosphamide (Sigma) at 200 mg/kg was used on days 2.

Efficacy of aerosolized L-AMB against pulmonary mucormycosis

ICR mice were immunosuppressed and then challenged on day 0 with 1×10^6 conidia of *R. oryzae* (TIMM 1327) intratracheally. Infected mice were assigned to one of the following 3 groups: (i) control group, (ii) aerosolized L-AMB treatment group, and (iii) aerosolized L-AMB prophylaxis plus treatment group. Treatment consisted of inhaled aerosolized L-AMB from day 1 to 5 after challenge, and prophylaxis plus treatment consisted of inhaled aerosolized L-AMB from day -2 to 5 before and after challenge. The L-AMB solution was aerosolized using a nebulizer (Muromachi Kikai Co., Ltd., Tokyo, Japan), and mice were exposed to aerosol treatment for 60 min as previously described [9]. L-AMB was administered once daily in an 8-mL suspension (at 1.2

mg/mL) for each inhalation. Control mice were not treated and monitored for survival. Each group consisted of 11 and 17 mice for survival and fungal-burden analyses, respectively. Survival was observed until 12 days after challenge. For fungal-burden and histopathological examinations, mice were sacrificed 4 h after treatment on day 3. Numbers of colony-forming units (CFUs) in lung tissue were calculated as previously described [10], and the lungs were fixed and stained with Grocott's methenamine silver nitrate (GMS) and hematoxylin-eosin as previously described [14]. Survival and fungal burden data have been pooled from 2 sets of experiments.

Statistical analysis

Survival curves were generated using the Kaplan-Meier method, and statistical differences were evaluated using the log rank test. To assess fungal burden in lung tissue, geometric means of CFUs per organ were compared using the Student's *t* test. Statistical significance was defined as a *P* value of <0.05.

AMB concentration in the bronchoalveolar lavage fluid and alveolar macrophages

The concentration of AMB in bronchoalveolar lavage fluid (BAL) and lung cells was evaluated. Uninfected mice were exposed to an aerosolized 8-mL suspension of L-AMB (at 1.2 mg/mL) for inhalation; BAL samples were recovered once per day for 3 days. Alveolar macrophages were collected by centrifugation of BAL. The supernatant was removed, and the pellet was washed twice with saline. AMB concentration was quantified using high-performance liquid chromatography as previously described [15].

Immunohistochemical localization of AMB in the lung tissue

Immunohistochemical localization of AMB in the lung tissue was performed as previously described [15]. Briefly, aerosolized L-AMB was administered once daily for 15, 45, or 60 min for 3 consecutive days. Both lungs were excised 30 min after inhalation of L-AMB on day 3.

Immunohistochemical detection of AMB was performed on 5- μ m frozen sections of mouse lung, as described previously [16]. The frozen sections were dried and postfixed in 4% paraformaldehyde in phosphate buffered saline (PBS) (pH 7.4). After washing with PBS, the sections were incubated with 5% normal goat serum (Dako, Glostrup, Denmark) and 1% bovine serum albumin (BSA) (Sigma, MO, USA) at room temperature (RT) for 1 h. Then, the sections were reacted with rabbit anti-AMB (kindly gifted from Gilead Science) (1 μ g/mL) in 1% BSA at RT for 2 h. After being washed in 0.075% Brij 35 (Sigma) in PBS 3 times for 5 min each, the sections were incubated with Alexa 546 goat anti-rabbit IgG (Invitrogen, CA, USA) (1/500) in 1% BSA at RT for 30 min. After washing again with 0.075% Brij 35 in PBS 3 times for 5 min, nuclei were stained with 4',6'-diamino-2-phenylindole (Molecular Probes, OR, USA) for 1 min. As a negative control, sections were reacted with normal rabbit IgG (Dako) instead of the first antibody. The analysis of fluorescence signals was performed using LSM 5 Pascal (V3.2) (Carl Zeiss, Jena, Germany).

Results

In vitro experiments in murine pulmonary mucormycosis

The MIC of AMB against *R. oryzae* TIMM 1327 was 0.25 μ g/mL.

Survival rate of R. oryzae-infected mice

Survival rate was significantly higher in the treatment and prophylaxis plus treatment groups than in the control ($P < 0.05$ for both) (Fig. 1). However, significant differences were not observed between the treatment and the prophylaxis plus treatment groups.

Lung fungal burden of R. oryzae-infected mice after inhalation of aerosolized L-AMB

Lung fungal burdens in the treatment and prophylaxis plus treatment groups were significantly lower than those in the control group ($P < 0.05$) (Fig. 2). No significant differences were observed in fungal burden between the treatment and prophylaxis plus treatment groups.

Lung histopathological examination of R. oryzae-infected mice after inhalation of aerosolized L-AMB

Light microscopy of the hematoxylin-eosin-stained lung tissue of control mice revealed severe inflammatory changes with hemorrhage (Fig. 3, a). In the treatment group (Fig. 3, b), mild inflammatory changes were evident, and even less inflammation was seen in the prophylaxis plus treatment group (Fig. 3, c). GMS-stained lung tissue of the control mice showed extensive angioinvasive hyphae and alveolar consolidation (Fig. 3, d). Fewer hyphae were seen in the treatment and prophylaxis plus treatment groups (Fig. 3, e, f).

AMB concentration in the BAL fluid and alveolar macrophages

The mean AMB concentration in the BAL fluid after L-AMB inhalation for 3 days was 0.59 $\mu\text{g/mL}$ ($N = 10$), as compared with $<0.05 \mu\text{g/mL}$ in the control group ($N = 10$). The

mean AMB concentration in the alveolar macrophage pellets ($/10^4$ cells) following L-AMB inhalation for 3 days was $0.02 \mu\text{g/mL}$ ($N = 10$), as compared with $<0.01 \mu\text{g/mL}$ in the control group ($N = 10$).

Distribution of AMB in the lungs

The distribution of AMB in the lungs after inhalation of aerosolized L-AMB for 15, 45, or 60 min for 3 consecutive days is presented in Figure 4. The lungs of mice exposed to aerosolized L-AMB for 15 min showed slightly bright red fluorescence localized to the surface of the respiratory tract (Fig. 4, b). In contrast, the respiratory tract surfaces of control mice showed only faint fluorescence (Fig. 4, a).

The red fluorescence was localized at the surface of the respiratory tract after the inhalation of aerosolized L-AMB at 45 min (Fig. 4, c) and 60 min per day, for 3 days (Fig. 4, d). The intensity of the red fluorescence was increased for mice exposed to aerosolized L-AMB for 45 (Fig. 4, c) and 60 min per day for 3 days (Fig. 4, d) compared to that of mice exposed to aerosolized L-AMB for 15 min (Fig. 4, b).

In the alveolar region of the mice lungs, red fluorescent dots were observed for mice exposed to 15 min of aerosolized L-AMB (Fig. 4, f). In contrast, no signals were observed in the alveolar region of control mice (Fig. 4, e). The red fluorescent dots in the alveolar region were also observed in mice exposed to aerosolized L-AMB for 45 and 60 min per day for 3 consecutive days (Fig. 4, g, h).

These results indicated that L-AMB reached the respiratory tract and alveolar regions immediately after inhalation.

Discussion

The present study demonstrated the efficacy of aerosolized L-AMB in murine invasive mucormycosis. The time-course distribution of AMB in mice lungs after inhalation of aerosolized L-AMB showed that L-AMB reached the alveolar region immediately, and was transferred to internal macrophages. It has been reported that nebulized L-AMB has a long half-life in the human lung [9]. In that study, nebulized L-AMB was used as prophylaxis for aspergillosis infection in lung transplant patients as follows: patients received 25 mg 3 times per week up to day 60 post-transplantation, 25 mg once per week between days 60 and 180, then 25 mg once every 2 weeks indefinitely thereafter. In such a clinical setting, AMB concentrations remained high even when doses were administered 14 days apart (3.0 µg/mL and 4.1 µg/mL in the first and third aliquots of BAL, respectively).

In our study, for the prophylaxis efficacy of aerosolized L-AMB, treatment consisted of inhaled aerosolized L-AMB from day -2 to 0 before challenge as the prophylaxis group (n=11). Consequently, the prophylaxis group tended to have improved survival rates compared to mice in the control group; however, no significant differences between the prophylaxis and control groups were detected ($P=0.274$) (data not shown). In contrast, the treatment and prophylaxis plus treatment groups had significantly improved survival rates compared to the control group. These data suggest that prophylaxis with aerosolized L-AMB is not effective in this murine mucormycosis model, while post-challenge treatment with inhaled L-AMB is apparently effective. Different experimental conditions such as longer period of treatment than 3 days, longer time of inhalation, increasing daily dose of L-AMB, and increasing the number of inhalation

time to twice a daily, may potentially demonstrate some prophylactic efficacy for aerosolized L-AMB.

The most invasive mucormycosis infections occur in the lung. Although the exact pathogenesis is unclear, when *R. oryzae* conidia are inhaled into the lung, alveolar macrophages and neutrophils play a role in primary host defense. Alveolar macrophages form the first line of defense against microorganisms entering the lungs through the airways. Hence, concentrations of AMB in lung tissue or alveolar macrophages are important. Our immunohistochemical study revealed that L-AMB was rapidly transferred into lung tissue and macrophages; in the alveolar region of mice lungs, red fluorescent dots were observed after inhalation. However, because the dots were bigger than the liposomes containing AMB in the drug's formulation (100 nm), these dots were considered to be aggregates of liposomes containing AMB or endocytosed liposomes containing AMB. In contrast, L-AMB immediately reached the respiratory tract and accumulated on its surface. It has been reported that L-AMB itself was localized at infection sites, and this pattern of distribution might contribute to the activity of L-AMB in vivo [15]. Therefore, it is interesting to see the distribution of L-AMB at the lung infection sites in murine mucormycosis. Generally, invasive pulmonary mucormycosis is characterized by the rapid development of tissue necrosis as a result of vascular invasion, with hemorrhage and subsequent thrombosis. However, since anti-AMB antibody cross-reacts with hemorrhagic regions, the distribution of AMB in our murine mucormycosis model could not be analyzed. In addition, immunohistochemical study after cessation of L-AMB inhalation might be revealed the reason why the efficacy against murine mucormycosis was limited in prophylaxis group of mice.

It is interesting to determine whether L-AMB is absorbed as AMB into the alveolar region. Although a faint signal was observed in the background area in mice exposed to aerosolized L-AMB for 60 min on 3 consecutive days, it was not revealed how AMB attached to and remained on the surface of the lung and in the alveolar region. Further characterization of the intrapulmonary pharmacodynamics and disposition of inhaled aerosolized L-AMB in infected patients is warranted.

In conclusion, aerosolized L-AMB showed modest efficacy against *R. oryzae* infection in mice treated after fungal challenge. The results suggest that intratracheal administration of aerosolized L-AMB has potential as a safe and effective strategy for the treatment of invasive pulmonary mucormycosis. However, prophylaxis with aerosolized L-AMB was not effective in this animal model. In clinical setting, if mucormycosis is strongly suspected, intravenous L-AMB should be considered.

Transparency declarations

Shigeru Kohno received honorarium, consultation fee and research grant from Pfizer Inc, and Dainippon Sumitomo Pharama. Co.

Figure legends

Figure 1

Survival curves of mice (n = 11–17 per group) infected with *R. oryzae* (Kaplan-Meier plot). Mice were treated with an inhalation of aerosolized L-AMB from day 1 to 5 (treatment group: filled circles) or from day -2 to day 5 (prophylaxis plus treatment group: open circles), or were untreated (control group: open triangles). * $P < 0.05$ versus control (log rank test). Survival in the treatment group and the prophylaxis plus treatment group was longer than that in the control group ($P < 0.05$).

Figure 2

Fungal burden in lungs after 3 days of treatment with aerosolized L-AMB.

The number of colony-forming units recovered from homogenized murine lung tissues. Groups of 7–9 mice infected with *R. oryzae* were intratracheally treated with aerosolized L-AMB (4 mg/mL) daily, and lungs were excised after 3 days of treatment. * $P < 0.05$ (Student's *t* test). Inhalation of L-AMB resulted in significant reduction in the lung fungal burdens compared to the control group.

Figure 3

Histopathology of lung tissues.

Both lungs were excised after 3 days of treatment with inhalation of aerosolized L-AMB. HE, hematoxylin-eosin; GMS, Grocott's methenamine silver nitrate stain.

The infiltrates in control animals showed extensive hyphal spreading and angioinvasion; the median hyphal lengths are shown (a, d). The hyphal numbers and lengths were

markedly reduced in the lungs of mice from the treatment group (b, e), and the maximal suppression of hyphal invasion was observed in the lungs of mice in the prophylaxis plus treatment group (c, f). Original magnification: HE stain x100, GMS stain x200

Figure 4

Distribution of AMB in the lungs after inhalation of aerosolized L-AMB for 15 min (b, f), 45 min (c, g), or 60 min (d, h) for 3 consecutive days. Lung tissues were excised 30 min after inhalation. Immunohistochemical detection of AMB was performed using anti-AMB antibody. To assess the positive areas for AMB in the pulmonary tract region (a-d) and in the alveolar region (e-h), mice lung tissues were examined by fluorescence microscopy. Red fluorescence was localized at the surface on the respiratory tract after inhalation of aerosolized L-AMB. The intensity was increased for mice exposed to 45 min as compared to those exposed to 15 min of aerosolized L-AMB. In the alveolar region, the red fluorescent dots were observed for mice exposed to aerosolized L-AMB for 15 min, 45 min, and 60 min for 3 consecutive days. In contrast, no signal was observed in the alveolar region of control mice. Original magnification: x400.

References

1. Sun HY, Singh N. Mucormycosis: its contemporary face and management strategies. *Lancet Infect Dis.* 2011;11:301–11.
2. Gomes MZ, Lewis RE, Kontoyiannis DP. Mucormycosis caused by unusual mucormycetes, non-Rhizopus, -Mucor, and -Lichtheimia species. *Clin Microbiol Rev.* 2011;24:411–45.
3. Dannaoui E, Meis JF, Loebenberg D, Verweij PE. Activity of posaconazole in treatment of experimental disseminated zygomycosis. *Antimicrob Agents Chemother.* 2003;47:3647–50.
4. Sun QN, Najvar LK, Bocanegra R, Loebenberg D, Graybill JR. In vivo activity of posaconazole against *Mucor* spp. in an immunosuppressed-mouse model. *Antimicrob Agents Chemother.* 2002;46:2310–2.
5. Monforte V, Roman A, Gavalda J, Bravo C, Tenorio L, Ferrer A, *et al.* Nebulized amphotericin B prophylaxis for *Aspergillus* infection in lung transplantation: study of risk factors. *J Heart Lung Transplant.* 2001;20:1274–81.
6. Reichenspurner H, Gamberg P, Nitschke M, Valantine H, Hunt S, Oyer PE, *et al.* Significant reduction in the number of fungal infections after lung-, heart-lung, and heart transplantation using aerosolized amphotericin B prophylaxis. *Transplant Proc.* 1997;29:627–8.
7. Lowry CM, Marty FM, Vargas SO, Lee JT, Fiumara K, Deykin A, *et al.* Safety of aerosolized liposomal versus deoxycholate amphotericin B formulations for prevention of invasive fungal infections following lung transplantation: a retrospective study. *Transpl Infect Dis.* 2007;9:121–5.
8. Allen SD, Sorensen KN, Nejdil MJ, Durrant C, Proffit RT. Prophylactic efficacy of aerosolized liposomal (AmBisome) and non-liposomal (Fungizone) amphotericin B in murine pulmonary aspergillosis. *J Antimicrob Chemother.* 1994;34:1001–13.
9. Ruijgrok EJ, Fens MH, Bakker-Woudenberg IA, van Etten EW, Vulto AG. Nebulization of four commercially available amphotericin B formulations in persistently granulocytopenic rats with invasive pulmonary aspergillosis: evidence for long-term biological activity. *J Pharm Pharmacol.* 2005;57:1289–95.
10. Takazono T, Izumikawa K, Mihara T, Kossai K, Saijo T, Imamura Y, *et al.* Efficacy of combination antifungal therapy with intraperitoneally administered

micafungin and aerosolized liposomal amphotericin B against murine invasive pulmonary aspergillosis. *Antimicrob Agents Chemother.* 2009;53:3508–10.

11. Clinical Laboratory Standards Institute. 2008. Reference method for broth dilution antifungal susceptibility testing of filamentous fungi. Approved standard, 2nd ed. Document M38-A2. Clinical Laboratory Standards Institute, Wayne, PA

12. Otsubo T, Maruyama K, Maesaki S, Miyazaki Y, Tanaka E, Takizawa T, *et al.* Long-circulating immunoliposomal amphotericin B against invasive pulmonary aspergillosis in mice. *Antimicrob Agents Chemother.* 1998;42:40–4.

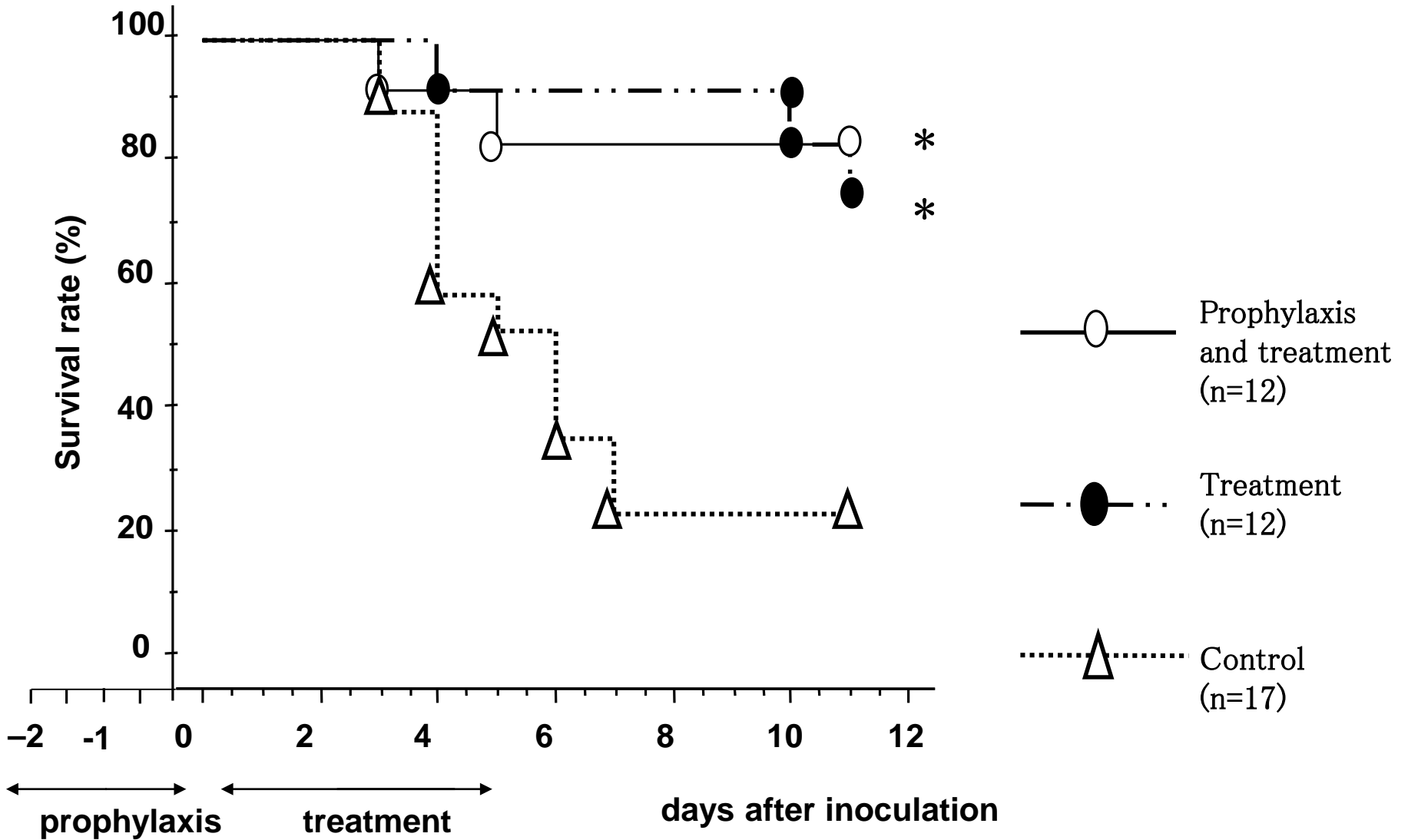
13. Kakeya H, Miyazaki Y, Senda H, Kobayashi T, Seki M, Izumikawa K, *et al.* Efficacy of SPK-843, a novel polyene antifungal, in comparison with amphotericin B, liposomal amphotericin B, and micafungin against murine pulmonary aspergillosis. *Antimicrob Agents Chemother.* 2008;52:1868–70.

14. Tansho S, Abe S, Ishibashi H, Torii S, Otani H, Ono Y, *et al.* Efficacy of intravenous itraconazole against invasive pulmonary aspergillosis in neutropenic mice. *J Infect Chemother.* 2006;12:355–62.

15. Takemoto K, Yamamoto Y, Ueda Y, Sumita Y, yoshida K, Niki Y. Comparative study on the efficacy of AmBisome and Fungizone in a mouse model of pulmonary aspergillosis. *J Antimicrob Chemother.* 2006;57:724–31.

16. Koji T, Kondo S, Hishikawa Y, An S, Sato Y. In situ detection of methylated DNA by histo endonuclease-linked detection of methylated DNA sites: a new principle of analysis of DNA methylation. *Histochem Cell Biol.* 2008;130:917–25.

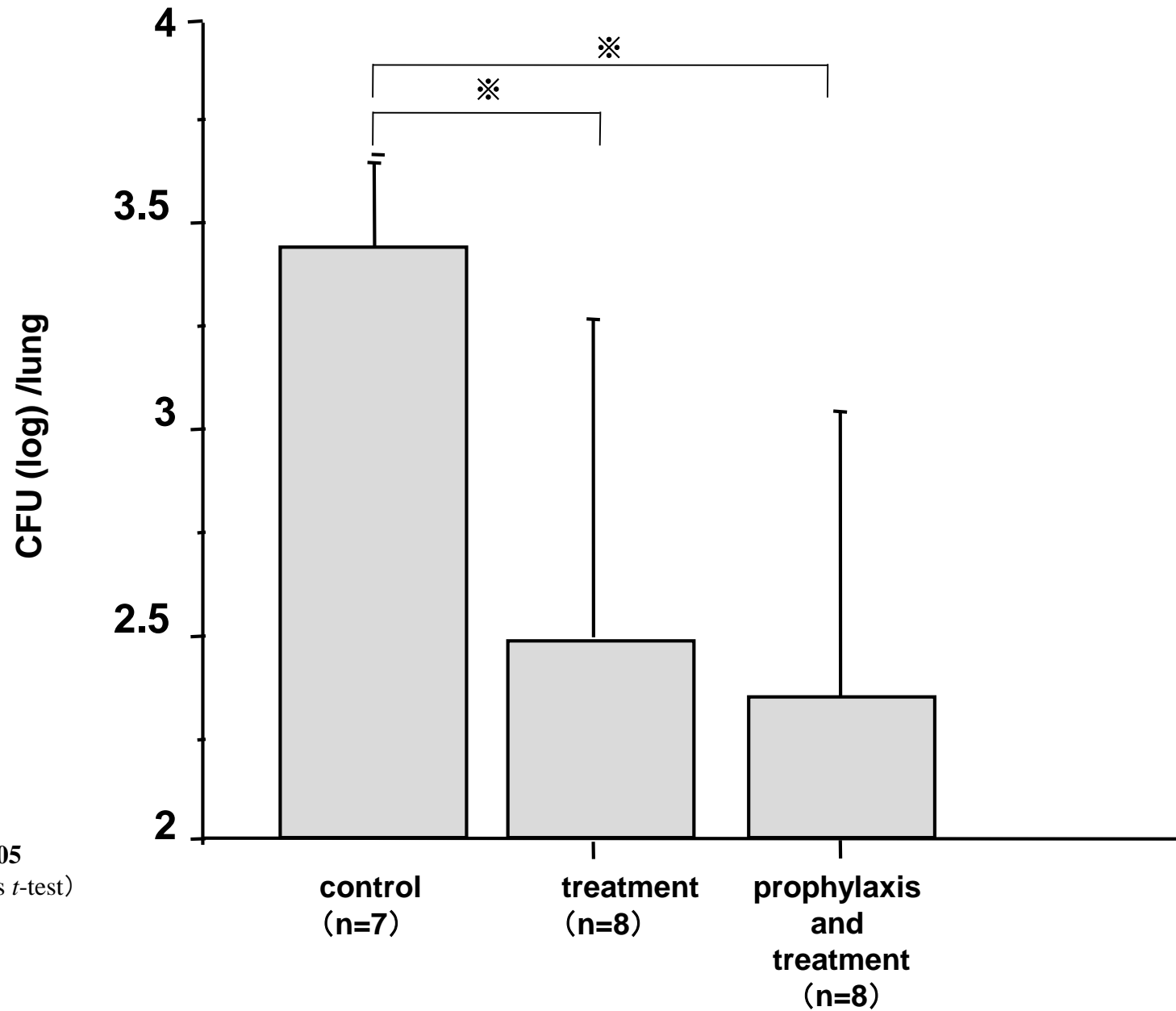
Fig. 1



* P < 0.05 log rank test

Fig. 2

Fungal burdens in lungs after 3 days treatment



※ P<0.05
(Student's *t*-test)

Fig. 3 **Histopathology of lung tissues (day 3)**

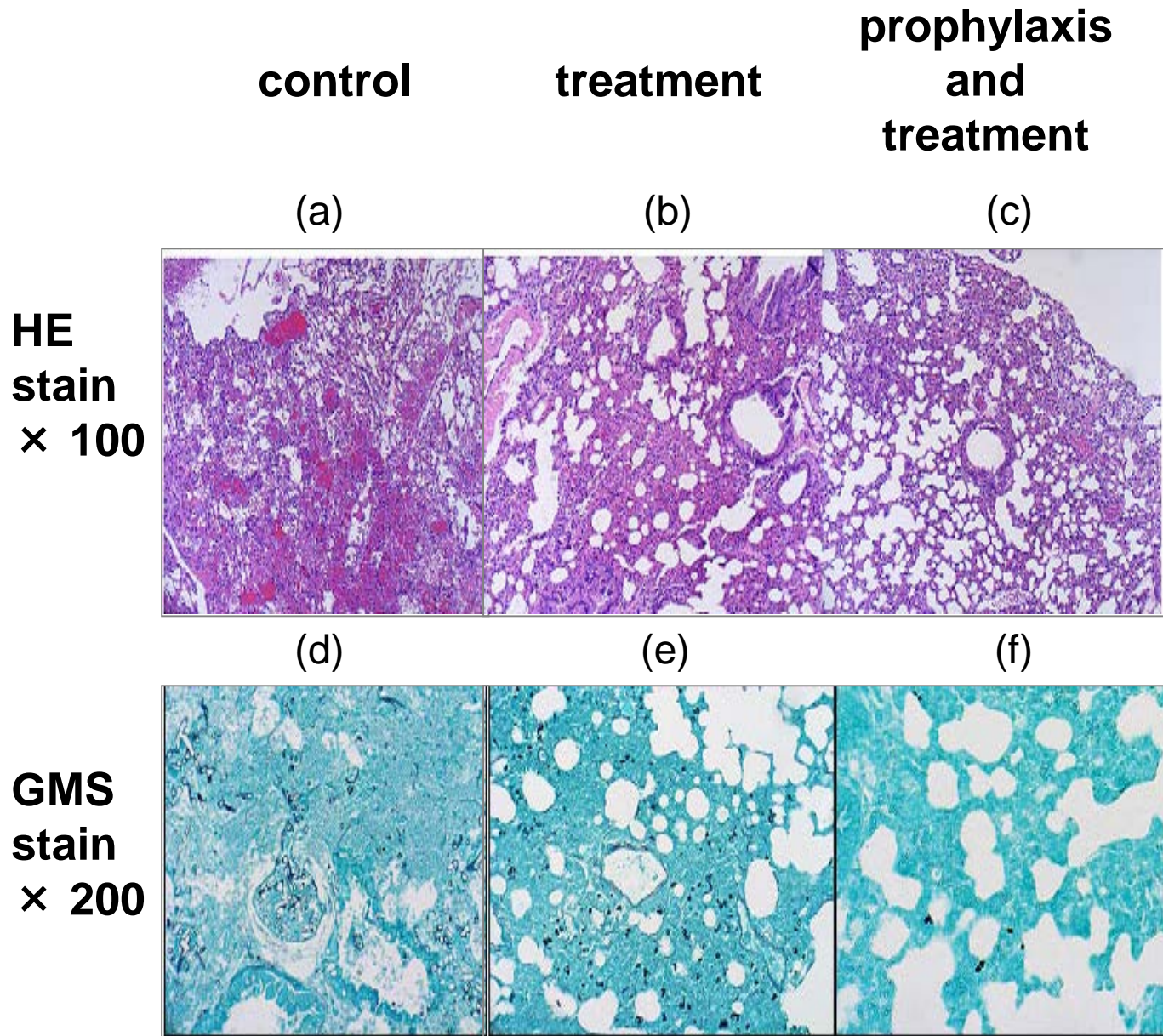
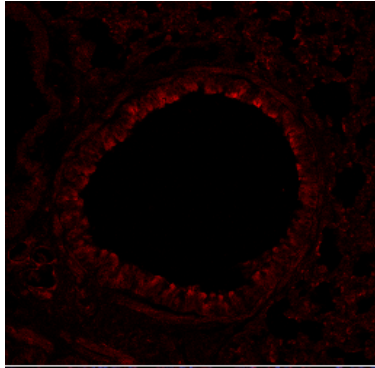


Fig. 4

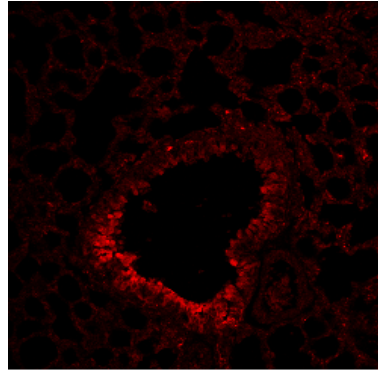
Control

(a)



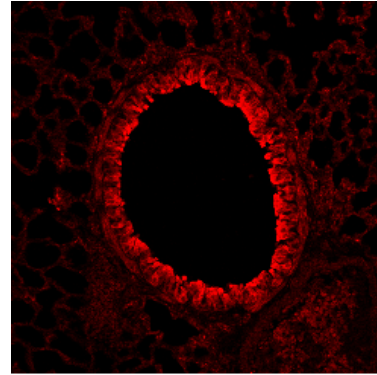
15 min

(b)



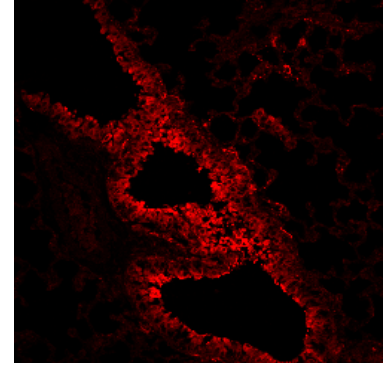
45min

(c)




60min, 3days

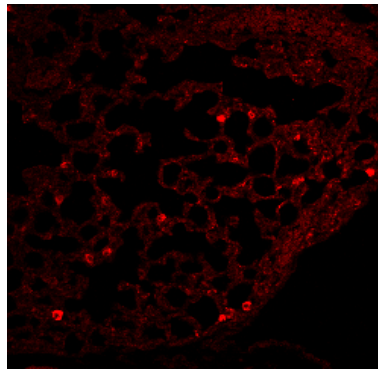
(d)



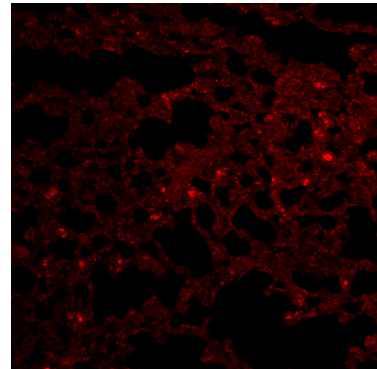
(e)



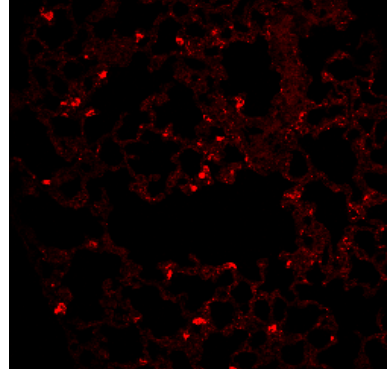
(f)



(g)



(h)



Broncheal tract

Alveolar region