

Picture in Tropical Medicine and Health

Isolation of *Acanthamoeba* Genotype T4 from a Non-Contact Lens Wearer from the Philippines

Corazon C. Buerano^{1,2,3}, Abigail D. Trinidad², Lindsay Sydney N. Fajardo³, Irwin Y. Cua⁴, Michael O. Baclig³ and Filipinas F. Natividad^{3*}

Received 16 June, 2014 Accepted 25 July, 2014 Published online 23 August, 2014

Abstract: We report the case of a 76-year old Filipino male who presented with pain, redness, and blurring of vision of the right eye. Corneal scraping was done and sent to the St. Luke's Research and Biotechnology Group for detection and identification of the infectious agent. Morphological detection was performed by allowing the organism from the scraping to grow in 1.5% non-nutrient agar plate with heat-killed *E. coli*. Trophozoites with acanthopodia and double-walled cysts characteristic of *Acanthamoeba* were observed within the first and second week of observations, respectively. Molecular identification of the amoebae at the genus level based on the presence of *Acanthamoeba*-specific amplicon S1, ASA.S1 confirmed the morphological identification. Genotyping through sequence revealed that the organism belonged to T4, which is the genotype commonly present in the eye of keratitis patients.

Key words: *Acanthamoeba* genotype T4, non-contact lens wearer, Philippines

We report the case of a 76-year old Filipino male from the province of Pampanga who presented with pain, redness, and blurring of vision of the right eye (oculus dexter, OD) on 25 February 2009. One and a half weeks prior to consultation, the patient complained of right eye discharge and lid swelling. He consulted an ophthalmologist and was given unrecalled topical eye medications, but no improvement of symptoms was noted. The patient complained of worsening pain and redness in the right eye. A non-contact lens wearer, he denied any trauma to the right eye. However, he admitted to washing both eyes with tap water. Visual acuity in the right eye was counting fingers at 3 feet. Slit lamp examination showed diffuse conjunctival injection. A ring-like infiltrate was noted in the cornea almost extending to the limbus. Significant anterior chamber cell reaction and hypopyon were also observed. The primary working impression was *Acanthamoeba* keratitis (AK), OD (Fig. 1).

The patient was referred to another ophthalmologist for further evaluation and management. Corneal scraping was done and sent to the St. Luke's Research and Biotechnology Group for detection and identification of the infec-

tious agent. Morphological detection was performed by allowing the organism from the scraping to grow in 1.5% non-nutrient agar (NNA) plate with heat-killed *E. coli*. Trophozoites with acanthopodia and double-walled cysts characteristic of *Acanthamoeba* were observed within the

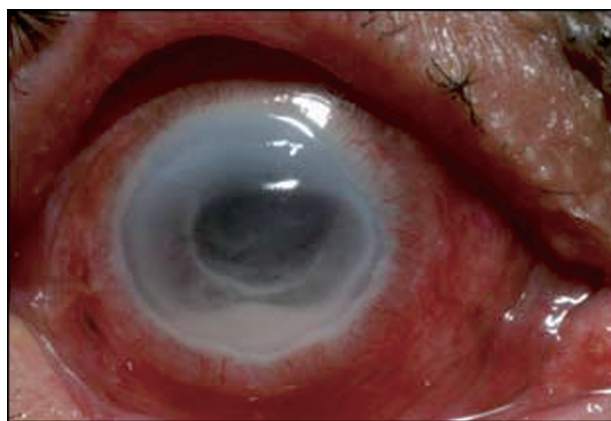


Fig. 1. Ring-like infiltrate in the cornea of the right eye of a clinically diagnosed AK patient.

¹ Department of Virology, Institute of Tropical Medicine, Nagasaki University, Nagasaki, Japan

² Institute of Biology, University of the Philippines, Diliman, Quezon City 1101, Philippines

³ Research and Biotechnology, St. Luke's Medical Center, 279 E. Rodriguez Blvd. Quezon City 1112, Philippines

⁴ Eye Institute, St. Luke's Medical Center, 279 E. Rodriguez Blvd. Quezon City 1112, Philippines

*Corresponding author:

Tel: (632) 727-5540

Fax (632) 726-0467

E-mail: ffnatividad@stluke.com.ph

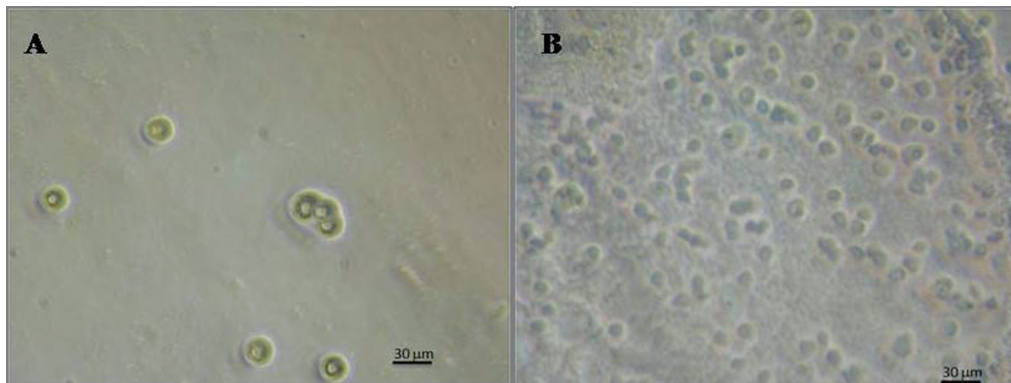


Fig. 2. *Acanthamoeba* cultures in 1.5% NNA plate with heat-killed *E. coli*. A. Doubled-walled cysts and B. Trophozoites.

first and second week of observations, respectively. The isolate was then grown axenically in 2% proteose-peptone, 0.2% yeast 1.8% glucose (PPYG) with 100 units of penicillin G sodium and 100 µg streptomycin sulfate/ml of PPYG (Fig. 2).

The DNA from *Acanthamoeba* isolated from the infected eye of the patient was extracted using the DNeasy Blood and Tissue Kit according to the manufacturer's instructions (Qiagen, Hilden, Germany). PCR amplification was carried out with 1X Phusion HF buffer, 0.2 mM dNTPs, 0.50 µM of genus-specific JDP1 sense (5'-GGCCCAGATCGTTTACCGTGAA-3') and JPD2 (5'-TCTCACAAGCTGCTAGGGGAGTCA-3') antisense primer [1], 0.02 U Phusion DNA polymerase, and PCR-grade water with the following thermal profile: initial denaturation at 95°C for 7 minutes followed by 45 cycles at 95°C for 1 minute, 60°C for 1 minute, 72°C for 2 minutes, and final elongation at 72°C for 10 minutes. The PCR products were purified using the QIAquick PCR Purification Kit according to the manufacturer's protocol (Qiagen, Hilden, Germany). The amplicons were sequenced using an automated sequencer (First BASE Laboratories, Selangor, Malaysia). Sanger dideoxy sequencing of the PCR product was carried out using conserved 892 (5'-CCAAGAATTCACCTCTGAC-3') sense and 892C (5'-GTCAGAGGTGAAATTCTTGG-3') antisense primers to determine the sequence of diagnostic fragment (DF3) of the 18S ribosomal DNA (Rns). Nucleotide sequences were compared for identity with sequences from NCBI utilizing the BLAST program. Molecular identification of the amoebae at the genus level based on the presence of *Acanthamoeba*-specific amplicon S1, ASA.S1 (a partial 18S ribosomal DNA gene) confirmed the morphological identification (Fig. 3) [1, 2]. Genotyping through sequence revealed that the organism belonged to T4, which is the genotype commonly present in the eye of keratitis patients.

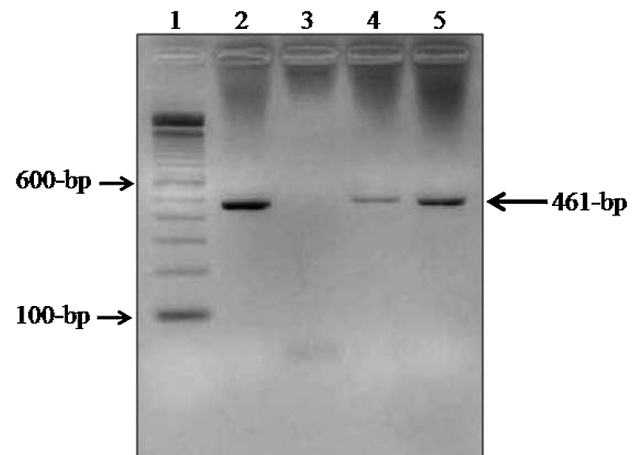


Fig. 3. EZ vision-stained agarose gel showing the amplicons used for the detection of *Acanthamoeba* spp. Lane 1: molecular weight marker; Lane 2: patient sample (this case) positive for *Acanthamoeba* spp (band at 461-bp); Lane 3: negative control; Lane 4: positive control (isolate M21) for *Acanthamoeba* spp; Lane 5: positive control (isolate F04) for *Acanthamoeba* spp.

The nucleotide sequence reported in this study has been deposited to NCBI and can be retrieved under GenBank accession number KJ995957. To the best of our knowledge, this is the first documentation of the genotype of *Acanthamoeba* directly isolated from a non-contact lens wearer patient in the Philippines. However, in 1992, Philippine *Acanthamoeba* isolate IB-1-7 was reported to have been obtained from a patient with keratitis at the Philippine General Hospital. The same report also noted isolation of *Acanthamoeba* from a deep-well water source in Quezon City. These two previously reported isolates were not genotyped [3].

Acanthamoeba is one of the leading causes of keratitis, a painful sight-threatening corneal infection. The ma-

jority of AK strains are associated with genotype T4, but AK strains belonging to other genotypes have also been reported worldwide [4–5]. In the Philippines, *Acanthamoeba* isolates from contact lens wearers were found to be either genotype T4 or T5 [6]. AK cases mostly occur in contact lens wearers and people with a history of ocular trauma. The free-living amoeba is also responsible for life-threatening infections such as granulomatous amebic encephalitis, a fatal disease of the central nervous system seen among immuno-compromised patients [7].

Non-contact lens wearers comprised 3% to 15% of AK cases in the United Kingdom and United States [8]. Recently, it was reported that 27% of the recreational water samples collected in Batangas and Pampanga, Philippines were positive for *Acanthamoeba* by PCR. *Acanthamoeba* spp. was found in river, pond, lake, and tap water samples from the said provinces [9]. This study corroborates and extends previous findings which showed that risk factors other than contact lens wear, corneal trauma and contamination of the water supply can predispose infection [2, 5].

Based on the clinical findings and laboratory results, the final diagnosis was AK. The patient was treated with chlorhexidine. The corneal infection subsided and was resolved after two months of treatment. A corneal scar was noted and corneal transplant contemplated, but the patient was lost to follow-up.

ACKNOWLEDGMENTS

This study was supported by St. Luke's Medical Center through the Research and Biotechnology Group, with the collaboration of the St. Luke's Eye Institute.

REFERENCES

1. Schroeder JM, Booton GC, Hay J, et al. Use of subgenomic 18S ribosomal DNA PCR and sequencing for genus and genotype identification of *Acanthamoeba* from humans with keratitis and from sewage sludge. *J Clin Microbiol* 2001; 39(5): 1903–1911.
2. Booton GC, Kelly DJ, Chu YW, et al. 18S ribosomal DNA typing and tracking of *Acanthamoeba* species isolates from corneal scrape specimens, contact lenses, lens cases, and home water supplies of *Acanthamoeba* keratitis patients in Hong Kong. *J Clin Microbiol* 2002; 40(5): 1621–1625.
3. Lagmay JP, Matias RR, Natividad FF, et al. Cytopathogenicity of *Acanthamoeba* isolates on rat glial C6 cell line. *Southeast Asian J Trop Med Public Health* 1999; 30(4): 670–677.
4. Ledee DR, Iovieno A, Miller D, et al. Molecular identification of T4 and T5 genotypes in isolates from *Acanthamoeba* keratitis patients. *J Clin Microbiol* 2009; 47(5): 1458–1462.
5. Ertabaklar H, Türk M, Dayanir V, et al. *Acanthamoeba* keratitis due to *Acanthamoeba* genotype T4 in a non-contact-lens wearer in Turkey. *Parasitol Res* 2007; 100(2): 241–246.
6. Rivera WL, Adao DE. 18S ribosomal DNA genotypes of *Acanthamoeba* species isolated from contact lens cases in the Philippines. *Parasitol Res* 2009; 105(4): 1119–1124.
7. Marciano-Cabral F, Cabral G. *Acanthamoeba* spp. as agents of disease in humans. *Clin Microbiol Rev* 2003; 16(2): 273–307.
8. Dart JK, Saw VP, Kilvington S. *Acanthamoeba* keratitis: Diagnosis and treatment update 2009. *Am J Ophthalmol* 2009; 148(4): 487–499.
9. Onichandran S, Kumar T, Salibay CC, et al. Waterborne parasites: A current status from the Philippines. *Parasit Vectors* 2014; 7: 244.