

Spontaneous Spiral Dissection of Left Internal Thoracic Artery Graft

Combined Assessment by Optical Coherence Tomography and Intravascular Ultrasound

Seiji KOGA,¹ MD, Satoshi IKEDA,¹ MD, Tomoo NAKATA,¹ MD, and Koji MAEMURA,¹ MD

SUMMARY

The left internal thoracic artery (LITA) is considered the most reliable coronary artery bypass grafting conduit due to its high rate of long-term patency. LITA grafts are extremely durable and associated complications are infrequent. We present a case with spontaneous spiral dissection of a LITA graft to the left anterior descending artery, which was assessed by optical coherence tomography (OCT) and intravascular ultrasound (IVUS). OCT was superior in visualizing the disrupted flap, false lumen, and intramural hematoma, but it did not visualize the full extent of the vessel wall. In contrast, IVUS allowed more complete and deeper vessel visualization, and thus better appreciation of the extent of intramural hematoma. Combined use of these two modalities provides complementary details on imaging of a LITA dissection. (Int Heart J 2015; 56: 360-362)

Key words: Coronary artery bypass, Intravascular imaging, Coronary artery disease

The left internal thoracic artery (LITA) is considered the gold standard coronary artery for a bypass graft due to its high rate of long-term patency and large survival impact compared with saphenous vein grafts.^{1,2)} The characteristics of the LITA including its elastomuscular composition and its well-known resistance to atherosclerosis are thought mainly to account for these favorable results.³⁾ LITA grafts are extremely durable and complications associated with them are infrequent. Here, we present a case with spontaneous spiral dissection in the body of the LITA graft evaluated by optical coherence tomography (OCT) and intravascular ultrasound (IVUS).

CASE REPORT

A 69-year-old man with angina pectoris underwent coronary artery bypass grafting (CABG) with a LITA graft to the left anterior descending artery (LAD) and a saphenous vein graft to the right coronary artery. Mobilization of the LITA from the chest wall was uneventful and no other procedural troubles were encountered during the bypass surgery. He had a history of hypertension, hypercholesterolemia, and hyperuricemia, but no history of chest trauma. He also had a history of acute myocardial infarction treated by plain old balloon angioplasty 16 years previously.

Seven days after CABG surgery, computed tomographic angiography was performed to examine the patency of the by-

pass grafts. The saphenous vein graft to the right coronary artery was patent, but a focal stenosis in the mid-portion of the LITA graft was identified (Figure 1). To confirm the diagnosis, we performed coronary angiography. Selective angiography of the LITA graft showed severe irregular stenosis suggesting dissection in the mid-portion of its body (Figure 2A). The orifice of the LITA graft and distal anastomosis site to the left anterior descending artery were intact. For further examination, IVUS and OCT were performed to evaluate the detailed morphology of the angiographic stenosis. IVUS (Atlantis SR Pro 2. Boston Scientific, Natick, MA, USA) of the lesion demonstrated an intramural hematoma; however, disrupted sites in the dissection flap were not detected (Figure 2B, 1-5). In contrast, OCT (M2 OCT Imaging System, LightLab Imaging Inc., Westford, MA, USA) clearly showed a spiral dissection with two disrupted flaps and intramural hematoma (Figure 2C, 1-5). Notably, two false lumens extending proximally and distally from two disrupted flap sites were clearly identified in the longitudinal OCT view (Figure 2D). This lesion was subsequently treated successfully with implantation of a zotarolimus-eluting stent (Endeavor 2.75 × 30 mm. Medtronic CardioVascular, Santa Rosa, CA, USA).

DISCUSSION

LITA grafts have shown superior patency rates compared to saphenous vein grafts. When anastomosed to the left arteri-

From the ¹ Department of Cardiovascular Medicine, Nagasaki University Graduate School of Biomedical Sciences, Nagasaki, Japan.

Address of correspondence: Satoshi Ikeda, MD, Department of Cardiovascular Medicine, Nagasaki University Graduate School of Biomedical Sciences, 1-7-1 Sakamoto, Nagasaki 852-8501, Japan. Email: sikeda@nagasaki-u.ac.jp

Received for publication December 10, 2014. Revised and accepted December 17, 2014.

Released in advance online on J-STAGE April 23, 2015.

All rights reserved by the International Heart Journal Association.

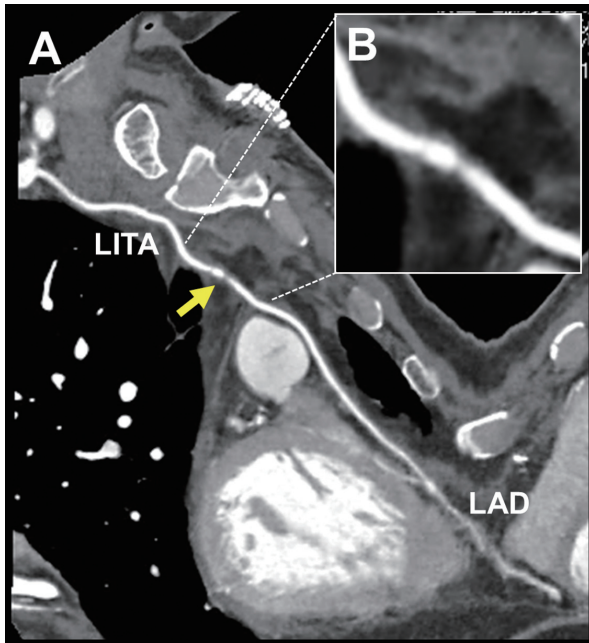


Figure 1. **A:** Computed tomographic angiography showed a focal stenosis (yellow arrow) in the mid-portion of the left internal thoracic artery (LITA) graft to the left anterior descending artery (LAD). **B:** Magnified image of a stenosis in the LITA graft.

or descending artery, LITA grafts are very favorable over a 10-year period.^{1,2)} The most common site of stenosis in the LITA graft is the distal anastomosis.⁴⁾ On the other hand, graft failure of LITA itself is rare but can occur. Manipulation of the LITA graft during the surgical procedure is the most common cause of graft failure.^{5,6)} This may occur while harvesting the graft from the chest wall and during creation of the anastomotic site.⁷⁾ Graft failure requiring revascularization may be due to atherosclerotic disease, thrombus formation, or intimal proliferation.^{5,7)} LITA graft dissection is very rare as a cause of graft failure. Extensive kinking of the LITA during the surgical procedure or strenuous physical movement has been reported as a possible cause of LITA dissection.^{8,9)} In particular, dissection in the proximal portion of the LITA appearing soon after surgery is most likely to be caused by kinking of the LITA during surgical mobilization or occasionally a surgical clip.¹⁰⁾ In the present case, there were no procedural troubles during manipulation of the LITA graft during the bypass surgery. Furthermore, the patient did not undertake any strenuous exercise or experience trauma to his chest after the bypass surgery. Thus, potential factors that contributed to development of the spontaneous LITA dissection remain unknown.

We evaluated LITA graft dissection using OCT and IVUS. OCT is an innovative intravascular imaging tool that can be used to examine coronary atherosclerotic lesions at a resolution (10–15 μm) that far exceeds existing standards, such as IVUS.¹¹⁾ The strength of OCT lies in its ability to clearly visualize the surface of the vessel lumen,¹²⁾ although it cannot visualize the deeper areas of the vessel wall due to its shallow penetration depth (1 to 2 mm).¹³⁾ In addition, OCT is not able to image through blood, and thus image acquisition requires that the blood be cleared from the coronary artery.¹⁴⁾ In the

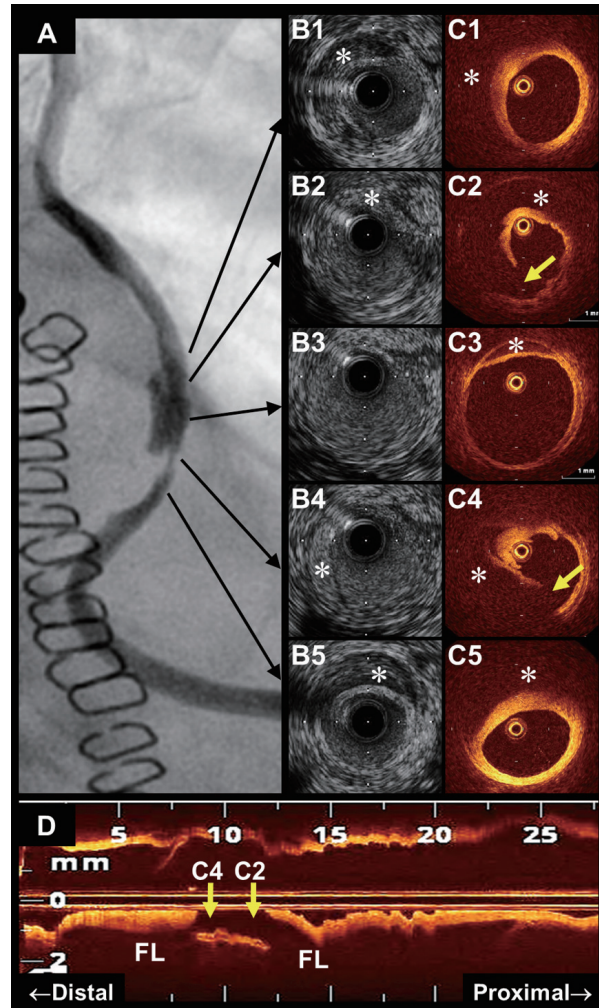


Figure 2. **A:** Angiography revealed severe stenosis that suggested dissection in the mid-portion of the left internal thoracic artery (LITA) graft. **B1-B5:** Intravascular ultrasonography showed intramural hematoma (*), but disruptions of the dissection flap were not detected. **C1-C5:** Optical coherence tomography (OCT) clearly showed intramural hematoma (*) and two disrupted dissection flaps (yellow arrows) at separate sites. Full images of the vessel wall were not seen in part because of attenuation caused by intramural hematoma on OCT. **D:** Longitudinal OCT image showed two false lumens (FL) extending proximally and distally from two disrupted sites (yellow arrows) corresponding to C2 and C4, respectively.

present study, both imaging techniques could depict the false lumen/intramural hematoma. Although OCT was superior to IVUS in the identification of disrupted flaps, a full image of the vessel wall could not be seen in some areas because of residual blood, attenuation, or insufficient penetration. On the other hand, IVUS did not delineate the lumen-intimal interface sharply, but it enabled more complete vessel visualization in larger intramural hematoma areas compared to OCT. Thus, combined use of OCT and IVUS can provide more valuable and complementary diagnostic information to understand the structural image of LITA graft dissection.

In conclusion, we have presented a case with spontaneous spiral dissection in the body of a LITA graft. Combined use of OCT and IVUS may provide valuable and complementary di-

agnostic insights on the potential mechanisms underlying the development of LITA dissection.

REFERENCES

1. Goldman S, Zadina K, Moritz T, *et al.* Long-term patency of saphenous vein and left internal mammary artery grafts after coronary artery bypass surgery: results from a Department of Veterans Affairs Cooperative Study. *J Am Coll Cardiol* 2004; 44: 2149-56.
2. Nicolini F, Agostinelli A, Spaggiari I, *et al.* Current trends in surgical revascularization of multivessel coronary artery disease with arterial grafts. *Int Heart J* 2014; 55: 381-5. (Review)
3. Porto I, Gaudino M, De Maria GL, *et al.* Long-term morphofunctional remodeling of internal thoracic artery grafts: a frequency-domain optical coherence tomography study. *Circ Cardiovasc Interv* 2013; 6: 269-76.
4. Ishizaka N, Ishizaka Y, Ikari Y, *et al.* Initial and subsequent angiographic outcome of percutaneous transluminal angioplasty performed on internal mammary artery grafts. *Br Heart J* 1995; 74: 615-9.
5. Shelton ME, Forman MB, Virmani R, Bajaj A, Stoney WS, Atkinson JB. A comparison of morphologic and angiographic findings in long-term internal mammary artery and saphenous vein bypass grafts. *J Am Coll Cardiol* 1988; 11: 297-307.
6. Bourassa MG, Fisher LD, Campeau L, Gillespie MJ, McConney M, Lespérance J. Long-term fate of bypass grafts: the Coronary Artery Surgery Study (CASS) and Montreal Heart Institute experiences. *Circulation* 1985; 72: V71-8. (Review)
7. Ziaee A, Puri S, Kern MJ. Stenting for spontaneous left internal mammary artery dissection: a case report. *Catheter Cardiovasc Interv* 2003; 60: 389-91.
8. Koutouzis M, Mavrogeni S, Nikolidakis S, Lazaris E, Kyriakides ZS. Multislice computed tomographic angiography of a spontaneous left internal mammary graft dissection. *Int J Cardiol* 2007; 114: 384-5.
9. Freixa X, Gallo R. Internal thoracic artery dissection: a proposed mechanistic explanation. *JACC Cardiovasc Interv* 2013; 6: 533-4.
10. Suresh V, Evans S. Successful stenting of stenotic lesion and spontaneous dissection of left internal mammary artery graft. *Heart* 2007; 93: 44.
11. Otsuka F, Joner M, Prati F, Virmani R, Narula J. Clinical classification of plaque morphology in coronary disease. *Nat Rev Cardiol* 2014; 11: 379-89. (Review)
12. Imamura T, Kinugawa K, Murasawa T, *et al.* Cardiac allograft vasculopathy can be distinguished from donor-transmitted coronary atherosclerosis by optical coherence tomography imaging in a heart transplantation recipient: double layered intimal thickness. *Int Heart J* 2014; 55: 178-80.
13. Waksman R, Kitabata H, Prati F, Albertucci M, Mintz GS. Intravascular ultrasound versus optical coherence tomography guidance. *J Am Coll Cardiol* 2013; 62: S32-40. (Review)
14. Johnson PM, Patel J, Yeung M, Kaul P. Intra-coronary imaging modalities. *Curr Treat Options Cardiovasc Med* 2014; 16: 304.