

**Secondary Bone Grafting with Simultaneous Auto-Tooth Transplantation to  
the Alveolar Cleft**

Kei-ichiro Miura, DDS, PhD<sup>a,b</sup>, Masashi Yoshida, DDS, PhD<sup>b</sup>, and Izumi  
Asahina, DDS, PhD<sup>a</sup>

5       <sup>a</sup>Department of Regenerative Oral Surgery, Unit of Translational Medicine,  
Nagasaki University Graduate School of Biomedical Sciences, Nagasaki,  
Japan.

<sup>b</sup>Department of Oral Surgery, Imakiire General Hospital, Kagoshima,  
Japan.

10       Corresponding author: Izumi Asahina, DDS, PhD

Address: 1-7-1, Sakamoto, Nagasaki, Japan 852-8588

Fax number: +81-095-819-7705

Tel number: +81-095-819-7704

E-mail address: [asahina@nagasaki-u.ac.jp](mailto:asahina@nagasaki-u.ac.jp)

15       Running title: SECONDARY BONE GRAFTING WITH AUTO-TOOTH  
TRANSPLANTATION.

## **Abstract**

One of the most important purposes of secondary bone grafting of the alveolar cleft is to stabilize the maxillary alveolar arch with completion of the dental arch. We report here a case of secondary bone grafting with simultaneous auto-tooth transplantation to the alveolar cleft, using particulate cancellous bone and marrow (PCBM) combined with platelet-rich plasma (PRP), which contains many growth factors. The patient was born with a bilateral cleft lip and left buccal-localized cleft alveolus. We performed a bone grafting to the cleft using PCBM with PRP, and a transplantation of the supernumerary tooth under general anesthesia at 11 years and 10 months of age. The postoperative course was uneventful and without any complications. Orthodontic treatment was nearly complete 10 months after the operation. The transplanted tooth was stable, and normal gingival contour was attained over the 2-year follow-up period. The case was successful in achieving a stable occlusal condition in a short period of time. We suggest the secondary bone grafting with simultaneous

auto-tooth transplantation as an option for alveolar cleft treatment.

## **Introduction**

Major purposes of secondary bone grafting to the alveolar cleft includes closing the oronasal fistula[1], improving alveolar ridge height [2],

5 promoting tooth eruption adjacent to the cleft, and stabilizing the maxillary alveolar arch with the completion of the dental arch, which provides long-term stability of the occlusal condition.

Orthodontic treatment of the displaced or impacted teeth[3, 4] is usually performed to establish the dental arch; however, the permanent tooth that  
10 should erupt into the cleft is occasionally congenitally missing[5]. Prosthetic appliance[6], dental implants[7, 8], or auto-tooth transplantation[5, 9] are alternatives for the missing tooth. Among these, auto-tooth transplantation is superior because it provides stable periodontal tissue, resulting in a local environment that promotes the longevity of the dentition.

15 If the tooth is available, it is favorable to the patient that tooth placement is completed simultaneously with bone grafting. Furthermore, the

transplanted tooth may prevent resorption of the grafted bone, which generally occurs due to the lack of functional stress, leading to an insufficient amount of alveolar bone to complete the dentition[10].

We report here a case of secondary bone grafting with simultaneous auto-tooth transplantation to the alveolar cleft, using particulate cancellous bone and marrow (PCBM) combined with platelet-rich plasma (PRP), which contains many growth factors and increases bone formation [1].

### **Case Report**

The patient was born with a bilateral cleft lip and a left buccal-localized cleft alveolus. Left and right lip closures were performed by Cronin procedure at 3 and 6 months of age, respectively. Occlusal management was started by an orthodontist at 3 years of age and a wait-and-see approach was taken for the left cleft alveolus. Later, a bone graft to the patient's left alveolar cleft was planned for at 11 years of age.

Extra-orally, the alinasal deformity was slight, and a linear scar was observed at the left upper lip (Fig. 1). Intra-orally, a trough-like depression

was observed at the cleft alveolus falling under the position of the left upper lateral incisor and connecting to the palatal bone. A supernumerary tooth was identified behind the upper right lateral incisor (Fig. 2). Occlusal radiograph and panoramic radiograph showed the cleft alveolus between the left upper central incisor and canine. A radiolucent area, which indicates a nasopalatal fistula, was observed (Fig. 3). Three-dimensional imaging from computed tomography (3D-CT) showed the cleft alveolus between the left upper central incisor and canine (Fig. 4). At 11 years and 10 months of age, we performed a bone grafting to the cleft using PCBM from the iliac bone with PRP, and transplantation of the supernumerary tooth under general anesthesia. IRB at Imaki-ikre General Hospital approved the procedure. An intracrevicular incision was made and a mucoperiosteal flap was elevated (Fig. 5A, 5B). PRP was separated from venous blood by centrifugation, and PCBM was harvested from ilium bone. PRP was then added to the PCBM (Fig. 5C). PCBM with PRP was packed into the alveolar cleft and the extracted supernumerary tooth was

transplanted into the cleft. The wound was closed with tension-free mucoperiosteal flaps (Fig. 5D, 5E). An orthodontic bracket was applied to the transplanted tooth and fixed to the main wire.

The postoperative course was uneventful and without any complications.

5 Orthodontic alignment of the transplanted tooth was initiated 1 month postoperatively (Fig. 6). Orthodontic treatment was nearly complete 10 months after the operation. The grafted bone and transplanted tooth were in good condition 1 year and 2 months postoperatively (Fig. 7).

10 Occlusal radiograph revealed the bone-grafted site had become more radiopaque. Periodontal space and lamina dura were observed around the tooth, and root resorption was not seen (Fig. 8). 3D-CT images showed new bone formation at the cleft area and closure of the space between the floor of the nasal cavity and oral cavity (Fig. 9). After 2 years and 3 months, stability of the transplanted tooth was normal and a relatively normal gingival contour was attained. There were no signs of infection, such as 15 discharge of pus, reddening of the gingiva, or tenderness of the apical area

(Fig. 10).

## Discussion

In the present case, an auto-transplanted tooth was successfully taken into

5 PCBM grafted into the alveolar cleft, and the permanent dentition was

completed after orthodontic treatment. Lamina dura was observed

radiographically, indicating the proper formation of the periodontal

ligament. It is well known that PCBM contains not only osteoprogenitor

cells but also mesenchymal stem cells; these cells along with periodontal

10 ligament cells from the transplanted tooth may synergistically generate the

complicated periodontal tissue.

Simultaneous auto-tooth transplantation with bone grafting has additional

advantages. First, only a relatively short period of time, 10 months, was

required after surgery to complete the dentition; simultaneous formation of

15 alveolar bone and periodontal ligament may reduce the duration of the

treatment. Second, neither root resorption nor ankylosis were observed in

the present case, despite being known complications of auto-tooth transplantation [11, 12]. This is because there was no compression of the periodontal ligament in the soft PCBM host bed.

PCBM is widely utilized for secondary bone grafting because it is easy to harvest in a sufficient amount and possesses high osteoinductive ability.

Despite these advantages of PCBM, resorption of newly formed bone may occur, and the height and width of the regenerated residual ridge may decrease unless functional stress is applied to the transplanted site [13, 14].

In the present case, there was no bone resorption either in the height or width of the newly formed bone. The transplanted tooth may have provided the required functional stress. The early formation of viable periodontal ligament may also have prevented bone resorption.

We used PRP to promote new bone formation. It has been reported that PRP in conjunction with autogenous bone significantly increases the activity of osteoprogenitor cells [15, 16], because PRP contains many growth factors such as PDGF, TGF- $\beta$ , and vascular endothelial growth factor



(VEGF) [17]. On the other hand, it has also been reported that PRP application does not have a significant benefit for bone regeneration[18, 19]. However, even if PRP does not provide a benefit for secondary bone grafting, it does not prevent bone formation[13]. Furthermore, PRP promotes easier handling of PCBM due to the fibrin in PRP working as a “glue” to bind the bone chips together. Additionally, the narrow alveolar cleft, sufficient grafted bone, and a thick palatal bone may have contributed to the successful result of the present case.

Although the treatment showed in this report was a single case, this treatment may be successful with careful selection of the case, which should have the adequate supernumerary tooth, and attentive procedure. Points which may have contributed to the success of the case include sufficient volume of grafted bone, compact and tight graft of PCBM, unscathed periodontal ligament of the transplant tooth, and the absence of excess occlusal interference by lower incisor teeth. SBG is usually performed before the eruption of capsid, this procedure is more suitable to apply after

the eruption. So further studies are needed to clarify the efficiency of this treatment, keeping in mind that this is a single case report.

We showed in the present case successful treatment with alveolar bone grafting and simultaneous auto-tooth transplantation. Although a new practice, we suggest this treatment as an option with many advantages for treatment of alveolar cleft and also assume that the idea may be applied to alveolar bone reconstruction after cystectomy or tumor resection.

There is no conflict of interest concerning this report.

## References

1. Rullo R, Festa VM, Guida L, Laino G: Bone grafting with platelet-rich plasma in alveolar cleft. Case report. *Minerva Stomatol* 56:63, 2007

2. Long RE, Jr., Paterno M, Vinson B: Effect of cuspid positioning in the cleft at the time of secondary alveolar bone grafting on eventual graft

success. *Cleft Palate Craniofac J* 33:225, 1996

3. Freitas JA, Garib DG, Oliveira M, Lauris Rde C, Almeida AL, Neves LT, Trindade-Suedam IK, Yaedu RY, Soares S, Pinto JH: Rehabilitative treatment of cleft lip and palate: experience of the Hospital for

5 Rehabilitation of Craniofacial Anomalies-USP (HRAC-USP)--part 2: pediatric dentistry and orthodontics. *J Appl Oral Sci* 20:268, 2012

4. Peamkaroonrath C, Manosudprasit M, Godfrey K: Assisted eruption of impacted teeth into an alveolar bone graft in a patient with cleft lip and palate. *Aust Orthod J* 24:149, 2008

10 5. Aizenbud D, Zaks M, Abu-El-Naaj I, Rachmiel A, Hazan-Molina H: Mandibular premolar autotransplantation in cleft affected patients: the replacement of congenital missing teeth as part of the cleft patient's treatment protocol. *J Craniomaxillofac Surg* 41:371, 2013

15 6. Reisberg DJ: Dental and prosthodontic care for patients with cleft or craniofacial conditions. *Cleft Palate Craniofac J* 37:534, 2000

7. Hartel J, Pogl C, Henkel KO, Gundlach KK: Dental implants in

alveolar cleft patients: a retrospective study. *J Craniomaxillofac Surg*

27:354, 1999

8. Wermker K, Jung S, Joos U, Kleinheinz J: Dental implants in cleft

lip, alveolus, and palate patients: a systematic review. *Int J Oral Maxillofac*

5 *Implants* 29:384, 2014

9. Luvizuto ER, Faco EF, Faco RS, Queiroz TP, Margonar R,

Betoni-Junior W, Camara KA, Assuncao WG: Bone augmentation and

autogenous transplantation of premolar to the site of the fissure in a cleft

palate patient. *Dent Traumatol* 29:483, 2013

10 10. Oyama T, Nishimoto S, Tsugawa T, Shimizu F: Efficacy of

platelet-rich plasma in alveolar bone grafting. *J Oral Maxillofac Surg*

62:555, 2004

11. Hermann NV, Lauridsen E, Ahrensburg SS, Gerds TA, Andreasen

JO: Periodontal healing complications following concussion and subluxation

15 injuries in the permanent dentition: a longitudinal cohort study. *Dent*

*Traumatol* 28:386, 2012

12. Hermann NV, Lauridsen E, Ahrensburg SS, Gerds TA, Andreasen JO: Periodontal healing complications following extrusive and lateral luxation in the permanent dentition: a longitudinal cohort study. Dent Traumatol 28:394, 2012

5 13. Lee C, Nishihara K, Okawachi T, Iwashita Y, Majima HJ, Nakamura N: A quantitative radiological assessment of outcomes of autogenous bone graft combined with platelet-rich plasma in the alveolar cleft. Int J Oral Maxillofac Surg 38:117, 2009

10 14. Giudice G, Gozzo G, Sportelli P, Gargioli F, De Siate A: The role of functional orthodontic stress on implants in residual alveolar cleft. Plast Reconstr Surg 119:2206, 2007

15. Marx RE, Carlson ER, Eichstaedt RM, Schimmele SR, Strauss JE, Georgeff KR: Platelet-rich plasma: Growth factor enhancement for bone grafts. Oral Surg Oral Med Oral Pathol Oral Radiol Endod 85:638, 1998

15 16. Marx RE: Platelet-rich plasma: evidence to support its use. J Oral Maxillofac Surg 62:489, 2004

17. Pierce GF, Tarpley JE, Yanagihara D, Mustoe TA, Fox GM, Thomason A: Platelet-derived growth factor (BB homodimer), transforming growth factor-beta 1, and basic fibroblast growth factor in dermal wound healing. Neovessel and matrix formation and cessation of repair. Am J Pathol 140:1375, 1992

18. Klongnoi B, Rupprecht S, Kessler P, Thorwarth M, Wiltfang J, Schlegel KA: Influence of platelet-rich plasma on a bioglass and autogenous bone in sinus augmentation. An explorative study. Clin Oral Implants Res 17:312, 2006

19. Klongnoi B, Rupprecht S, Kessler P, Zimmermann R, Thorwarth M, Pongsiri S, Neukam FW, Wiltfang J, Schlegel KA: Lack of beneficial effects of platelet-rich plasma on sinus augmentation using a fluorohydroxyapatite or autogenous bone: an explorative study. J Clin Periodontol 33:500, 2006

## Figure legends

Figure 1: The alinasal deformity is slight, and a linear scar is observed at the upper left lip.

Figure 2: A trough-like depression is seen at the cleft alveolus falling under the area of the upper left lateral incisor (A), and the depression connects to the palatal bone (B).

Figure 3: Occlusal radiograph (A) and panoramic radiograph (B) shows the cleft alveolus between the upper left central incisor and upper left canine. A radiolucent area, suggestive of a nasopalatal fistula, is shown.

Figure 4: Three-dimensional imaging from computed tomography (3D-CT) shows the cleft alveolus between the upper left central incisor and upper left canine.

Figure 5: An intracrevicular incision (A) was made and a mucoperiosteal flap was elevated (B). PCBM was added to the PRP (C). The extracted supernumerary tooth (D) was transplanted into the cleft, then closed with tension-free mucoperiosteal flaps (E).

Figure 6: Orthodontic alignment of the transplanted tooth was initiated 1 month postoperatively.

Figure 7: The grafted bone and transplanted tooth were in good condition 1 year and 2 months postoperatively.

5 Figure 8: Periodontal space and lamina dura are observed around the tooth, and root resorption is not seen.

Figure 9: 3D-CT images show new bone formation at the cleft area and closure of the space between the floor of the nasal cavity and oral cavity.

10 Figure 10: After 2 years and 3 months, stability of the transplanted tooth was normal and a normal gingival contour was attained. There were no signs of infection, such as discharge of pus, reddening of the gingiva, or tenderness of the apical area.



5

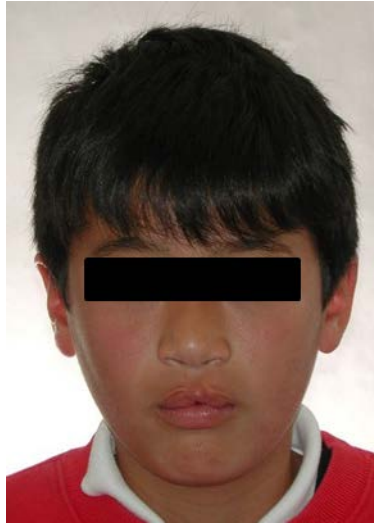
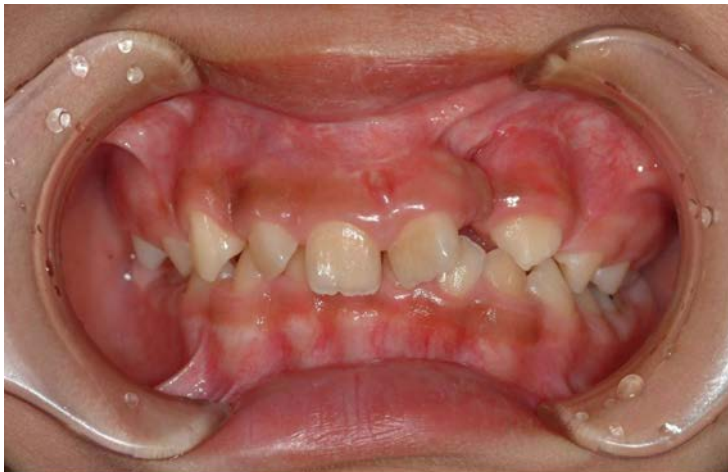
Figure 1

10



15

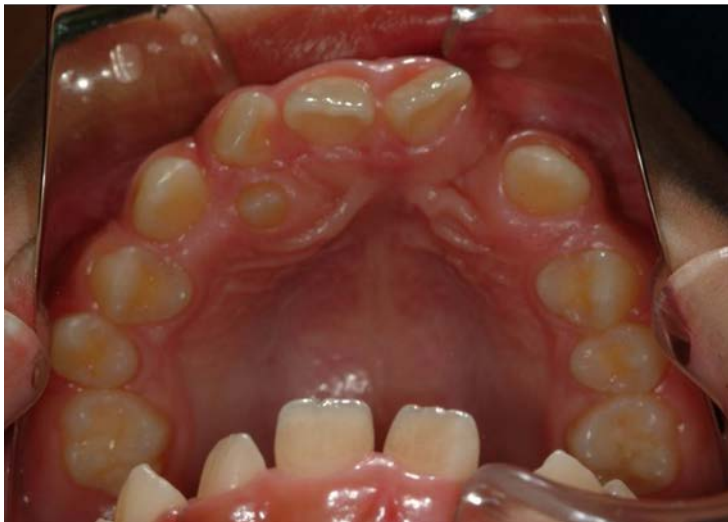

Figure 2

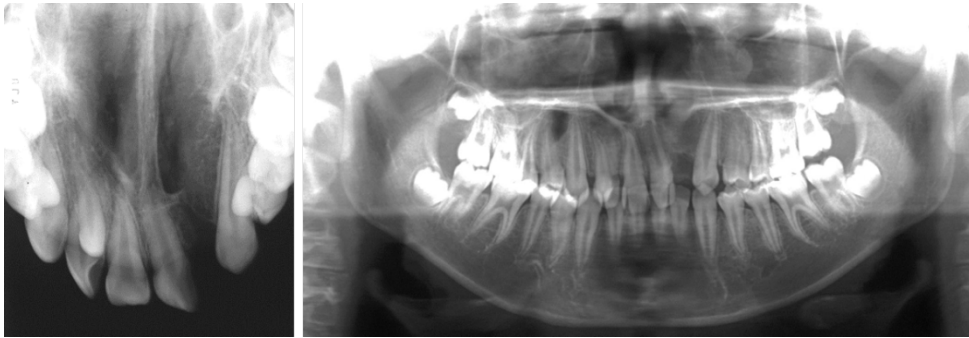

Figure 3

5

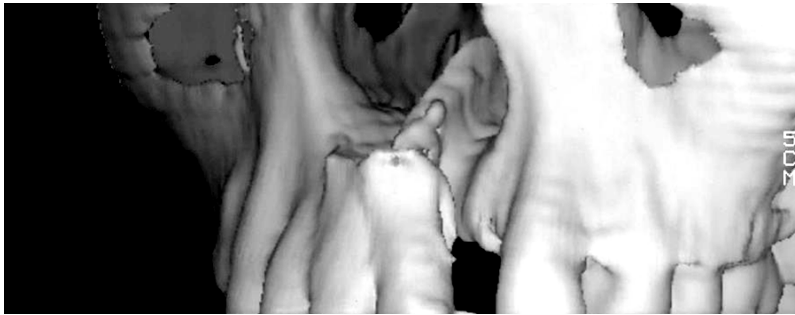
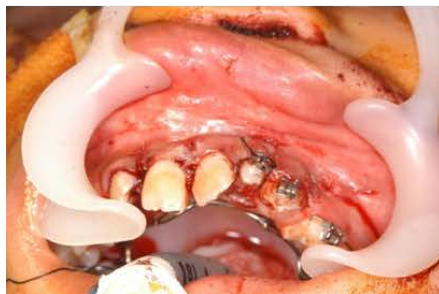
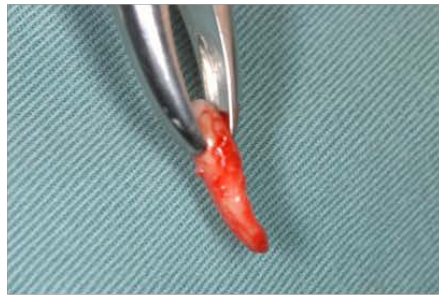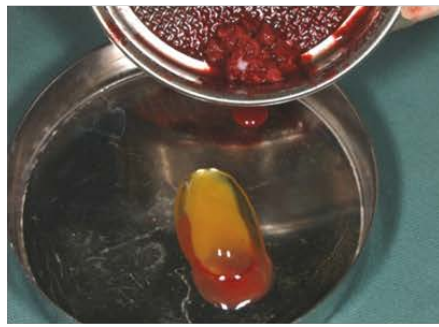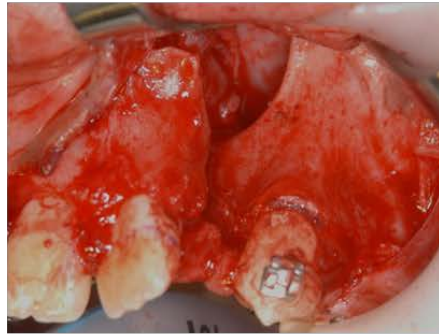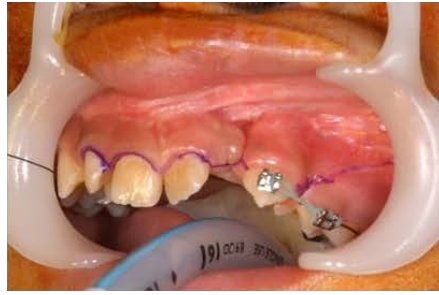Figure 4

10

15

5



10

15

Figure 5

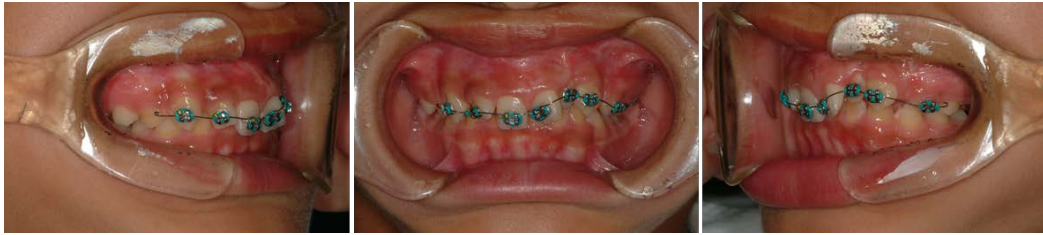

Figure 6

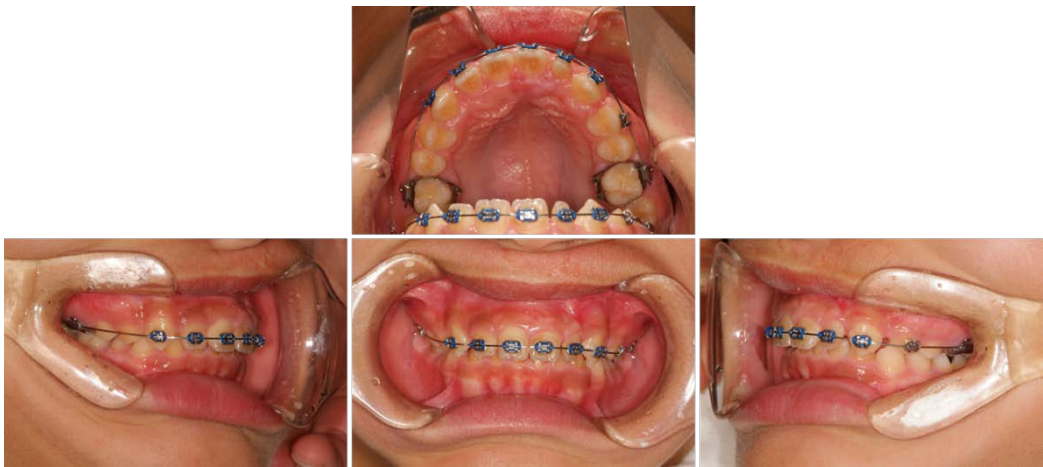
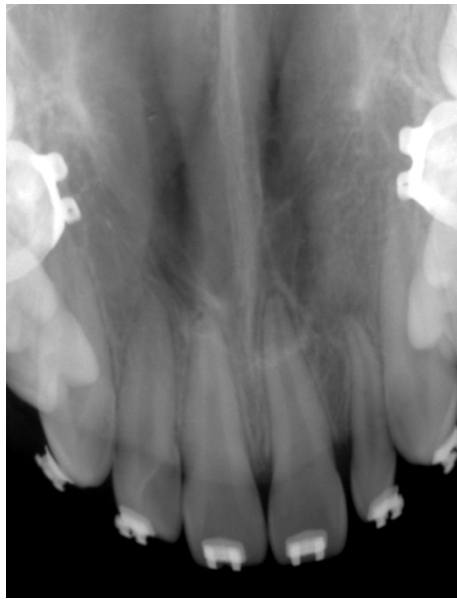

Figure 7

5



10

Figure 8

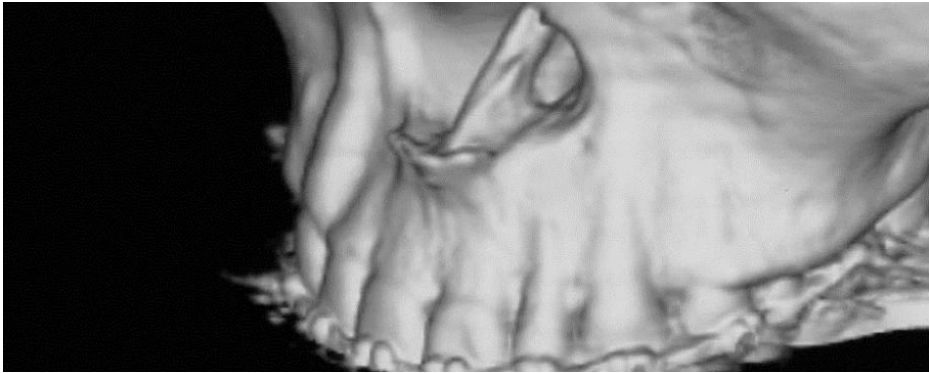


Figure 9

5

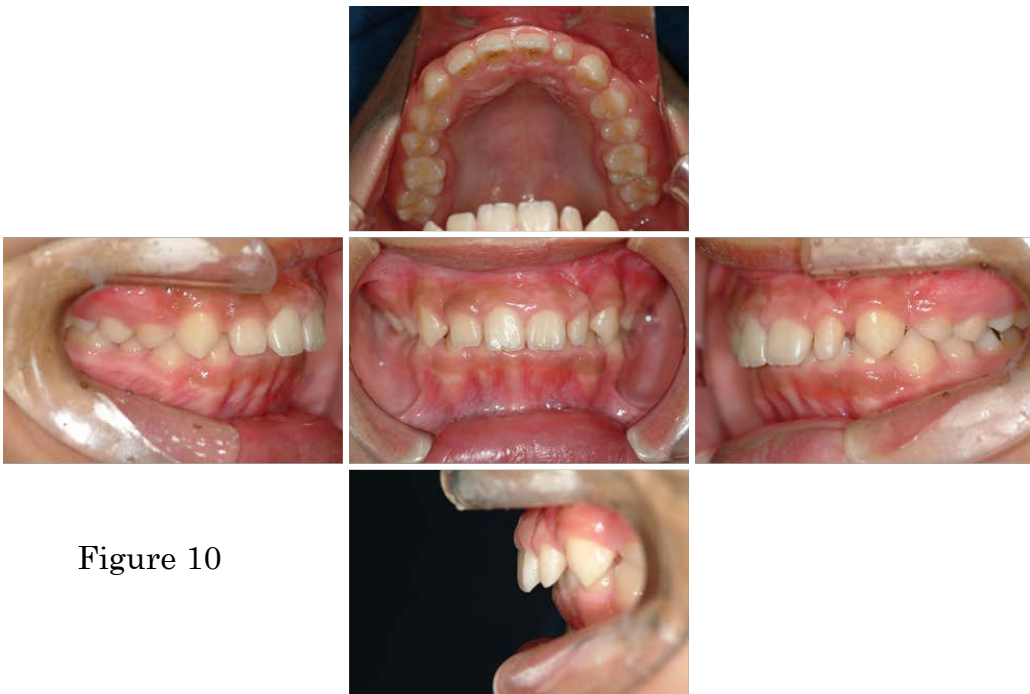

Figure 10

10