

Section: How I do it

Title: Low-Cost High-Speed Imaging System for Observing Vocal Fold Vibration in  
Voice Disorders

Kenichi Kaneko<sup>a</sup>, Koichi Sakaguchi<sup>a</sup>, Masato Inoue<sup>b</sup>, and Haruo Takahashi<sup>a</sup>

<sup>a</sup>Department of Otolaryngology-Head and Neck Surgery, Nagasaki University Graduate  
School of Biomedical Sciences, Nagasaki, Japan

<sup>b</sup>Department of Electrical Engineering and Bioscience, School of Advanced Science and  
Engineering, Waseda University, Tokyo, Japan

Corresponding author:

Kenichi Kaneko, MD, PhD

Department of Otolaryngology-Head and Neck Surgery, Nagasaki University Graduate  
School of Biomedical Sciences, 1-7-1 Sakamoto, Nagasaki, Japan

Tel: +81-95-819-7349

Fax: +81-95-819-7352

Email: [kkaneko@nagasaki-u.ac.jp](mailto:kkaneko@nagasaki-u.ac.jp)

Keywords: High-speed digital videoimaging, Laryngostroboscopy, Vocal fold vibration,

Voice disorders

## Abstract

**Purpose:** The aim of this study was to establish a method to observe vocal fold vibration using a low-cost high-speed laryngeal imaging system.

**Procedures:** We assembled a high-speed imaging system with a consumer digital camera and a rigid laryngeal endoscope. The camera can shoot digital images at a rate of 1,200 frames per second and be purchased for about \$US1000 in Japan.

**Results:** We examined the normal and pathologic vocal folds of 215 subjects with our new system and analyzed the vocal fold vibration in these subjects by playback of a video and kymograph images.

**Conclusions:** Our high-speed laryngeal imaging system is highly cost-effective and can be a useful tool for examining the vocal folds of patients with voice disorders.

## Introduction

Observing the vocal fold vibration is essential for investigating the causes of voice hoarseness. For this purpose, videostroboscopy is widely used to show “illusory” slow motion images of the vibrating vocal folds. However, its clinical use is limited because it relies on periodic vocal fold vibration and a stable phonation frequency to activate the strobe light [1]. While high-speed laryngeal imaging can visualize “true” vocal fold vibration, considerable acquisition costs and limited recording capacities of conventional systems for high-speed digital imaging have impeded the spread of this highly effective method.

A consumer high-speed digital camera (EXILIM PRO EX-F1, Casio Computer Co., Ltd., Tokyo), which can record a movie at a rate of 1,200 frames per second (fps), is available in Japan since March 2008. We assembled a high-speed imaging system from this camera and reported it in literature [2]. We applied this system to clinical practice and examined more than 200 subjects with healthy or pathologic vocal fold vibration since October 2008. Here, we demonstrate the usefulness and cost-effectiveness of our system in the clinical setting.

## Technique

Our high-speed imaging system consists of the EX-F1 digital camera, a 70° rigid laryngeal endoscope (STF-1, Nagashima Medical Instruments Co., Ltd., Tokyo), a custom-made C-mount endoscope adapter, and a xenon 300W light source (CLV-S40Pro, Olympus Co., Tokyo) (Figure 1). This system enabled us to transorally observe each vocal fold vibration with images at a rate of 1,200 fps, and the video images were saved in the camera as MOV format files (336 × 96 pixels). Although the camera can shoot color images, we set the color tone of the images to black and white mode to achieve higher contrast. This study was approved by the institutional review board at Nagasaki University Hospital.

To date, the number of subjects examined with this system has totaled to 215 (124 males and 91 females; mean age 60.6 years; Table 1). We analyzed the vocal fold vibration by playback of the video images at various speeds and kymograph images constructed from the MOV files with our original software.

Figure 2 shows an example of images of vocal fold vibration in a subject examined with our system. The subject was an 80-year-old male with severely “breathy” voice due to right vocal fold paralysis caused by invasion of thyroid carcinoma on the right recurrent laryngeal nerve. In this case, the left vocal fold started to vibrate earlier than

the right. The vocal fold vibration showed left–right asymmetry with respect to the amplitude of vibration (right side increased amplitude) and incomplete glottal closure. The mucosal waves also increased on the right side. During videostroboscopy, the vocal fold vibration could not be tracked because the pitch was not accurately detected. Figure 3 illustrates another example. The subject was a 76-year-old male with left vocal fold scarring after resection of keratosis. The glottis did not close completely and the mucosal waves were absent on the left side, suggesting increased stiffness of the cover.

## Discussion

Videostroboscopy has been the primary method used to evaluate vocal fold vibration. However, aperiodic movement due to lesions on the vocal folds or asymmetry of vocal fold function, characterized clinically as a hoarse or rough vocal quality, cannot be visualized with stroboscopy [1]. It is also impossible to observe the folds during a lull in the phonation such as at vocal onset and offset. High-speed laryngeal imaging offers benefits over standard videostroboscopy in the analysis of aperiodic vocal fold motion and will probably develop as an important adjunct to videostroboscopy in the evaluation of voice disorders [1]. For example, it is sometimes difficult to observe vocal fold vibration using videostroboscopy in patients with hemilateral vocal fold paralysis

accompanied by a large glottal gap or in patients with severe Reinke's edema. We believe that high-speed laryngeal imaging is very useful for preoperative evaluation of vocal folds in such cases.

EX-F1 can shoot digital images at maximum of 1,200 fps and can be purchased at approximately \$US1000 in Japan. Using this camera, we succeeded in shooting ultra slow-motion movies of true intracycle vocal fold vibration at speeds that were previously only available in expensive professional level cameras.

Apart from its high-speed movie capability and low price, EX-F1 has many other strong points. In its high-speed movie recording mode at 1,200 fps, the total shooting time is as long as approximately 4 hours when a 32 gigabyte (GB) memory card is used (maximum recording capacity per file is 4 GB). A built-in a 2.8-inch monitor screen behind the camera displays images for both recording and playback. A movie is recorded as an MOV file, which is the standard format of QuickTime (Apple Inc., USA). It is possible to copy movie files to a personal computer and to undertake a more detailed analysis such as kymography. The weight of the camera itself is about 671 g, and with a battery, adapter, and a rigid endoscope, approximately 1 kg.

The rate of 1,200 fps will be helpful in the clinical examination of the vocal folds in many cases, though it may be insufficient for the especially detailed analysis of vocal

fold vibration. Our high-speed laryngeal imaging system is highly cost-effective and can be a useful tool when examining the vocal folds of patients with voice problems.

#### Acknowledgement

This study was supported by the JFE (The Japanese Foundation for Research and Promotion of Endoscopy) grant.



## Figure Legends

Figure 1: The low-cost high-speed imaging system

Figure 2: Vocal fold vibration in a patient with right vocal fold paralysis (A) A sequence of images containing almost one glottal cycle shown in 12 images (10 ms)

(B) Kymogram at vocal onset; White arrow shows time axis running downward; White bar shows 100 ms

Figure 3: Vocal fold vibration in a patient with left vocal fold scarring. A sequence of 10 images (8.3 ms) showing approximately one glottal cycle.

Supplementary material: The movie of the vocal fold vibration of the same case as in

Figure 2

## References

- 1 Kendall KA: High-speed laryngeal imaging compared with videostroboscopy in healthy subjects. *Arch Otolaryngol Head Neck Surg* 2009;135:274–281.
- 2 Kaneko K, Sakaguchi K, Tanaka F, Takano A, Jinnouchi S, Nishi H, Takahashi

H, Inoue M: Vibration of the vocal folds observed using a high-speed movie system with consumer digital video camera. *Practica Oto-Rhino-Laryngologica* 2009;102:379–384 (in Japanese).

Figure. 1



Figure. 2A

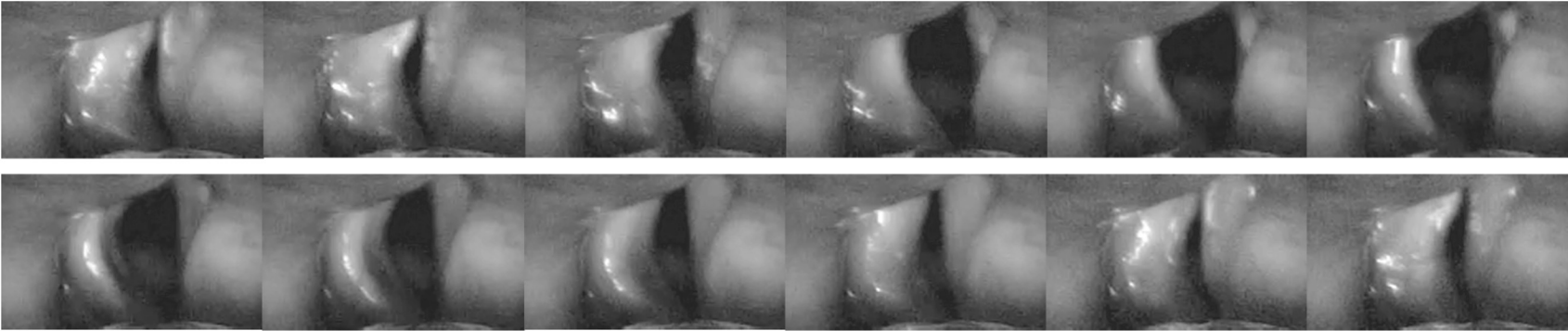


Figure. 2B


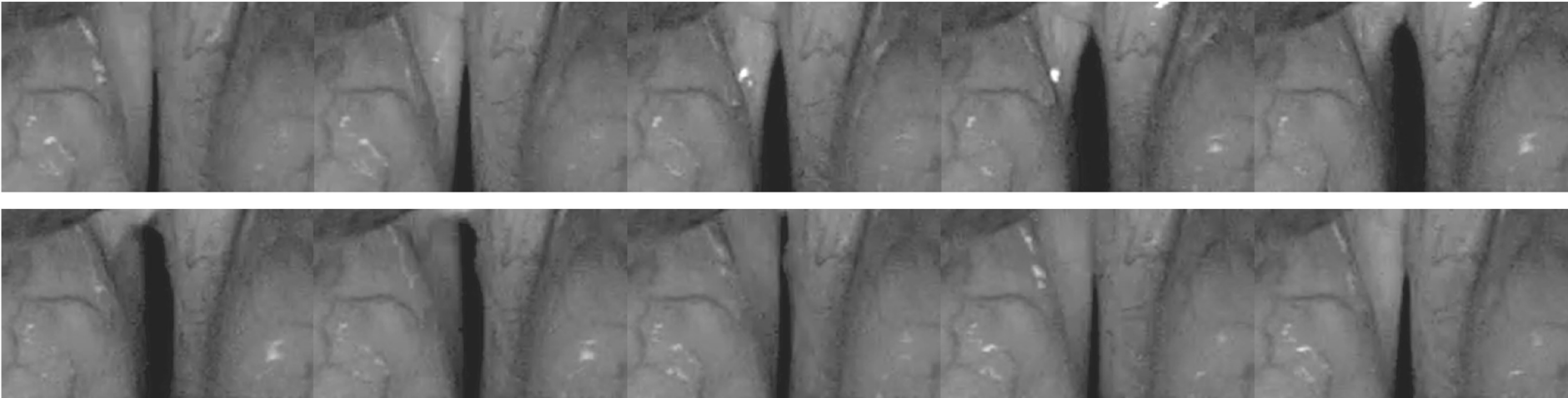


Figure. 3



**Table 1.** List of voice disorders

Diagnosis	Number of subjects
Normal	32
Neoplastic tumor	
Carcinoma	49
Precancerous changes and keratosis	9
Papilloma	4
Laryngeal paralysis	60
Phonotrauma and associated benign lesions	
Vocal fold polyp	10
Reinke's edema	9
Laryngeal cyst	8
Vocal fold nodules	6
Vocal fold scarring	5
Sulcus vocalis	5
Functional dysphonia	9
Laryngitis	4
Age-related atrophy of vocal fold	3
Prolapse of ventricle	1
External laryngeal trauma	1