

Title: Bisphosphonate-Related Osteonecrosis of the Palatal Torus

Kenichi Kaneko and Haruo Takahashi

Department of Otolaryngology – Head and Neck Surgery, Nagasaki University

Graduate School of Biomedical Sciences, Nagasaki, Japan

Corresponding Author: Kenichi Kaneko, MD, PhD

Department of Otolaryngology – Head and Neck Surgery, Nagasaki University

Graduate School of Biomedical Sciences

1-7-1 Sakamoto, Nagasaki 852-8501 (Japan)

Telephone: +81-95-819-7349

Fax: +81-95-819-7352

E-mail: kkaneko@nagasaki-u.ac.jp

Abstract

Background: Bisphosphonates are widely used for the treatment of osteoporosis and other bone degrading disorders; however, bisphosphonate therapy is an important risk factor for osteonecrosis of the jaws. **Methods:** We report a rare case of bisphosphonate-related osteonecrosis of the palatal torus. **Results:** The patient was a 72-year-old female with osteoporosis who had received 35 mg alendronate sodium hydrate once every week for 6 years. She had a 2-month history of oral pain because of intractable mucositis and ulceration of the palatal torus, with no history of malignant disease, radiation therapy, chemotherapy, steroid use, or recent dentoalveolar surgery. A CT scan showed a bony prominence at the midportion of the hard palate with erosion of its cortex. Her condition was diagnosed as stage 2 bisphosphonate-related osteonecrosis of the jaw (BRONJ) caused by trauma and she was advised to discontinue alendronate. She was prescribed oral antibiotics for 5 days and an oral antibacterial rinse. The mucositis with ulceration healed in approximately 10 weeks, but left a small scar.

Conclusions: Although osteonecrosis of the palatal torus associated with bisphosphonate use is a rare condition, otolaryngologists should consider this condition in the differential diagnosis of intractable ulceration of the hard palate.

Key Words

Osteonecrosis, Palatal torus, Bisphosphonates, Alendronate

Introduction

Bisphosphonates are widely used for the treatment of osteoporosis and other bone degrading disorders, although bisphosphonate-related osteonecrosis of the jaw (BRONJ) have been reported since 2003 [1, 2]. However, many otolaryngologists appear to have little understanding of this significant complication. Here we report a rare case of osteonecrosis of the palatal torus associated with the use of an oral bisphosphonate (alendronate).

Case Report

A 72-year-old female experienced oral pain after eating hot food one day. She visited an ENT clinic where she was diagnosed with mucositis with ulceration of the hard palate. She was instructed to apply a steroidal ointment for treatment of the mucositis, but there was no sign of improvement after 2 months. Thereafter, she was encouraged to undergo a biopsy and visited our hospital for further examination after recommendation from the ENT clinic. She presented with a chief complaint of sustained pain in the palate. Her medical history revealed osteoporosis, which had been treated with 35 mg of alendronate sodium hydrate once per week for 6 years. She had no history of malignant disease, radiation therapy, chemotherapy, steroid use, or recent dentoalveolar surgery.

Physical examination revealed an ulcer with a diameter of 1 cm, with exposure of the bone of the palatal torus (fig. 1). No abnormal blood vessels were observed in the mucosa surrounding the ulcer by narrow-band imaging (NBI) [3, 4]. She had 28 teeth except the 4 third molars and had neither tooth caries nor periodontal disease. The results of hematological examination were normal. A CT scan showed a bony prominence at the midportion of the hard palate with erosion of its cortex (fig. 2). Although we did not perform a biopsy of the palate, we diagnosed her condition as stage 2 bisphosphonate-related osteonecrosis of the palatal torus caused by trauma and advised her to discontinue alendronate. We prescribed an oral antibiotic (cefdinir) for 5 days and an oral antibacterial rinse. Bacterial examination was not performed. The ulcer began to shrink 7 weeks after discontinuation of alendronate. After 3 additional weeks, the ulcer was healed, but left a small scar, and the oral pain ceased. After recovery from osteonecrosis, she declined resection of the palatal torus. Her orthopedist determined that she did not need to restart bisphosphonate therapy. There has been no recurrence of symptoms or ulceration for 6 months.

Discussion

BRONJ is a potential serious side effect of bisphosphonate therapy. The incidence of

BRONJ in patients receiving weekly alendronate therapy is estimated at 0.01%–0.04% [5]. The risk factors for BRONJ include drug-related factors (bisphosphonate potency and duration of therapy), local factors (dentoalveolar surgery, local anatomy of the jaw including tori and ridge, and concomitant oral disease), demographic and systemic factors (e.g., age, renal dialysis, low hemoglobin levels, obesity, and diabetes), genetic factors, and preventative factors (e.g., manipulation of intravenous bisphosphonate dose) [6]. The 2 most important risk factors for BRONJ are intravenous bisphosphonate administration and dentoalveolar procedures [6]. The mucosa overlying bony prominences such as tori are possibly injured while eating. Marx et al. found that 9.2% of patients with BRONJ had their exposed bone over the mandibular tori [7], but BRONJ cases involving the palatal tori are comparatively rare [8-10].

According to a position paper on BRONJ by the American Association of Oral and Maxillofacial Surgeons, patients may be considered to have BRONJ if all the following 3 characteristics are present: (1) current or previous treatment with a bisphosphonate; (2) exposed bone in the maxillofacial region that has persisted for more than 8 weeks; and (3) no history of radiation therapy to the jaws [6]. The patient in our case met all 3 conditions and no abnormal blood vessels were observed in the mucosa surrounding the ulcer on NBI; thus, we made a diagnosis of BRONJ without a biopsy. According to

Ruggiero et al., biopsies are not recommended for BRONJ in cancer patients undergoing bisphosphonate treatment unless metastasis to the jaw is suspected, because the benefit of a confirmed biopsy does not outweigh the risk of inducing further bone damage that could exacerbate the condition [11]. We must judge carefully whether we should perform a biopsy when a patient has the aforementioned 3 characteristics so as to not deteriorate the condition. Then NBI will be helpful for detecting superficial oral squamous cell carcinomas because it is an optical technique that enhances the diagnostic capability of endoscopy by illuminating the intraepithelial papillary capillary loop by means of narrow and wide filters in a red–green–blue sequential illumination system [3, 4]. If a malignancy is suspected, a biopsy should be performed to confirm the diagnosis at any stage of the disease.

BRONJ is classified into 4 stages, stage 0–3 [6]. In our case, we categorized BRONJ as stage 2 because exposed and necrotic bone was observed over a limited area, accompanied by pain and clinical evidence of infection. The position paper states that patients with stage 2 BRONJ can benefit from the use of oral antimicrobial rinses and antibiotic therapy, and if systemic conditions permit, oral bisphosphonate therapy should be modified or ceased after consultation with the treating physician and the patient [6]. Our patient successfully recovered from BRONJ with only conservative

therapy using oral rinses and antibiotics, in combination with discontinuation of alendronate. Though penicillin is recommended in the position paper [6], we used cefdinir for antibiotic therapy because it has insurance indication for periodontitis in Japan.

In previous reports of osteonecrosis of the palatal tori, surgical removal of the torus [8] and necrotic bone [9] was performed after bisphosphonate treatment was discontinued. Lo et al. reported 3 patients with stage 1–2 BRONJ involving the palatal tori and spontaneous exfoliation occurred in 2 patients [10]. If the exposed and necrotic bone extends over wide areas (stage 3), debridement will be useful; regardless of the disease stage, mobile segments of bony sequestrum should be removed without exposing uninvolved bone, as recommended by the position paper [6]. Furthermore, after recovery from BRONJ, removal of the palatal tori should be considered if the patient restarts bisphosphonate therapy, particularly by the intravenous route. To prevent BRONJ, Marx et al. recommended removal of the palatal tori 1 month before initiation of bisphosphonate therapy [7].

Most BRONJ cases have been reported in the dental literature; thus, this condition remains unfamiliar to many otolaryngologists. However, otolaryngologists may encounter BRONJ cases and should, therefore, become more familiar with this

condition. BRONJ involving the palatal tori is atypical and may be difficult to be correctly diagnose if the examining physician fails to associate it with bisphosphonate exposure. Correct diagnosis of BRONJ can avoid unnecessary biopsy and possible exacerbation of the condition by facilitating appropriate treatment.

Conclusions

Although osteonecrosis of the palatal torus associated with bisphosphonate therapy is a rare condition, otolaryngologists should consider this condition in the differential diagnosis of intractable ulceration of the hard palate.

CONFLICT OF INTEREST

No potential conflict of interest relevant to this article was reported.

References

- 1 Migliorati CA: Bisphosphonates and oral cavity avascular bone necrosis. *J Clin Oncol* 2003;21:4253-4254.

- 2 Marx RE: Pamidronate (aredia) and zoledronate (zometa) induced avascular necrosis of the jaws: A growing epidemic. *J Oral Maxillofac Surg* 2003;61:1115-1117.
- 3 Katada C, Nakayama M, Tanabe S, Naruke A, Koizumi W, Masaki T, Okamoto M, Saigenji K: Narrow band imaging for detecting superficial oral squamous cell carcinoma: A report of two cases. *Laryngoscope* 2007;117:1596-1599.
- 4 Takano JH, Yakushiji T, Kamiyama I, Nomura T, Katakura A, Takano N, Shibahara T: Detecting early oral cancer: Narrowband imaging system observation of the oral mucosa microvasculature. *Int J Oral Maxillofac Surg* 2010;39:208-213.
- 5 Mavrokokki T, Cheng A, Stein B, Goss A: Nature and frequency of bisphosphonate-associated osteonecrosis of the jaws in australia. *J Oral Maxillofac Surg* 2007;65:415-423.
- 6 Ruggiero SL, Dodson TB, Assael LA, Landesberg R, Marx RE, Mehrotra B: American association of oral and maxillofacial surgeons position paper on bisphosphonate-related osteonecrosis of the jaws--2009 update. *J Oral Maxillofac Surg* 2009;67:2-12.
- 7 Marx RE, Sawatari Y, Fortin M, Broumand V: Bisphosphonate-induced exposed bone (osteonecrosis/osteopetrosis) of the jaws: Risk factors, recognition, prevention, and treatment. *J Oral Maxillofac Surg* 2005;63:1567-1575.

- 8 Godinho M, Barbosa F, Andrade F, Cuzzi T, Ramos ESM: Torus palatinus osteonecrosis related to bisphosphonate: A case report. *Case Rep Dermatol* 2013;5:120-125.
- 9 Goldman ML, Denduluri N, Berman AW, Sausville R, Guadagnini JP, Kleiner DE, Brahim JS, Swain SM: A novel case of bisphosphonate-related osteonecrosis of the torus palatinus in a patient with metastatic breast cancer. *Oncology* 2006;71:306-308.
- 10 Lo JC, O’Ryan FS, Gordon NP, Yang J, Hui RL, Martin D, Hutchinson M, Lathon PV, Sanchez G, Silver P, Chandra M, McCloskey CA, Staffa JA, Willy M, Selby JV, Go AS: Prevalence of osteonecrosis of the jaw in patients with oral bisphosphonate exposure. *J Oral Maxillofac Surg* 2010;68:243-253.
- 11 Ruggiero S, Gralow J, Marx RE, Hoff AO, Schubert MM, Huryn JM, Toth B, Damato K, Valero V: Practical guidelines for the prevention, diagnosis, and treatment of osteonecrosis of the jaw in patients with cancer. *J Oncol Pract* 2006;2:7-14.

Figure legends

Fig. 1. Photographs of the palatal torus. Ulcer formation with exposure of the cortical bone was observed (arrows). The asterisk indicates the uvula.

Fig. 2. Axial CT scan. The cortex of the palatal torus was eroded.

Fig. 1.

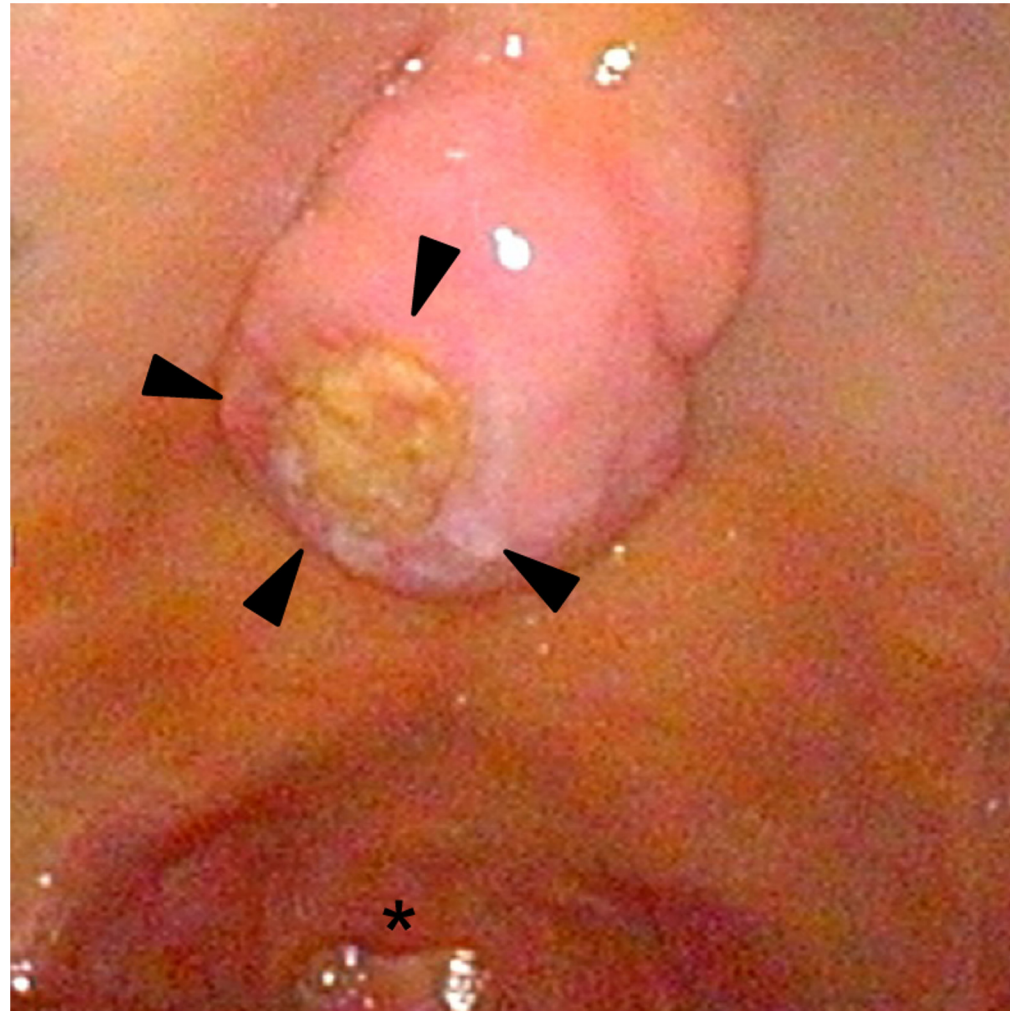


Fig. 2.

