

[CASE REPORT]

Diffuse Alveolar Hemorrhage Developing Immediately after Immunosuppressive Treatments in a Patient with Granulomatosis with Polyangiitis Who Had Pulmonary Nodules

Chiaki Watanabe¹, Shoichi Fukui¹, Naoki Iwamoto¹, Toshimasa Shimizu¹, Masataka Umeda¹, Ayako Nishino¹, Tomohiro Koga¹, Shin-ya Kawashiri^{1,2}, Kunihiro Ichinose¹, Yasuko Hirai¹, Mami Tamai¹, Hideki Nakamura¹, Tomoki Origuchi^{1,3}, Kazuhiro Tabata⁴ and Atsushi Kawakami¹

Abstract:

A 65-year-old man was diagnosed with granulomatosis with polyangiitis (GPA) based on the detection of high myeloperoxidase anti-neutrophil cytoplasmic antibody (MPO-ANCA), vasculitis and granulomas in a lung biopsy specimen and crescentic glomerulonephritis in a kidney biopsy specimen. Soon after the initiation of intravenous methylprednisolone pulse therapy (mPSL pulse) and intravenous cyclophosphamide pulse therapy (IVCY), the patient experienced cough and hemoptysis. Based on emerging anemia and bilateral diffuse lung consolidation on computed tomography, we judged that diffuse alveolar hemorrhage (DAH) was complicated by GPA. The patient's DAH improved following additional mPSL pulse and IVCY. Physicians should be aware of the possible occurrence of DAH, even when a patient's symptoms improve after mPSL pulse and IVCY.

Key words: diffuse alveolar hemorrhage, granulomatosis with polyangiitis, intravenous pulse methylprednisolone, intravenous cyclophosphamide pulse therapy, ANCA associated vasculitis

(Intern Med 57: 417-421, 2018)

(DOI: 10.2169/internalmedicine.9188-17)

Introduction

Antineutrophil cytoplasmic antibody (ANCA)-associated vasculitis (AAV) is a form of necrotizing vasculitis, with few or no immune deposits, that predominantly affects the small vessels associated with ANCA (1); however, its etiology remains unknown. Granulomatosis with polyangiitis (GPA) is a form of AAV that affects the airways, lungs, kidneys, skin, eyes and nervous system (2). Diffuse alveolar hemorrhage (DAH) is a lung manifestation that appears in 10% of GPA cases (3). DAH is a catastrophic clinical syn-

drome that causing hypoxemic respiratory failure and which is histopathologically characterized by pulmonary capillaritis and clinically characterized by diffuse radiographic pulmonary infiltration, hemoptysis, and anemia (4). In AAV, in particular, DAH is often associated with kidney disease (5). The poor prognosis of DAH associated with kidney disease, including AAV, which has a one-year survival rate of only 50%, has previously been reported (6). However, a study on DAH with small vessel vasculitis, which had a short follow-up period, revealed that treatment with plasma exchange can achieve a survival rate of 95% (7). We present a characteristic case of GPA that was complicated by DAH soon after

¹Unit of Advanced Preventive Medical Sciences, Department of Immunology and Rheumatology, Nagasaki University Graduate School of Biomedical Sciences, Japan, ²Unit of Advanced Preventive Medical Sciences, Department of Community Medicine, Nagasaki University Graduate School of Biomedical Sciences, Japan, ³Unit of Rehabilitation Sciences, Department of Locomotive Rehabilitation Science, Nagasaki University Graduate School of Biomedical Sciences, Japan and ⁴Department of Pathology, Nagasaki University Hospital, Japan

Received: March 14, 2017; Accepted: June 6, 2017; Advance Publication by J-STAGE: November 1, 2017

Correspondence to Dr. Shoichi Fukui, fukui-ngs@umin.ac.jp

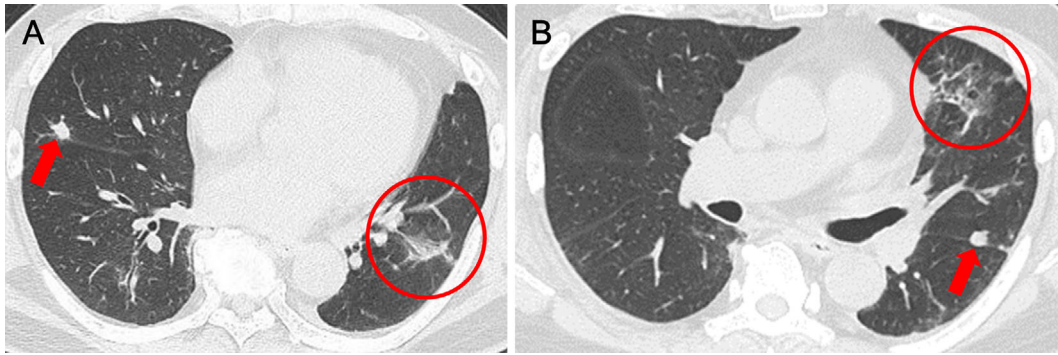


Figure 1. Multiple pulmonary nodules in the bilateral lung fields (red arrows) and partial interstitial reticular markings in the lingular segment (red circles).

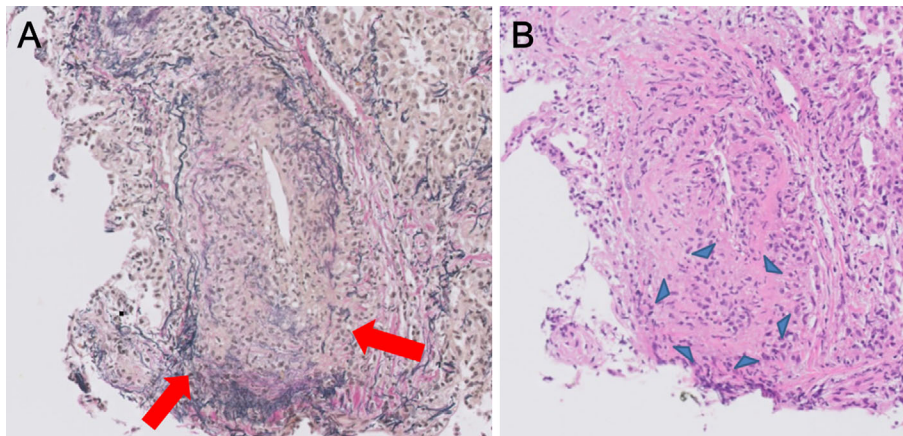


Figure 2. (A) Vasculitis with vessel destruction (red arrows). (B) Noncaseating epithelioid granulomas (blue arrowheads) in the lung.

the administration of methylprednisolone pulse therapy and cyclophosphamide pulse therapy.

Case Report

A 65-year-old man was admitted to our hospital with a fever of one month in duration. The patient's appetite declined and hyperemia of the bilateral conjunctiva and pitting edema in the bilateral legs appeared. His past medical history included angina pectoris, hypertension, and dyslipidemia, which were treated with aspirin, telmisartan, and pitavastatin. He had smoked 40 cigarettes a day for 45 years (from 20 to 64 years of age).

On physical examination, the patient's body temperature was 38.0°C. His bilateral conjunctiva showed hyperemia. Auscultation of the chest showed no abnormal findings. Pitting edema were observed in the bilateral legs. There were no signs or symptoms suggesting involvement of the ears, nose, and throat (ENT). He had no skin eruptions. The laboratory data were as follows: white blood cell (WBC) count, 10,300/ μ L; hemoglobin, 11.3 g/dL; platelets, 407,000/ μ L; C-reactive protein (CRP), 8.29 mg/dL; serum creatinine (Cr), 1.79 mg/dL; antinuclear antibody, 1:40 (normal range: <1:40); KL-6, 200 U/mL; and a high myeloperoxidase (MPO)-ANCA level of 81.7 enzyme-linked immunosorbent assay

(ELISA) units (EU)/mL (normal range: <12 EU/mL). Proteinase 3 (PR3)-ANCA was negative. A urinalysis revealed microscopic hematuria (31-50 red blood cells/high-power field), proteinuria (0.32 g/g Cr) and erythrocyte casts. Chest computed tomography (CT) showed multiple pulmonary nodules in the bilateral lung fields and partial interstitial reticular markings in the lingular segment (Fig. 1). Bronchoalveolar lavage demonstrated no erythrocytes suggesting DAH. Lung biopsy specimens showed vasculitis with vessel destruction (Fig. 2A) and noncaseating epithelioid granulomas (Fig. 2B). A kidney biopsy specimen demonstrated a glomerular crescent formation (Fig. 3A), histiocyte infiltration, and the rupture of Bowman's capsules (Fig. 3B).

Because there were high degrees of MPO-ANCA, vasculitis and noncaseating epithelioid granulomas in the lung biopsy specimens and due to the presence of crescentic glomerulonephritis in the kidney biopsy specimens, the patient was diagnosed with GPA based on the Chapel Hill Consensus Conference (CHCC) criteria (1) and the European Medicines Agency (EMA) algorithm (8). Treatment with oral prednisolone (PSL, 60 mg/day) followed by intravenous pulse methylprednisolone (mPSL pulse; 1,000 mg/day for 3 consecutive days) on day 10. The patient's fever declined. His CRP level also declined (2.15 mg/dL on day 14); however, his creatinine levels showed no improvement.

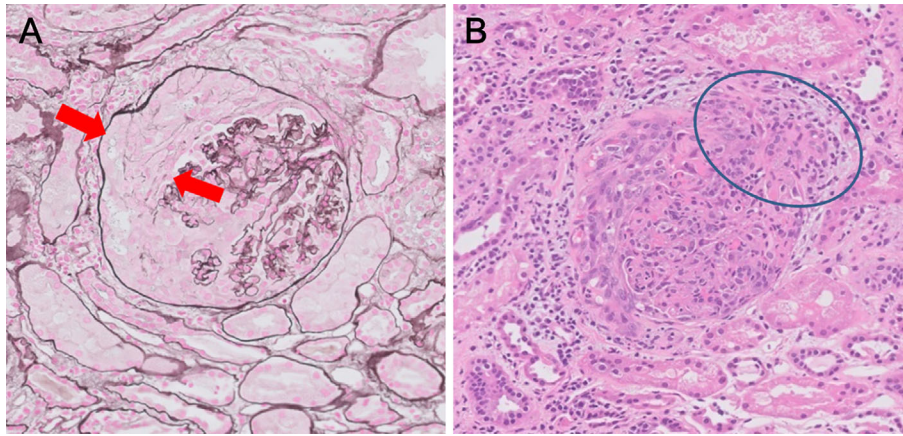


Figure 3. (A) Glomerular crescent formation (red arrows). (B) Histiocyte infiltration and the rupture of Bowman's capsules (blue circle).

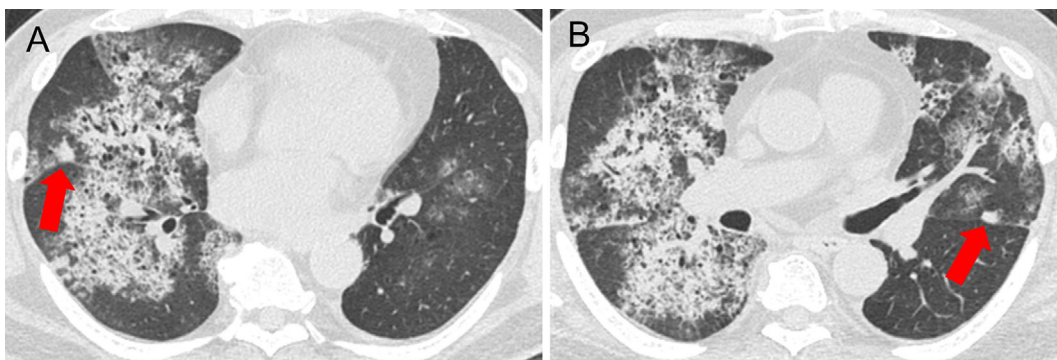


Figure 4. (A) A pulmonary nodule in the right lung field did not change in size (red arrow). Emerging diffuse consolidation in the bilateral lower lobes. (B) A pulmonary nodule in the left lung field did not change in size (red arrow). Partial reticular markings in the lingular segment in the previous chest CT became a larger ground glass opacity and consolidation.

We added intravenous cyclophosphamide pulse therapy [intravenous cyclophosphamide pulse therapy (IVCY) (925 mg, equivalent to 15 mg/kg body weight)] on day 11.

On day 15, the patient experienced cough and hemoptysis. Chest CT showed emerging diffuse consolidation in the bilateral lower lobes, suggesting DAH (Fig. 4). The partial interstitial reticular markings in the lingular segment that had been seen in the previous CT scan changed to a larger ground glass opacity and consolidation, and diffuse consolidation also spread in an area in which no opacity had been observed on the previous chest CT scan. Multiple pulmonary nodules in the bilateral lung fields showed no changes in size in comparison to the previous CT scan (Fig. 4, the same levels of nodules as Fig. 2). The patient's hemoglobin level suddenly declined (9.1 g/dL on day 15) and his CRP level became elevated (7.11 mg/dL on day 15). We judged that DAH was complicated by GPA, despite the improvement of his fever. We administered mPSL pulse therapy for 3 consecutive days twice (on days 15-17 and days 21-23) and performed plasma exchange six times (three times per week). Because his respiratory status gradually worsened despite the use of oxygen (by reservoir mask), we used non-

invasive positive pressure ventilation. His respiratory status showed a brisk recovery, and he could be managed without intubation. We administered IVCY a second time two weeks after the first IVCY (Fig. 5). His chest CT findings improved within two months. Although his serum Cr level was kept, the red blood cell casts in the urine disappeared and his MPO-ANCA titer declined.

We administered a total of 9 courses of IVCY. One year later, he continues to receive PSL (3 mg/day) and has shown no signs of relapse.

Discussion

We presented the case of a patient with GPA associated with DAH following mPSL pulse and IVCY. DAH occurred soon after the initiation of mPSL pulse and IVCY, despite the improvement of the patient's fever and laboratory data (including his CRP level).

The incidence of DAH in AAV is between 8% and 36%. Among AAV patients with DAH, 41% of patients are diagnosed with GPA (mainly in Western countries) (9). In Japan, it was reported that among 1,147 AAV patients, 177 had

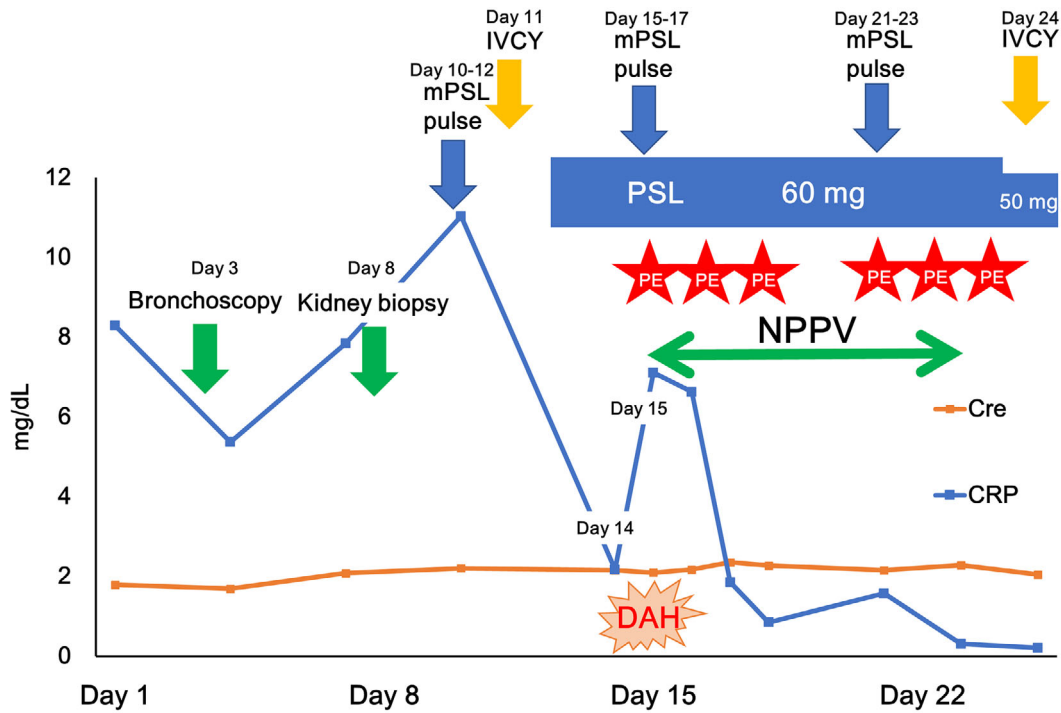


Figure 5. The clinical course of granulomatosis with polyangiitis complicated by diffuse alveolar hemorrhage. Cre: creatinine, CRP: C-reactive protein, DAH: diffuse alveolar hemorrhage, IVCY: intravenous cyclophosphamide pulse therapy, mPSL pulse: intravenous pulse methylprednisolone, NPPV: non-invasive positive pressure ventilation, PE: plasma exchange, PSL: prednisolone

DAH (10). Only 2 of 13 (15%) AAV patients with DAH had GPA, because more patients are diagnosed with MPA than GPA in Japan (11).

In our patient, DAH emerged in a way that was not parallel to the other activities or results of AAV, including the patient's fever and CRP levels. The patient's GPA disease activity may have been high because his creatinine level did not improve. Our patient showed two factors (renal insufficiency and no ENT manifestations) from the revised five factor score (2009 FFS) that indicated a poor prognosis (12). However, treatment based on the five factor score is not applicable to GPA, in which immunosuppressants combined with corticosteroids are compulsory. Thus, we used IVCY after mPSL pulse. DAH occurred in our patient despite the administration of mPSL pulse and IVCY. To the best of our knowledge regarding DAH after mPSL pulse, there is one reported case of a patient with GPA and systemic lupus erythematosus complicated by DAH at one week after the initiation of mPSL pulse while the patient's symptoms including fever, skin eruptions, renal function and otitis media were improving by PSL (50 mg/day) (13).

Our patient had pulmonary nodules and interstitial reticular markings and subsequent DAH. In Japan, among 600 AAV patients with pulmonary involvement, 50 patients had both DAH and interstitial lung disease, and 6 patients had both DAH and pulmonary granuloma; however, it is unclear when DAH and interstitial lung disease or pulmonary granuloma occur (10). The changes in the lung opacity on the patient's chest CT scans was a valuable finding.

There is little information regarding risk factors for DAH in AAV. AAV patients with hypocomplementemia are reported to show a higher incidence of DAH in comparison to AAV patients without hypocomplementemia (14); however, our patient had no hypocomplementemia. DAH (not limited to AAV) is reported to be caused by antiplatelet (15) and anticoagulant medications (16). Our patient was treated with aspirin for angina pectoris. Thus, caution should be exercised with regard to the administration of antiplatelet or anticoagulant medications.

In conclusion, DAH may occur after the initiation of mPSL pulse and IVCY. Physicians should be aware of the possibility of DAH, even when a patient's symptoms and inflammatory marker levels improve after mPSL pulse and IVCY. It is necessary to evaluate the risk factors for DAH in AAV patients.

The authors state that they have no Conflict of Interest (COI).

References

- Jennette JC, Falk RJ, Bacon PA, et al. 2012 revised International Chapel Hill Consensus Conference Nomenclature of Vasculitides. *Arthritis Rheum* **65**: 1-11, 2013.
- Berden A, Goceroglu A, Jayne D, et al. Diagnosis and management of ANCA associated vasculitis. *BMJ* **344**: e26, 2012.
- Homma S, Suzuki A, Sato K. Pulmonary involvement in ANCA-associated vasculitis from the view of the pulmonologist. *Clin Exp Nephrol* **17**: 667-671, 2013.
- Lara AR, Schwarz MI. Diffuse alveolar hemorrhage. *Chest* **137**:

- 1164-1171, 2010.
5. Niles JL, Bottinger EP, Saurina GR, et al. The syndrome of lung hemorrhage and nephritis is usually an ANCA-associated condition. *Arch Intern Med* **156**: 440-445, 1996.
 6. Gallagher H, Kwan JT, Jayne DR. Pulmonary renal syndrome: a 4-year, single-center experience. *Am J Kidney Dis* **39**: 42-47, 2002.
 7. Klemmer PJ, Chalermkulrat W, Reif MS, Hogan SL, Henke DC, Falk RJ. Plasmapheresis therapy for diffuse alveolar hemorrhage in patients with small-vessel vasculitis. *Am J Kidney Dis* **42**: 1149-1153, 2003.
 8. Watts R, Lane S, Hanslik T, et al. Development and validation of a consensus methodology for the classification of the ANCA-associated vasculitides and polyarteritis nodosa for epidemiological studies. *Ann Rheum Dis* **66**: 222-227, 2007.
 9. West S, Arulkumaran N, Ind PW, Pusey CD. Diffuse alveolar haemorrhage in ANCA-associated vasculitis. *Intern Med* **52**: 5-13, 2013.
 10. Hirayama K, Kobayashi M, Usui J, et al. Pulmonary involvements of anti-neutrophil cytoplasmic autoantibody-associated renal vasculitis in Japan. *Nephrol Dial Transplant* **30** (Suppl 1): i83-i93, 2015.
 11. Sada KE, Yamamura M, Harigai M, et al. Classification and characteristics of Japanese patients with antineutrophil cytoplasmic antibody-associated vasculitis in a nationwide, prospective, inception cohort study. *Arthritis Res Ther* **16**: R101, 2014.
 12. Guillevin L, Pagnoux C, Seror R, Mahr A, Mouthon L, Le Toumelin P. The Five-Factor Score revisited: assessment of prognoses of systemic necrotizing vasculitides based on the French Vasculitis Study Group (FVSG) cohort. *Medicine (Baltimore)* **90**: 19-27, 2011.
 13. Fukui S, Iwamoto N, Tsuji S, et al. Diffuse alveolar hemorrhage emerging one week after starting high-dose corticosteroid therapy for granulomatosis with polyangiitis (GPA) with systemic lupus erythematosus (SLE). *Intern Med* **54**: 2681-2686, 2015.
 14. Fukui S, Iwamoto N, Umeda M, et al. Antineutrophilic cytoplasmic antibody-associated vasculitis with hypocomplementemia has a higher incidence of serious organ damage and a poor prognosis. *Medicine (Baltimore)* **95**: e4871, 2016.
 15. Cherian S, Hamarneh W, Das N, Landsberg D, Das S. Clopidogrel associated diffuse alveolar hemorrhage; an extremely rare occurrence. *Am J Respir Crit Care Med* **185**: A5929, 2012.
 16. Erdogan D, Kocaman O, Oflaz H, Goren T. Alveolar hemorrhage associated with warfarin therapy: a case report and literature review. *Int J Cardiovasc Imaging* **20**: 155-159, 2004.
- The Internal Medicine is an Open Access article distributed under the Creative Commons Attribution-NonCommercial-NoDerivatives 4.0 International License. To view the details of this license, please visit (<https://creativecommons.org/licenses/by-nc-nd/4.0/>).