



The effect of once-yearly zoledronic acid on hip structural and biomechanical properties derived using computed tomography (CT) in Japanese women with osteoporosis



Masako Ito ^{a,*}, Teruki Sone ^b, Masataka Shiraki ^c, Satoshi Tanaka ^d, Chika Irie ^d, Yuri Ota ^d, Toshitaka Nakamura ^e

^a Center for Diversity and Inclusion, Nagasaki University, 1-14 Bunkyo-machi, Nagasaki City, Nagasaki 852-8521, Japan

^b Department of Nuclear Medicine, Kawasaki Medical School, 577 Matsushima, Kurashiki City, Okayama 701-0192, Japan

^c Research Institute and Practice for Involuntal Diseases, 1610-1 Meisei, Misato, Azumino, Nagano 399-8101, Japan

^d Asahi Kasei Pharma Corporation, 1-105 Jinbocho, Kanda, Chiyoda-ku, Tokyo 101-8101, Japan

^e Japan Osteoporosis Foundation, 2-14 Odenma-cho, Nihonbashi Chuo-ku, Tokyo, Japan

ARTICLE INFO

Article history:

Received 17 January 2017

Revised 10 October 2017

Accepted 11 October 2017

Available online 12 October 2017

Keywords:

Bisphosphonate

Zoledronic acid

Hip geometry

Bone mineral density

Computed tomography

Biomechanical property

ABSTRACT

The effects of zoledronic acid on hip structural and biomechanical properties were evaluated in Japanese patients with osteoporosis by computed tomography (CT).

The subjects included in this study were a subset of female subjects (zoledronic acid group, 49 subjects; placebo group, 53 subjects) in the phase 3 trial (ZONE study) who were available for multi-detector row CT (MDCT) scanning. Eligible subjects were those diagnosed with primary osteoporosis based on the Diagnostic Criteria for Primary Osteoporosis (2000) by the Japanese Society for Bone and Mineral Research and who had between one and four fractured vertebrae located between the fourth thoracic vertebra and the fourth lumbar vertebra. The subjects received a once-yearly intravenous infusion of zoledronic acid 5 mg or placebo for two years. CT data were obtained at baseline and at 12 and 24 months later and analyzed under blinded conditions.

The results demonstrated that once-yearly intravenous infusion of zoledronic acid improved volumetric bone mineral density (vBMD), cortical bone geometry parameters, and CT-derived biomechanical parameters at the femoral neck, intertrochanteric region, and shaft; particularly at the intertrochanteric region, significant improvements in cortical bone geometry parameters and CT-derived biomechanical parameters, compared with those in the placebo group, were detectable early, at 12 months. The present data suggest that zoledronic acid has a possibility to reduce the risk of hip fractures in Japanese patients with osteoporosis.

© 2017 The Authors. Published by Elsevier Inc. This is an open access article under the CC BY license (<http://creativecommons.org/licenses/by/4.0/>).

1. Introduction

Zoledronic acid is known to have a powerful inhibitory effect on bone resorption when infused intravenously once yearly, an interval of administration that is the longest among injectable bisphosphonates for the treatment of osteoporosis. An international multi-institutional clinical trial (Health Outcomes and Reduced Incidence with Zoledronic acid ONCE yearly Pivotal Fracture Trial [HORIZON-PFT]) involving >7000 subjects demonstrated that 3-year treatment with zoledronic acid reduced new vertebral fractures by 70% and hip fractures by 41% and increased lumbar bone mineral density (BMD) from baseline by 6.71%, hip BMD by 6.02%, and femoral neck BMD by 5.06% compared with placebo [1]. A phase 3 trial of zoledronic acid (ZoledroNate treatment in Efficacy to osteoporosis [ZONE] study) in Japanese subjects also demonstrated that 2-year treatment increased lumbar BMD by

7.61%, hip BMD by 4.03%, and femoral neck BMD by 4.07%, and reduced new vertebral fractures by 66% compared with placebo. Furthermore, for the first time in a study of an osteoporosis drug in Japan, zoledronic acid significantly reduced nonvertebral fractures (45%, compared with placebo) [2].

Noninvasive methods for evaluating the effect of an osteoporosis drug on improving bone biomechanical parameters, which may serve as surrogate markers of bone strength, have been established. One such method has allowed studies conducted in recent years to evaluate bone biomechanical properties from bone structural properties using images. In particular, 3-dimensional visualization of bone structure by computed tomography (CT) has been used for morphological quantification. Thus, even for the femur, which has a complicated structure, the cross-sections that intersect the axis of the femoral neck or shaft can be precisely extracted. Additionally, the femur can be further divided into the neck, the intertrochanteric region, and the shaft areas, and, in each of these areas, the cortical bone can be extracted for evaluations that yield detailed information on cortical bone structural properties

* Corresponding author.

E-mail address: masako@nagasaki-u.ac.jp (M. Ito).

Table 1
Baseline demographic and bone characteristics.

	Zoledronic acid (N = 49)	Placebo (N = 53)
Age (years)	74.3 ± 5.6	72.6 ± 5.2
Body height (cm)	147.86 ± 6.85	149.37 ± 5.12
Weight (kg)	51.41 ± 8.16	52.65 ± 9.09
Body mass index (BMI) (kg/m ²)	23.53 ± 3.50	23.58 ± 3.72
Years after menopause (years)	23.9 ± 6.2	21.7 ± 6.4
Bone mineral density (T-score)		
Lumbar spine (L1–4)	−2.968 ± 0.725	−3.049 ± 0.875
Femoral neck	−3.086 ± 0.946	−3.136 ± 0.779
Femoral total hip	−2.428 ± 0.961	−2.429 ± 0.879
Number of prevalent vertebral fractures	1.4 ± 0.9	1.4 ± 0.9

Bone mineral density was measured by dual X-ray absorptiometry.
Data are means ± SD.

[3–6]. In addition, by matching 3-dimensional CT images taken before and after treatment, CT images of the same site can be extracted and compared over time.

While there have been reports of bone structural evaluations by CT of the effects of active vitamin D [7] and teriparatide [8,9], to the best of our knowledge, there have been no reports of detailed evaluations by clinical CT of the effects of bisphosphonates on femoral cortical geometry and bone mineral density in Japanese subjects. Given that bisphosphonates have a different tissue level mechanism of action than active vitamin D and teriparatide, zoledronic acid may have a different effect on bone structural properties than these drugs do. Therefore, analysis of CT geometry was used to evaluate the effects of zoledronic acid on bone structural properties in Japanese osteoporosis patients who were enrolled in the ZONE study.

Table 2
Baseline QCT measurements and percent changes at 12 and 24 months.

Region	Parameter	Zoledronic acid (N = 49)			Placebo (N = 53)			
		Baseline	Percent change (%)		Baseline	Percent change (%)		
			12 months	24 months		12 months	24 months	
Femoral neck	Cortical thickness (mm)	1.64 ± 0.32	2.43 ± 5.93**	4.09 ± 8.12**	1.58 ± 0.26	1.67 ± 9.32	0.52 ± 7.06	
	Cortical CSA (cm ²)	0.97 ± 0.17	1.12 ± 5.85	2.59 ± 7.70	0.94 ± 0.17	1.13 ± 9.00	−2.57 ± 5.00**	
	Total CSA (cm ²)	1.33 ± 0.20	0.27 ± 3.91	1.37 ± 5.33	1.31 ± 0.19	0.82 ± 6.57	−1.89 ± 3.58**	
	Cortical perimeter (cm)	11.01 ± 0.90	−1.56 ± 5.44	−1.41 ± 6.74	11.04 ± 0.87	−0.57 ± 5.86	−2.27 ± 5.21**	
	Cortical vBMD (mg/cm ³)	663.46 ± 41.99	0.25 ± 3.01	1.08 ± 3.05*	670.78 ± 45.95	0.52 ± 3.86	−0.27 ± 2.37	
	Total vBMD (mg/cm ³)	235.93 ± 40.22	1.25 ± 4.52	2.44 ± 4.11**	234.40 ± 36.90	0.46 ± 4.67	−0.93 ± 4.48	
	CSMI (cm ⁴)	0.58 ± 0.16	0.94 ± 8.55	0.55 ± 12.67	0.57 ± 0.15	−0.20 ± 11.61	−6.71 ± 8.51**	
	SM (cm ³)	0.42 ± 0.11	1.48 ± 7.14	1.79 ± 11.46	0.41 ± 0.10	−0.54 ± 10.51	−4.75 ± 8.84**	
	BR	12.43 ± 3.16	−2.63 ± 6.91*	−3.28 ± 8.87*	13.04 ± 3.19	−0.79 ± 9.49	−1.09 ± 7.99	
	Femoral intertrochanteric region	Cortical thickness (mm)	1.51 ± 0.26	4.74 ± 8.29**	2.98 ± 6.17**	1.50 ± 0.28	−0.52 ± 7.58	−1.67 ± 7.50
		Cortical CSA (cm ²)	1.54 ± 0.29	3.74 ± 6.90**	3.87 ± 5.00**	1.52 ± 0.31	−0.60 ± 6.25	−2.63 ± 6.92*
Total CSA (cm ²)		2.59 ± 0.38	2.95 ± 5.35**	2.33 ± 6.00*	2.57 ± 0.49	0.37 ± 7.83	−2.96 ± 7.51*	
Cortical perimeter (cm)		17.32 ± 1.25	−0.15 ± 3.60	−0.56 ± 4.18	17.19 ± 1.17	0.67 ± 3.67	−1.01 ± 4.13	
Cortical vBMD (mg/cm ³)		641.26 ± 43.08	−0.39 ± 2.14	0.30 ± 2.14	633.80 ± 40.52	0.41 ± 3.30	0.72 ± 2.35	
Total vBMD (mg/cm ³)		194.29 ± 36.90	3.11 ± 5.07**	2.75 ± 5.54**	192.01 ± 32.23	−0.54 ± 6.40	−2.03 ± 6.27*	
CSMI (cm ⁴)		1.67 ± 0.59	6.59 ± 15.98**	3.57 ± 17.38	1.72 ± 0.59	−0.71 ± 17.22	−9.21 ± 15.77**	
SM (cm ³)		0.81 ± 0.25	4.78 ± 14.92*	4.16 ± 17.25	0.83 ± 0.25	−0.16 ± 16.29	−8.47 ± 14.48**	
BR		19.63 ± 4.07	−5.83 ± 8.61**	−2.79 ± 7.53*	19.52 ± 3.98	2.79 ± 12.40	3.74 ± 10.30*	
Femoral shaft		Cortical thickness (mm)	3.95 ± 0.56	1.78 ± 4.98*	0.81 ± 3.79	3.92 ± 0.61	−0.21 ± 5.18	−2.79 ± 4.89**
		Cortical CSA (cm ²)	2.37 ± 0.30	1.62 ± 3.45**	1.48 ± 2.76**	2.33 ± 0.36	0.29 ± 3.50	−0.95 ± 3.12
	Total CSA (cm ²)	2.54 ± 0.29	1.20 ± 3.01**	1.29 ± 2.38**	2.49 ± 0.35	0.12 ± 2.80	−0.67 ± 2.62	
	Cortical perimeter (cm)	10.48 ± 0.75	−0.84 ± 3.93	−1.34 ± 4.30	10.41 ± 0.67	−0.29 ± 5.49	1.31 ± 5.50	
	Cortical vBMD (mg/cm ³)	890.87 ± 70.60	1.55 ± 3.47**	1.29 ± 3.13*	888.05 ± 58.31	0.28 ± 3.79	−0.72 ± 3.21	
	Total vBMD (mg/cm ³)	481.19 ± 80.08	2.83 ± 5.72**	2.11 ± 4.65*	477.68 ± 73.91	0.59 ± 6.13	−1.65 ± 5.98	
	CSMI (cm ⁴)	1.26 ± 0.31	1.03 ± 7.49	3.27 ± 6.08**	1.24 ± 0.24	0.36 ± 4.15	0.74 ± 3.98	
	SM (cm ³)	0.97 ± 0.18	1.73 ± 5.88*	2.95 ± 5.98**	0.96 ± 0.16	−0.18 ± 5.33	−0.62 ± 4.30	
	BR	3.37 ± 0.74	−1.75 ± 6.66	−0.07 ± 4.84	3.39 ± 0.75	0.49 ± 7.87	4.56 ± 7.81**	

Data are means ± SD.

QCT, quantitative computed tomography; CSA, cross-sectional area; vBMD, volumetric bone mineral density; CSMI, cross-sectional moment of inertia; SM, section modulus; BR, buckling ratio; Cortical perimeter; Periosteal cortical perimeter.

* $p < 0.05$.

** $p < 0.01$ compared with baseline by paired t -test.

2. Subjects and methods

2.1. Subjects

The subjects in this study were a subset of female subjects in the ZONE study [2] who were available for CT scans. These subjects were enrolled at one of 17 sites with a multi-detector row computed tomography (MDCT) scanner capable of measuring femoral geometry. Patients eligible for the ZONE study were those diagnosed with primary osteoporosis based on the Diagnostic Criteria for Primary Osteoporosis (2000) by the Japanese Society for Bone and Mineral Research. In short, if a patient had a BMD of <80% of young adult mean (YAM), or possible osteoporosis on radiographic images and a previous history of fragility fracture, the patient was diagnosed as having primary osteoporosis. In a patient with no previous history of fragility fracture, if the BMD was <70% of YAM or osteoporosis was observed on radiographs, the patient was diagnosed as having primary osteoporosis [10]. Patients who had between one and four fractured vertebrae located between the fourth thoracic vertebra and the fourth lumbar vertebra were also included. The following subjects were excluded: patients with any disease or taking any medication that affects bone metabolism; and subjects with decreased renal function who met the criterion for decreased renal function defined as an increase in the serum creatinine level of >0.5 mg/dL during the pretreatment observation period or a creatinine clearance of <35.0 mL/min calculated from the Cockcroft and Gault formula or a urine protein level of 2+ or more at the time of informed consent or on the first day of treatment.

The subjects were randomized into two groups to receive once-yearly intravenous infusions of zoledronic acid 5 mg or placebo over 15 min for two years. All subjects also received daily supplements of calcium 610 mg, vitamin D₃ 400 IU, and magnesium 30 mg. The ZONE study was conducted according to the ethical principles of the

Declaration of Helsinki and the Guidelines for Good Clinical Practice (GCP). The institutional review board (IRB) at each site approved the protocol in advance, and all subjects provided written, informed consent before enrollment.

2.2. CT data acquisition

CT data were obtained using the scanning and reconstruction protocol reported previously at baseline and at 12 and 24 months [11]. The scanning method (X-ray energy, 120 kV; X-ray current, 250 mA; rotation speed, 0.5–0.7 s/rotation; beam pitch, 0.5625–0.938) and the reconstruction parameters were evaluated and determined in advance for each type of CT. Beam pitch is specified as the ratio of table feed per rotation to collimation (slice collimation), which is determined by the slice-thickness and the number of slices in each rotation. Field of view (FOV) was defined as 350 mm to cover bilateral femoral neck regions.

The x-y plane spatial resolution (0.625–0.652 mm) and the reconstructed slice thickness (0.500–0.625 mm) were adjusted depending

on the CT scanner type. CT measurements were converted to bone mineral scale using a reference phantom B-MAS200 (FUJIREBIO Inc., Tokyo, Japan) containing hydroxyapatite (HA) at 0, 50, 100, 150, and 200 mg/cm³.

The MDCT scanners used in this study were: Activision 16 at one study site, Activision TM 16 at two, Aquilion 16 at three, Aquilion 64 at one, Aquilion CXL at one, Asterion Super 4 Edition scanners (Toshiba Medical Systems Corporation, Otawara, Japan) at one, LightSpeed Ultra at one, LightSpeed VCT 64 at one, LightSpeed VCT VI-SION at one, BrightSpeed SD 16ch at one, OptimaCT 660 scanner (GE Yokogawa Medical, Hino, Japan) at one, Somatom Sensation 16 at two, and Somatom Definition AS + scanner (Siemens AG, Munich, Germany) at one. Basically, a subject was scanned using the same CT scanner throughout the study period, but one of the study sites that used the Somatom Sensation 16 switched to a different model, Aquilion 64 TSX-101A scanner (Toshiba Medical Systems Corporation), for taking measurements midway through the study. The quality control (QC) data were checked before and after the switch with a Type 3 Mindways Phantom (Mindways Software, Austin, TX, USA).

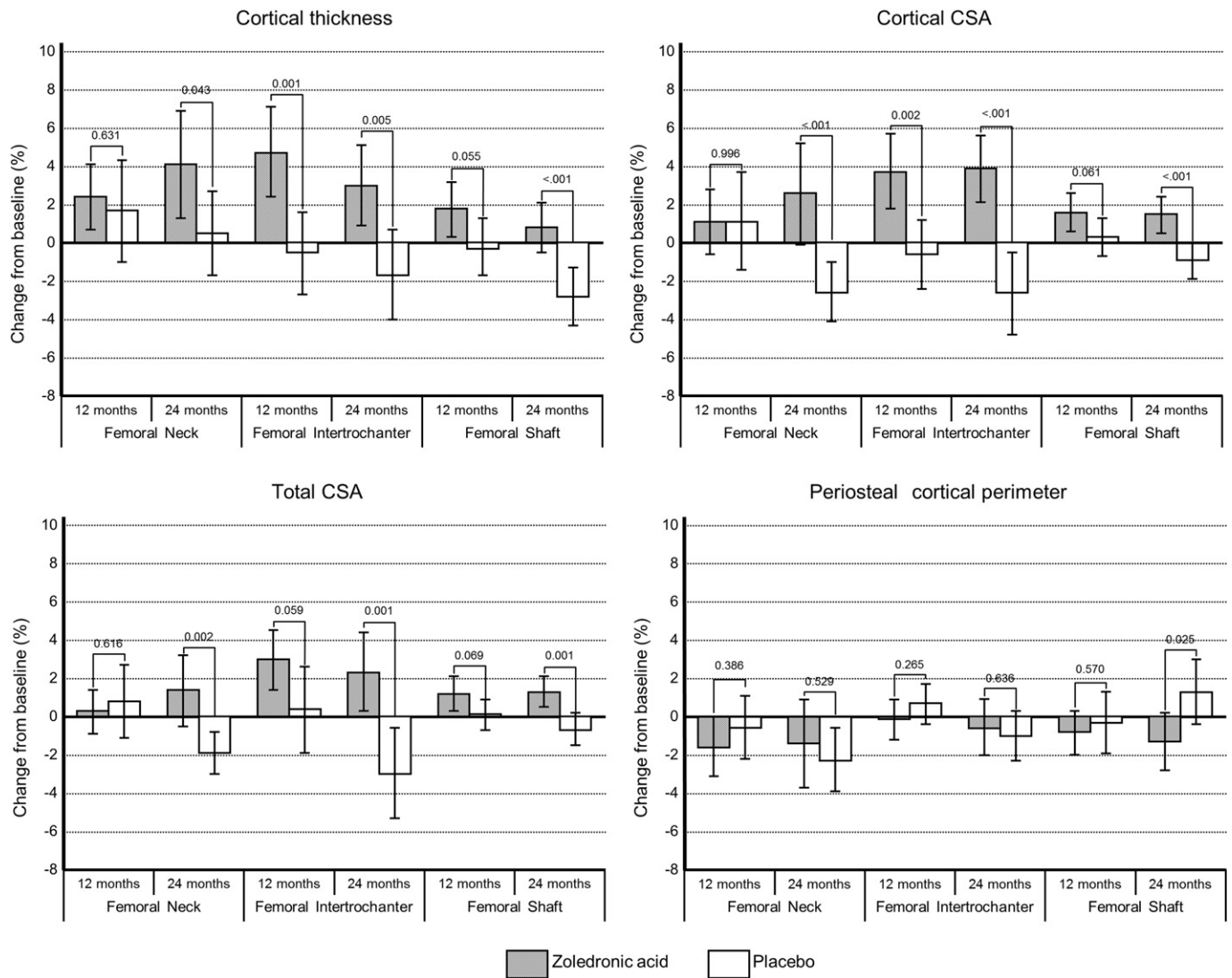


Fig. 1. Mean percent changes and 95% confidence interval from baseline in cortical thickness (a), cortical cross-sectional area (CSA) (b), total CSA (c), and periosteal cortical perimeter (d) at 12 months and 24 months with zoledronic acid and placebo. Changes at the femoral neck, femoral intertrochanteric region, and femoral shaft are shown. Values on top of each panel indicate p-values between zoledronic acid and placebo. To compare the differences between the two groups, the percent changes from baseline in QCT parameters were compared by Student's *t*-test.

2.3. Quality assurance of scanners

All CT scanners gave good positive linear correlations between CT values and HA concentrations ($r = 0.994\text{--}1.000$; $p < 0.0001$). Differences in CT values due to X-ray energy fluctuations were corrected using a phantom to convert CT values to HA values. To correct changes in the detector over the long-term, reliability assurance with a Type 3 Mindways Phantom (Mindways Software) was performed before and after measurements at each of the medical institutions. The reliability-assurance measurements were conducted in accordance with Mindways' QCT-Pro QA Guide. No changes in performance characteristics were noted with any of the CT scanners between baseline and completion of treatment.

2.4. Subject positioning for CT scanning

The femur of each of the subjects was scanned from the top of the acetabulum to 4 cm below the bottom of the lesser trochanter with the subject in a supine position and the phantom placed underneath the subject (mean number of slices, 350). A cushioning material such as a bolus bag or blanket was placed between the subject and the phantom to prevent artifacts, and the subject's hands and arms were positioned overhead or higher than the chest to avoid any impacts on the scan area. The CT scanner table height was set to the center of the greater trochanter.

2.5. Analyses of BMD, bone geometry, and biomechanical parameters obtained by CT

The subjects' femoral neck, intertrochanteric region, and shaft data were evaluated with QCT-Pro software v4.1.3 with the QCT-Pro Bone Investigational Toolkit v2.0 (BIT) (Mindways Software). All measurement data were analyzed by a single radiologist who was blinded to the case information.

2.6. QCT-Pro CTXA femoral neck analysis

Using the eccentricity registration method, a series of six consecutive 1-mm slices were placed vertically to the neck axis. The definitions of intertrochanteric region and shaft cross-sections were identical to

those in the dual energy X-ray absorptiometry (DXA)-based hip structure analysis (HSA) developed by Beck [12]. All images acquired from a subject during the study period were compared visually and matched. In the eccentricity registration method, the area consisting of six consecutive 1-mm slices of the image oriented perpendicular to the neck axis was defined as a 3-dimensional region of interest. The QCT BIT processing was performed with a fixed threshold for determining the cortical margin set to 350 mg/cm^3 for all subjects and measurements. This application was used to measure volumetric BMD (vBMD) and cross-sectional area (CSA) and cross-sectional bone mass of the femoral neck, intertrochanteric region, and shaft (total and cortical bone area), as well as cortical thickness and periosteal cortical perimeter. Bone biomechanical parameters were also calculated from the cross-sectional parameters of the femoral neck, intertrochanteric region, and shaft with the QCT-Pro software.

2.7. Analysis of cross-sectional area, vBMD, and bone mass

The cortical CSA (cm^2), total CSA (cm^2), cortical vBMD (mg/cm^3), total vBMD (mg/cm^3), total bone mass (g), cortical bone mass (g), thickness (mm), and periosteal cortical perimeter (cm) were calculated based on the cross-sectional data for the femoral neck, intertrochanteric region, and shaft. The CSA was determined from the estimated total mineralization area.

2.8. Bone biomechanical parameters

Biomechanical parameters including the cross-sectional moment of inertia (CSMI; cm^4), the sectional modulus (SM; cm^4), and the buckling ratio (BR) were calculated. The CSMI was calculated by integration of the CSA of the mineralized cortical bone and the square of the distance from the center of mass (centroid). The SM is the ratio of CSMI to the maximal distance from the centroid, which is an index correlated to bending strength. The local BR was calculated by dividing the maximal distance from the centroid with the cortical thickness, which is an index of structural stability [12].

The reproducibility of the analysis by the QCT-Pro program was reported previously [8].

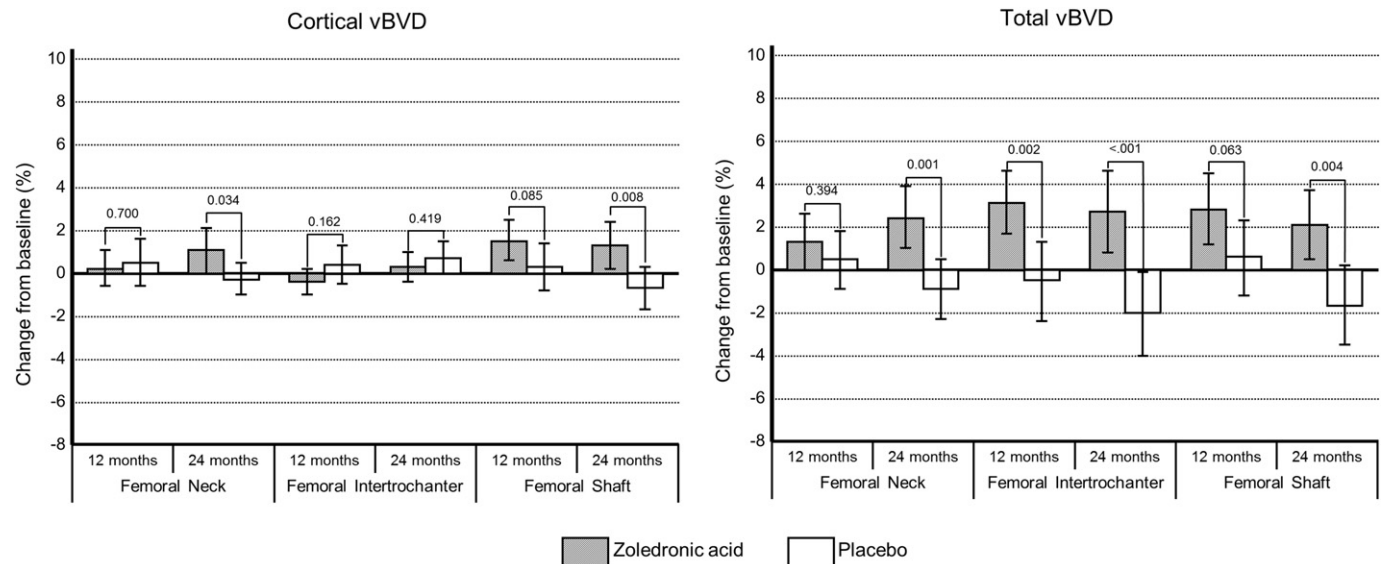


Fig. 2. Mean percent changes and 95% confidence interval from baseline in cortical volumetric bone mineral density (vBMD) (a) and total vBMD (b) at 12 months and 24 months with zoledronic acid and placebo. Changes at the femoral neck, femoral intertrochanteric region, and femoral shaft are shown. Values on top of each panel indicate p-values between zoledronic acid and placebo. To compare differences between the two groups, the percent changes from baseline in QCT parameters were compared by Student's *t*-test.

2.9. Statistics

All statistical analyses were performed on subjects who had been randomized and had completed the QCT evaluations at baseline and at 12 and 24 months. The methods used included Student's *t*-tests for comparing the zoledronic acid group with the placebo group for percent change from baseline and paired *t*-tests for comparing baseline values with those at 12 or 24 months. The *p* values were two-sided, without multiplicity adjustment. Statistical analyses were performed with SAS version 9.4 (SAS Institute, Cary, NC, USA).

3. Results

3.1. Subject demographics and baseline bone characteristics

The subject demographics and baseline bone characteristics for each group are shown in Table 1. In the ZONE study, 112 (8 male subjects and 104 female subjects) of the 665 subjects administered zoledronic acid or placebo underwent QCT scans. All subjects in the analysis in the present study were female, including 49 in the zoledronic acid group and 53 in the placebo group. There were no significant differences between the

two groups in age, height, weight, body mass index (BMI), years after menopause, BMD at the lumbar spine and proximal femur, and the number of vertebral fractures. The baseline characteristics (age, height, weight, BMI, menopausal age, and T-score) of the subjects of this study were similar to those of the ZONE study [2]; thus, the population was representative of the population of the ZONE study.

3.2. Effects of zoledronic acid on changes from baseline in various parameters

The baseline and percent changes (%) at 12 and 24 months for QCT parameters from baseline are shown in Table 2. There were no remarkable differences at baseline for any parameter at the femoral neck, intertrochanteric region, and shaft between the zoledronic acid and placebo groups.

In summary, compared with baseline, once-yearly treatment with zoledronic acid significantly improved: cortical thickness at the neck and intertrochanteric region; cortical CSA and total CSA at the intertrochanteric region and shaft; total vBMD at all sites; cortical vBMD at the neck and shaft; SM and CSMI at the shaft; and BR at the intertrochanteric region and neck. There were no changes from baseline

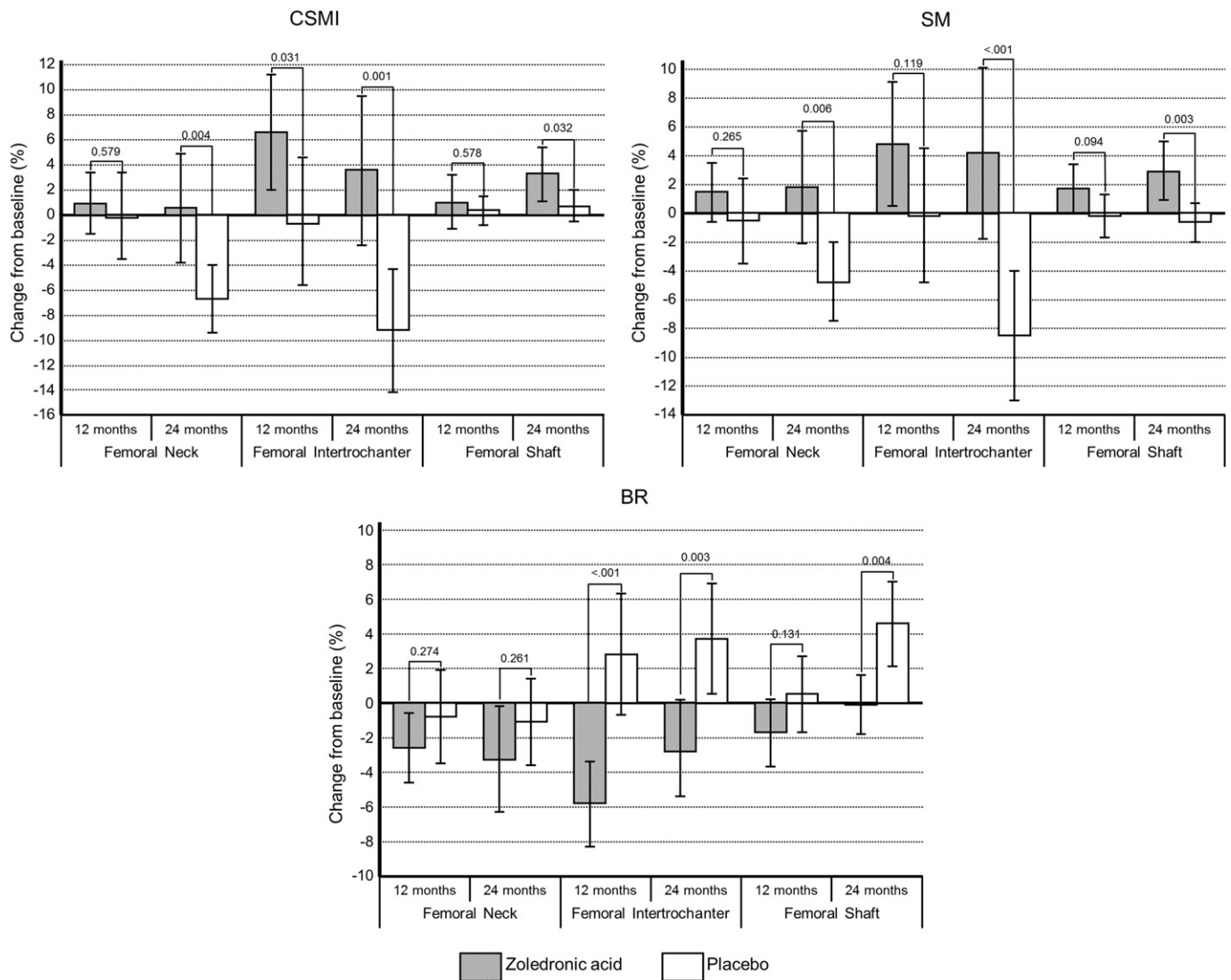


Fig. 3. Mean percent changes and 95% confidence interval from baseline in cross-sectional moment of inertia (CSMI) (a), section modulus (SM) (b), and buckling ratio (BR) (c) at 12 months and 24 months with zoledronic acid and placebo. Changes at the femoral neck, femoral intertrochanteric region, and femoral shaft are shown. Values on top of each panel indicate *p*-values between zoledronic acid and placebo. To compare the differences between the two groups, the percent changes from baseline in QCT parameters were compared by Student's *t*-test.

in the periosteal cortical perimeter at any site in the zoledronic acid group.

3.3. Effects of zoledronic acid treatment on cortical bone geometry compared with placebo

Percent changes from baseline in cortical thickness, cortical CSA, total CSA, and periosteal cortical perimeter are shown in Fig. 1.

In summary, cortical thickness, cortical CSA, and total CSA were significantly higher at all sites in the zoledronic acid group than in the placebo group at 24 months.

3.4. Effects of zoledronic acid on vBMD compared with placebo

Percent changes from baseline in cortical vBMD and total vBMD are shown in Fig. 2.

In summary, total vBMD in the zoledronic acid group was significantly higher at all sites at 24 months, and cortical vBMD was also significantly higher at the femoral neck and shaft than in the placebo group at 24 months.

3.5. Effects of zoledronic acid on CT-derived bone biomechanical parameters compared with placebo

Percent changes from baseline in CSMI, SM, and BR are shown in Fig. 3.

In summary, CSMI and SM were significantly higher at all sites at 24 months, and BR was significantly lower at the femoral intertrochanteric region and shaft in the zoledronic acid group than in the placebo group at 24 months.

4. Discussion

This study evaluated the effects of 2-year treatment with once-yearly intravenous infusions of zoledronic acid on femoral cortical bone geometry, vBMD, and CT-derived biomechanical parameters in a subset of 102 female subjects in the ZONE study, which was conducted in Japanese patients with osteoporosis. This is the first CT assessment of the effect of bisphosphonates on hip geometry in Japanese female subjects. Data from this study demonstrated that once-yearly intravenous infusions of zoledronic acid improved vBMD, cortical bone geometry parameters, and CT-derived biomechanical parameters at the femoral neck, intertrochanteric region, and shaft; particularly at the intertrochanteric region, improvements in cortical bone geometry parameters and biomechanical parameters, compared with those in the placebo group, were already significant at 12 months.

In this study, higher total vBMD was observed at the femoral neck, intertrochanteric region, and shaft in the zoledronic acid group compared with the placebo group. Similarly, the vBMD evaluation by CT performed in the HORIZON-PFT study showed significantly higher integral vBMD at the femoral neck and intertrochanteric region at 36 months (total 230 subjects) [13]. An examination of the effect on cortical vBMD showed no difference between the zoledronic acid and placebo

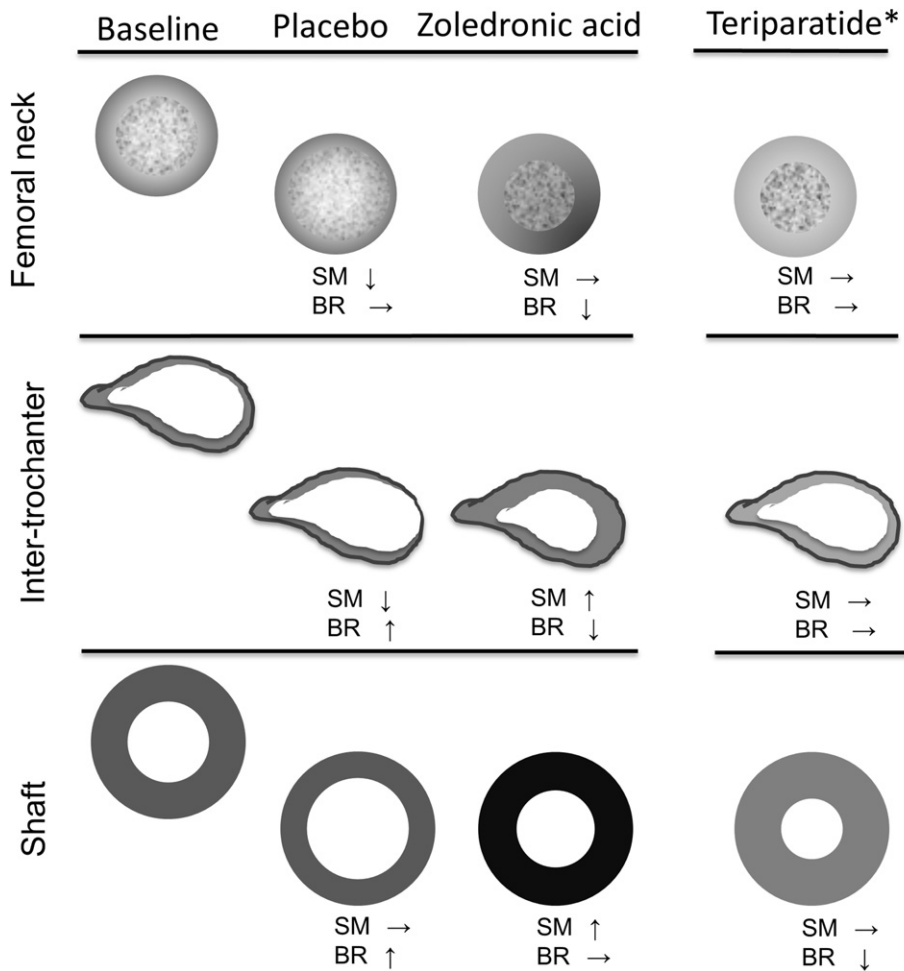


Fig. 4. Schematic illustration of the effects of zoledronic acid on cortical geometry and density of the femoral neck, intertrochanteric region, and shaft, compared to placebo. The darker black in the periphery indicates a higher vBMD. SM: section modulus, BR: buckling ratio. The effect of once-weekly teriparatide treatment on the proximal femur is illustrated based on the previous paper [8].

groups in the HORIZON-PFT study. In the present study, however, significantly higher cortical vBMD was observed in the neck and shaft at 24 months. While it is difficult to make a comparison between the HORIZON-PFT study and the ZONE study due to the use of different analytical programs and differences in imaging conditions and subject demographics, the ZONE study demonstrated the effect of 2-year treatment with zoledronic acid in significantly increasing cortical vBMD at the femoral neck and shaft, but the increase was not significant at the intertrochanteric region. This discrepancy among bone sites may be attributable to the effect of zoledronic acid on reduction in cortical porosity [14]. Increases of cortical vBMD are readily detectable in the neck and shaft, which is thick in cortical bone, and changes in cortical vBMD are difficult to detect by CT in the intertrochanteric region, which is thin in cortical bone.

A comparison was made with the results of studies on the effects of bisphosphonates on hip geometry. The effects of monthly ibandronate on the geometric properties of the hip were evaluated by DXA-based HSA in 89 Caucasian men with low BMD and compared with placebo, and the study demonstrated that cortical thickness, CSA, SM, and BR were significantly improved in the femoral intertrochanteric region and shaft compared with placebo, but the difference was not significant in the narrow neck [15]. The results of this study in Caucasian subjects were similar to those of the present study in terms of the effects on structural characteristics, although there was a difference in whether the effect was significant.

There has been one study that evaluated vBMD and bone geometry properties with CT in a similar manner in a subset of subjects who received once-weekly teriparatide in the TOWER trial [8]. The once-weekly teriparatide treatment for 72 weeks was shown to improve cortical thickness, cortical CSA, and CT-derived bone biomechanical parameters compared with placebo treatment. Moreover, as a result of teriparatide treatment, total vBMD remained at or increased from the baseline level, while cortical vBMD decreased slightly. This shows that the once-weekly teriparatide treatment had an effect in maintaining the bone perimeter while increasing Haversian remodeling and cortical porosity, or lowering the material density, or both, in the inner cortical region, suggesting that bone strength improves in association with such a process [8]. Both teriparatide and bisphosphonates improve bone biomechanical properties, but by different tissue level mechanisms of action. As a result, their effects on vBMD and bone geometry are also different (Fig. 4). In other words, the structural properties analyzed based on CT indicated that the two agents have different effects on the cortical bone; while teriparatide increases cortical and trabecular bone volume to improve bone strength, zoledronic acid prevents thinning of the cortex, decreases the rate of remodeling, and reduces cortical porosity, thus acting differently to improve bone strength.

Moreover, in the intertrochanteric region, despite significant increases from baseline in cortical CSA with both zoledronic acid and teriparatide, a difference in cortical thickness was noted: no change in cortical thickness was detected with teriparatide treatment, but the cortical thickness increased significantly at 12 months with zoledronic acid treatment. Such a difference is mainly attributable to the difficulty in detecting changes in the cortical bone of the intertrochanteric region due to the thinness of the cortical bone. With teriparatide, the new cortical bone formed at the endocortical surface was poorly mineralized and porous and was not perceived as an increased cortical thickness on CT [16]. With zoledronic acid, on the other hand, the cortical bone thickness was preserved or increased as a result of suppression of excessive bone resorption.

Although the comparison between the two drugs used results derived from different studies rather than a study that directly compared the drugs' effects, the difference in bone structural change described above may be reflected by a difference in effect between a bone resorption inhibitor and a bone formation stimulator.

The ZONE study in Japanese patients with osteoporosis did not demonstrate an inhibitory effect on hip fractures because it was conducted

in a small number of subjects over a short study period (total 665 subjects joined, 2-year study), and none of the subjects assessed in this QCT study suffered any femoral fractures during the study period. A large-scale international clinical trial of zoledronic acid in patients with osteoporosis, however, demonstrated that zoledronic acid significantly reduced the risk of hip fractures [1]. Furthermore, the previous study of CT-based hip structure analysis compared the characteristics of vBMD and bone geometry of the femoral neck. The comparison between subjects with hip fracture and age/sex-matched subjects with no fracture showed the following risk factors: low total vBMD, cortical vBMD, cortical CSA, cortical thickness, and CSMI for both femoral neck and intertrochanteric fracture, and high BR for femoral neck fracture [11]. In this study, SM increased and BR decreased in the zoledronic acid group, showing that zoledronic acid treatment improved hip fracture-related parameters. Only at the femoral neck, no significant differences in BR were noted between the zoledronic acid and placebo group, but BR was significantly lower in the zoledronic acid group relative to baseline at both 12 and 24 months. The data presented above suggest that zoledronic acid may reduce the risk of the occurrence of hip fractures in Japanese osteoporotic patients.

The results of the present study are explorative and we hope to validate them in future larger studies.

This study has two limitations. One is derived from the analysis using CT, and the other is derived from the small number of subjects. This study used the global BMD-based threshold of QCT-Pro as the analysis program, and the BMD value of each slice measured with the reference phantom showed good reproducibility (<0.1%). Since the cortical bone in the superior part of the femoral neck is remarkably thin, and there might be a partial volume effect in this part, the slice thickness was set as thin as possible (0.500–0.625 mm) to minimize the effect.

Another limitation of this study was that the number of subjects was small and not representative of all subjects who receive zoledronic acid treatment, because the subjects had to meet the inclusion criteria prescribed in the protocol, and the medical institutions had to meet the condition of being equipped with an MDCT scanner capable of certain functions. In the future, it will be necessary to confirm the effect of zoledronic acid on the prevention of hip fractures in Japanese women.

In conclusion, once-yearly zoledronic acid treatment increased BMD at all femoral sites, including the femoral neck, intertrochanteric region, and shaft, and improved cortical bone geometry and CT-derived bone biomechanical parameters in this study. Zoledronic acid may inhibit hip fractures in Japanese osteoporotic patients.

Declaration of interest

MI has received research grants from Asahi-Kasei Pharma, Astellas Pharma, Chugai Pharmaceutical, Daiichi-Sankyo, MSD, and Ono Pharmaceutical, and consulting fees from Asahi-Kasei Pharma and Ono Pharmaceutical. TS has received research grants from Asahi-Kasei Pharma, Astellas Pharma, Daiichi-Sankyo, Taisho Toyama Pharmaceutical, Takeda Pharmaceutical, Pfizer, and Teijin Pharma and consulting fees from Takeda Pharmaceutical. MS has received consulting fees from Asahi Kasei Pharma, MSD, and Teijin Pharma and received lecture fees from Chugai Pharmaceutical, Daiichi-Sankyo, Eisai, Eli Lilly Japan, Ono Pharmaceutical, and Pfizer. ST, CI, and YO are employees of Asahi Kasei Pharma. TN has received consulting fees from Asahi-Kasei Pharma, Amgen, Chugai Pharmaceutical, Daiichi-Sankyo, MSD, Taisho Toyama Pharmaceutical, and Teijin Pharma.

Acknowledgments

The authors would like to thank the investigators of the study and acknowledge Novartis Pharma AG for editorial assistance with this manuscript. The corresponding author had full access to all of the data in the study and had responsibility for the decision to submit for publication. The sponsor had responsibility for quality control.

Funding

The study was sponsored by Asahi-Kasei Pharma Corporation, Tokyo, Japan.

Role of funding source

Asahi-Kasei Pharma Corporation, was responsible for quality control. The corresponding author had full access to all of the data in the study and had responsibility for the decision to submit for publication.

Clinical trial registration

The clinical trial registration number identifier (www.clinicaltrials.gov) for this study is NCT01522521.

References

- [1] D.M. Black, P.D. Delmas, R. Eastel, I.R. Reid, S. Boonen, J.A. Cauley, et al., Once-yearly zoledronic acid for treatment of postmenopausal osteoporosis, *N. Engl. J. Med.* 356 (2007) 1809–1822.
- [2] T. Nakamura, M. Fukunaga, T. Nakano, H. Kishimoto, M. Ito, H. Hagino, et al., Efficacy and safety of once-yearly zoledronic acid in Japanese patients with primary osteoporosis: two-year results from a randomized placebo-controlled double-blind study (ZOledroNate treatment in Efficacy to osteoporosis; ZONE study), *Osteoporos. Int.* 28 (2017) 389–398.
- [3] D.M. Black, J.P. Bilezikian, K.E. Ensrud, S.L. Greenspan, L. Palermo, T. Hue, et al., One year of alendronate after one year of parathyroid hormone (1–84) for osteoporosis, *N. Engl. J. Med.* 353 (2005) 555–565.
- [4] D.M. Black, S.L. Greenspan, K.E. Ensrud, L. Palermo, J.A. McGowan, T.F. Lang, et al., The effects of parathyroid hormone and alendronate alone or in combination in postmenopausal osteoporosis, *N. Engl. J. Med.* 349 (2003) 1207–1215.
- [5] T. Lang, A. LeBlanc, H. Evans, Y. Lu, H. Genant, A. Yu, Cortical and trabecular bone mineral loss from the spine and hip in long-duration spaceflight, *J. Bone Miner. Res.* 19 (2004) 1006–1012.
- [6] B.L. Riggs, I.I.I.L.J. Melton, R.A. Robb, J.J. Camp, E.J. Atkinson, J.M. Peterson, et al., Population-based study of age and sex differences in bone volumetric density, size, geometry, and structure at different skeletal sites, *J. Bone Miner. Res.* 19 (2004) 1945–1954.
- [7] M. Ito, T. Nakamura, M. Fukunaga, M. Shiraki, T. Matsumoto, Effect of eldelcalcitol, an active vitamin D analog, on hip structure and biomechanical properties: 3D assessment by clinical CT, *Bone* 49 (2011) 328–334.
- [8] M. Ito, R. Oishi, M. Fukunaga, T. Sone, T. Sugimoto, M. Shiraki, et al., The effects of once-weekly teriparatide on hip structure and biomechanical properties assessed by CT, *Osteoporos. Int.* 25 (2014) 1163–1172.
- [9] J. Borggreffe, G. Christian, N.N. Thomas, M. Fernando, C.G. Claus, Quantitative computed tomographic assessment of the effects of 24 months of teriparatide treatment on 3D femoral neck bone distribution, geometry, and bone strength: results from EUROFORs study, *J. Bone Miner. Res.* 25 (2010) 472–481.
- [10] H. Orimo, Y. Hayashi, M. Fukunaga, T. Sone, S. Fujiwara, M. Shiraki, et al., Diagnostic criteria for primary osteoporosis: year 2000 revision, *J. Bone Miner. Metab.* 19 (2001) 331–337.
- [11] M. Ito, N. Wakao, T. Hida, Y. Matui, Y. Abe, K. Aoyagi, et al., Analysis of hip geometry by clinical CT for the assessment of hip fracture risk in elderly Japanese women, *Bone* 46 (2010) 453–457.
- [12] J.B. Thomas, L.O. Tammy, L.S. Katie, B.R. Christopher, E. Kristine, C.N. Michael, et al., Structural adaptation to changing skeletal load in the progression toward hip fragility: the study of osteoporotic fractures, *J. Bone Miner. Res.* 16 (2001) 1108–1119.
- [13] T. Eastell, T. Lang, S. Boonen, S. Cummings, P.D. Delmas, J.A. Cauley, et al., Effect of once-yearly zoledronic acid on the spine and hip as measured by quantitative computed tomography: results of the HORIZON pivotal fracture trial, *Osteoporos. Int.* 21 (2010) 1277–1285.
- [14] F. Cosman, E.F. Eriksen, C. Recknor, P.D. Miller, N. Guanabens, C. Jasoerj, et al., Effects of intravenous Zoledronic acid plus subcutaneous teriparatide [rhPTH(1–34)] in postmenopausal osteoporosis, *J. Bone Miner. Res.* 26 (2011) 503–511.
- [15] H.K. Genant, E.M. Lewiecki, T. Fuerst, M. Fries, Effect of monthly ibandronate on hip structural geometry in men with low bone density, *Osteoporos. Int.* 23 (2012) 257–265.
- [16] M.M. Barbara, P.P. Eleftherios, B. Stephane, F.Z. Nadja, K. Klaus, R. Paul, Effects of 1 year of daily teriparatide treatment on iliac bone mineralization density distribution (BMDD) in postmenopausal osteoporotic women previously treated with alendronate or risedronate, *J. Bone Miner. Res.* 25 (2010) 2297–2303.