

JHG-17-184 R1

SHORT COMMUNICATION

Maternally-derived 15q11.2-q13.1 Duplication and *H19*-DMR Hypomethylation in a Patient with Silver-Russell Syndrome

Sumito Dateki^{1*}, Masayo Kagami², Keiko Matsubara², Kei Izumi¹, Satoshi Watanabe¹, Akiko Nakatomi¹, Tatsuro Kondoh³, Maki Fukami², and Hiroyuki Moriuchi¹

¹ Department of Pediatrics, Nagasaki University Graduate School of Biomedical Sciences, Nagasaki, Japan

² Department of Molecular Endocrinology, National Research Institute for Child Health and Development, Tokyo, Japan

³ Misakaenosono Mutsumi Developmental, Medical, and Welfare Center, Isahaya, Japan

Running title: 15q duplication with SRS

Number of text pages: 10

Number of abstract words: 187 words

Number of text words: 1000 words.

Number of references: 15

Table: 1

Figures: 2

Supplementary Table: 1

*Correspondence to:

Sumito Dateki, M.D.

Department of Pediatrics, Nagasaki University Graduate School of Biomedical Sciences

Address: 1-7-1 Sakamoto, Nagasaki, 852-8501 Japan

E-mail: sdateki1@nagasaki-u.ac.jp

Phone: +81-95-819-7298

FAX: +81-95-819-7301

ABSTRACT

Silver-Russel syndrome (SRS) is a congenital developmental disorder characterized by intrauterine and postnatal growth failure, relative macrocephaly, protruding forehead, body asymmetry, and feeding difficulties. Hypomethylation of the *H19* differentially methylated region (DMR) on chromosome 11p15.5 is the most common cause of the SRS phenotype. We report the first SRS patient with hypomethylation of the *H19*-DMR and maternally-derived 15q11.2-q13.1 duplication. Although her clinical manifestations overlapped with those of previously reported SRS cases, the patient's intellectual disability and facial dysmorphic features were inconsistent with the SRS phenotype. Methylation analyses, array comparative genomic hybridization, and a FISH analysis revealed the hypomethylation of the *H19*-DMR and a maternally-derived interstitial 5.7-Mb duplication at 15q11.2-q13.1 encompassing the Prader-Willi/Angelman critical region in the patient. Based on the genetic and clinical findings in the present and previously reported cases, it is unlikely that the 15q duplication in the patient led to the development of hypomethylation of the *H19*-DMR and it is reasonable to consider that the characteristic phenotype in the patient was caused by the coexistence of the two (epi)genetic conditions. Further studies are needed to clarify the mechanisms leading to methylation aberrations in SRS.

Keywords: Silver Russel syndrome, 15q duplication, short stature, *H19*-DMR

INTRODUCTION

Silver-Russel syndrome (SRS) is a congenital developmental disorder characterized by intrauterine and postnatal growth failure, relative macrocephaly, protruding forehead, body asymmetry, and feeding difficulties (OMIM 180860). SRS is mainly caused by the hypomethylation of the *H19*-differentially methylated region (DMR) on chromosome 11p15.5 and maternal uniparental chromosome 7 (upd[7]mat), which account for ~40% and 5-10% of SRS patients, respectively. In addition, several other (epi)genetic aberrations, including 14q32 abnormalities, a heterozygous 15q26.3 deletion, and multi-locus imprinting disturbance have been identified in a small fraction of SRS-like patients.¹⁻³

15q11.2-q13.1 duplication syndrome is characterized by hypotonia, motor delays, intellectual disability, autism spectrum disorder (ASD), and epilepsy (OMIM 608636).⁴ This condition is caused by the presence of at least one extra maternally-derived copy of the Prader-Willi/Angelman critical region (PWACR) within chromosome 15q11.2-q13.1, whereas individuals with paternally-derived 15q11-q13 duplication are unlikely to develop symptoms.^{5,6}

We herein report the clinical and genetic findings in the first SRS patient with a maternally-derived 15q11.2-q13.1 duplication, and discuss the relationship between hypomethylation of the *H19*-DMR and 15q11.2-q13.1 duplication in the patient.

CASE REPORT

A Japanese girl was born at 39 weeks' gestation. At birth, her body length was 37.5 cm (−5.0 s.d.), her body weight was 1.47 kg (−5.0 s.d.) and her occipitofrontal circumference was 34.5 cm (+1.0 s.d.). She was diagnosed with SRS in infancy because the clinical features satisfied five of the six key features in the Netchine–Harbison SRS clinical scoring system (prenatal growth retardation, relative macrocephaly, protruding forehead, body asymmetry,

and feeding difficulties).⁷ She also had dysmorphic facial features (upturned nose, down-slanting palpebral fissures, hypertelorism, and low-set ears), which are observed less frequently in patients with SRS (Figure 1a and b; Table 1). She had severe hypotonia and failure to thrive in infancy. Her motor development was obviously delayed; she held up her head at 9 months, rolled over at 10 months, and walked at 2 years and 6 months.

At 9 years of age, treatment with a long-acting gonadotropin-releasing hormone analog was initiated because she entered puberty with severe short stature (-4.8 s.d.); however, the therapy had only modest effects on her growth (Figure 1c). At the last examination, at 15 years of age, she measured 131.2 cm (final adult height, -5.0 s.d.) and weighed 21 kg (-4.0 s.d.). She had intellectual disability (total IQ, 67).

Her non-consanguineous parents and elder sister were clinically normal. Her father and mother were 180 cm (+0.6 s.d.) and 152 cm (-1.3 s.d.) tall, respectively. There was no family history of seizure, neurodevelopmental diseases, or congenital malformation.

MOLECULAR STUDIES

This study was approved by the Institutional Review Board Committee at the National Center for Child Health and Development. DNA was obtained from peripheral blood samples from the patient and her parents after obtaining written informed consent.

First, we performed pyrosequencing-based methylation analyses for two DMRs responsible for SRS (*H19*-DMR and *PEG1/MEST*-DMR on chromosome 7), as previously reported.^{8,9} The results showed profound hypomethylation of the *H19*-DMR in the patient. Subsequently, we performed methylation analyses for other DMRs related to known imprinting disorders to search for multilocus imprinting disturbance, and found mild hypermethylation of the *SNRPN*-DMR at 15q11.2 (Figure 2a and Supplementary Table 1).

Because the patient's intellectual disability and facial dysmorphic features were

inconsistent with the SRS phenotype, we performed oligoarray comparative genomic hybridization using a human catalog array (2x400K format, ID G4448A; Agilent Technologies, Santa Clara, CA, USA) to identify other mechanisms leading to the phenotype. This revealed a 5.7-Mb duplication at 15q11.2-q13.1 encompassing the PWACR (Figure 2b). The duplication was also identified in the patient's mother. Fluorescence *in situ* hybridization with an *SNRPN* probe for PWACR detected two signals with a marked difference in intensity (a normal signal and an intense signal), indicating that this was an interstitial tandem duplication (Figure 2c). A methylation analysis of the mother revealed mild hypomethylation at the *SNRPN* DMR in contrast to the results in the patient (Figure 2a and Supplementary Table 1).

DISCUSSION

We identified hypomethylation of the *H19*-DMR and a maternally-derived 15q11.2-q13.1 duplication in a patient with SRS. The patient had typical SRS manifestations as well as intellectual disability and dysmorphic facial features, which are common in patients with 15q11.2-q13.1 duplication syndrome, but not in SRS patients (Figure 1 and Table 1).¹⁰⁻¹² These findings imply that the characteristic phenotype in the patient was likely caused by the coexistence of two rare epigenetic and genetic conditions.

The genetic basis for the development of *H19*-DMR hypomethylation in SRS patients remains to be explored.^{1,3} No unambiguous genomic aberrations in patients with hypomethylation of the *H19*-DMR have been identified thus far.^{1,13,14} In this regard, it is unlikely that the 15q11.2-q13.1 duplication in the present patient led to the development of hypomethylation of the *H19*-DMR for the following reasons. First, although over 30 different copy number variations have been reported in patients with the SRS phenotype, 15q11.2-q13.1 duplications have not been reported in SRS patients.^{1,13-15} Second, although patients with 15q11.2-q13.1 duplication show methylation abnormalities of the *SNRPN*-DMR,

those of the *H19*-DMR or other DMRs have not been reported in those patients. Third, the major manifestations seen in SRS patients (postnatal growth failure, relative macrocephaly, clinodactyly, and body asymmetry) have rarely (or never) been detected in patients with 15q11.2-q13.1 duplications.¹⁰⁻¹² Taken together, the two rare (epi)genetic conditions seemed to co-exist in the patient by chance.

The phenotypically normal mother also had the same 15q duplication. In this regard, since the duplicated region including the PWACR is imprinted, almost all of the previously reported children who inherit the duplicated allele from their mothers develop symptoms, whereas those who inherit it from their fathers are unlikely to develop symptoms.^{6, 10-12} Hypomethylation at the *SNRPN* DMR, which is methylated on the maternal allele, indicates the paternal origin of the duplication in the mother.³ These findings are consistent with the normal phenotype of the mother.

In conclusion, we reported the first case of *H19*-DMR hypomethylation and maternally-derived interstitial 15q11.2-q13.1 duplication. Further studies are needed to clarify the mechanisms leading to the epimutation in SRS patients.

CONFLICTS OF INTEREST

The authors declare no conflicts of interest in association with the present study.

ACKNOWLEDGEMENTS

We thank the patient and the family who participated in this study. This work was supported by Grants from the Japan Society for the Promotion of Science (JSPS) (15K15096), the National Center for Child Health and Development (28-6), the Japan Agency for Medical Research and Development (AMED) (16ek0109030h0003, 16ek0109141h0002), Takeda Science Foundation, and The Japanese Society for Pediatric Endocrinology Future Development Grant.

REFERENCES

1. Wakeling, E. L., Brioude, F., Lokulo-Sodipe, O., O'Connell, S. M., Salem, J., Blik, J. *et al.* Diagnosis and management of Silver-Russell syndrome: first international consensus statement. *Nat. Rev. Endocrinol.* **13**, 105–124 (2017).
2. Fuke, T., Mizuno, S., Nagai, T., Hasegawa, T., Horikawa, R., Miyoshi, Y., *et al.* Molecular and clinical studies in 138 Japanese patients with Silver-Russell syndrome. *PLoS. One.* **8**, e60105 (2013).
3. Eggermann, T., Perez, de, Nanclares, G., Maher, E.R., Temple, I.K., Tümer, Z., Monk, D., *et al.* Imprinting disorders: a group of congenital disorders with overlapping patterns of molecular changes affecting imprinted loci. *Clin. Epigenetics.* **7**, 123 (2015).
4. Bunday, S., Hardy, C., Vickers, S., Kilpatrick, M.W., Corbett, J.A. Duplication of the 15q11-13 region in a patient with autism, epilepsy and ataxia. *Dev. Med. Child. Neurol.* **36**, 736–742 (1994).
5. Noor, A., Dupuis, L., Mittal, K., Lionel, A.C., Marshall, C.R., Scherer, S.W., *et al.* 15q11.2 Duplication Encompassing Only the UBE3A Gene Is Associated with Developmental Delay and Neuropsychiatric Phenotypes. *Hum. Mutat.* **36**, 689–693 (2015).
6. Cook, E.H. Jr., Lindgren, V., Leventhal, B.L., Courchesne, R., Lincoln, A., Shulman, C. *et al.* Autism or atypical autism in maternally but not paternally derived proximal 15q duplication. *Am. J. Hum. Genet.* **60**, 928–934 (1997).
7. Netchine, I., Rossignol, S., Dufourg, M.N., Azzi, S., Rousseau, A., Perin, L., *et al.* 11p15 imprinting center region 1 loss of methylation is a common and specific cause of typical Russell-Silver syndrome: clinical scoring system and epigenetic-phenotypic correlations. *J. Clin. Endocrinol. Metab.* **92**, 3148–3154 (2007).

8. Kagami, M., Mizuno, S., Matsubara, K., Nakabayashi, K., Sano, S., Fuke, T., *et al.* mutations of the IG-DMR and the MEG3-DMR at the 14q32.2 imprinted region in two patients with Silver-Russell Syndrome-compatible phenotype. *Eur. J. Hum. Genet.* **23**, 1062–1067 (2015).
9. Kagami, M., Matsubara, K., Nakabayashi, K., Nakamura, A., Sano, S., Okamura, K., *et al.* Genome-wide multilocus imprinting disturbance analysis in Temple syndrome and Kagami-Ogata syndrome. *Genet. Med.* doi: 10.1038/gim.2016.123 (2016).
10. Al Ageeli, E., Drunat, S., Delanoë, C., Perrin, L., Baumann, C., Capri, Y. *et al.* Duplication of the 15q11-q13 region: clinical and genetic study of 30 new cases. *Eur. J. Med. Genet.* **57**, 5–14 (2014).
11. Bolton, P.F., Dennis, N.R., Browne, C.E., Thomas, N.S., Veltman, M.W., Thompson, R.J., *et al.* The phenotypic manifestations of interstitial duplications of proximal 15q with special reference to the autistic spectrum disorders. *Am. J. Med. Genet.* **105**, 675–685 (2001).
12. Browne, C.E., Dennis, N.R., Maher, E., Long, F.L., Nicholson, J.C., Sillibourne, J. *et al.* Inherited interstitial duplications of proximal 15q: genotype-phenotype correlations. *Am. J. Hum. Genet.* **61**, 1342–1352 (1997).
13. Bruce, S., Hannula-Jouppi, K., Puoskari, M., Fransson, I., Simola, K.O., Lipsanen-Nyman, M. *et al.* Submicroscopic genomic alterations in Silver-Russell syndrome and Silver-Russell-like patients. *J. Med. Genet.* **47**, 816–822 (2010).
14. Fokstuen, S., Kotzot, D. Chromosomal rearrangements in patients with clinical features of Silver-Russell syndrome. *Am. J. Med. Genet. A.* **164A**, 1595–1605 (2014).
15. Canton, A.P., Costa, S.S., Rodrigues, T.C., Bertola, D.R., Malaquias, A.C., Correa, F.A. *et al.* Genome-wide screening of copy number variants in children born small for

gestational age reveals several candidate genes involved in growth pathways. *Eur. J. Endocrinol.* **171**, 253–262 (2014).

TITLES AND FIGURE LEGENDS

Figure 1. The clinical findings in the patient.

The patient had dysmorphic facial features, including an upturned nose, down-slanting palpebral fissures, micrognathia, and relative macrocephaly (a), and severe clinodactyly of the bilateral fifth fingers (b). c, The growth chart of the patient. GnRH α , gonadotropin-releasing hormone analog.

Figure 2. Molecular studies of the family.

- a. Methylation analyses. Methylation indices obtained by pyrosequencing for nine DMRs. Red and black lines indicate methylation indices of the patient and the mother, respectively. Gray vertical bars indicate the reference ranges (minimum-maximum) in 50 control subjects.
- b. Oligoarray CGH analyses of the family. The duplication at chromosome 15q11.2-q13.1 was 5.7 Mbp in physical size (highlighted in *yellow*). Please note that a small deletion identified in upstream region of the 15q11.2-q13.1 duplication in the proband and the father (white arrows) has been reported as a normal copy number variant (<http://dgv.tcag.ca/dgv/app/home>).
- c. Fluorescence in situ hybridization analysis. A ~125-kb probe identifying a region encompassing *SNRPN* (red signals) was hybridized to lymphocyte metaphase spreads, together with a probe for *D15Z1* on 15p11.2 (blue signals, small arrows) and a probe for *PML* on 15q22 (green signals, arrow heads) utilized as internal controls.

Table 1 Clinical features of the present and reported cases with *H19*-DMR hypomethylation.

	Present case	SRS with <i>H19</i> -DMR hypomethylation ^c
Growth parameters		
Prenatal growth failure ^a	+	+
Birth weight (SD)	-5.0 SD	-3.50±0.85 (n = 42)
Birth length (SD)	-5.0 SD	-4.13±2.01 (n = 31)
Birth OFC (SD)	+1.0 SD	-0.54±1.22 (n = 29)
Postnatal growth failure ^a	+	+
present height (SD)	-5.0 SD	-3.58±1.65 (n = 35)
present weight (SD)	-4.0 SD	-3.15±1.16 (n = 32)
present OFC	-0.5 SD	-1.16±1.18 (n = 21)
SRS phenotype		
Relative macrocephaly at birth ^a	+	100.0%
Protruding forehead ^a	+	83.8%
Body asymmetry ^a	+	81.1%
Feeding difficulty ^{a, b}	+	47.1%
Trianglluar face	+	97.7%
Clinodactyly	+	78.4%
Brachydactyly	+	78.9%
Simian crease	-	15.4%
Irregular teeth	+	46.2%
ear anomalies ^b	+	40.0%
Muscular hypotonia ^b	+	53.1%
Speech delay ^b	-	25.8%
Developmental delay ^b	+	48.6%
Scoliosis/Kyphosis ^b	+	N.D.
15q duplication phenotype		
Mental retardation	+(IQ 67)	N.D.
Autism	-	N.D.
Learning disability	+	N.D.
Bhavioral disturbance	-	N.D.
Epilepsy	-	N.D.
Upturned nose	+	N.D.
Flattened nasal bridge	+	N.D.
High-arched palate	+	N.D.
Epicanthic fold	-	N.D.
Downslanting palpebral fissures	+	N.D.
Reduced skin pigmentation	-	N.D.

^a Key features in the Netchine–Harbison SRS clinical scoring system. ^b Manifestations overlapping with those of 15q duplication syndrome. ^c Frequencies of clinical features in Japanese patients with *H19*-DMR hypomethylation reported by Fuke et al. SRS, Silver Russel syndrome; IG-DMR, intergenic differentially methylated region; SD, standard deviation; OFC, occipitofrontal circumference; +, present; -, absent; N.D., not described.

Supplementary Table 1. Methylation indices (%) for CpG dinucleotides at disease-associated DMRs

DMR	CpG#	Proband	Mother	Control (n=50) Median (Min-Max)
<i>PLAGL1(ZAC1)</i> -DMR (Ch. 6q24.2)	1	50	48	47 (33-52)
	2	49	45	46 (34-51)
	3	48	48	48 (40-56)
	4	39	37	39 (31-47)
	5	40	46	50 (44-58)
	6	46	48	49 (41-55)
	7	56	50	53 (47-58)
<i>PEG1</i> -DMR (Ch. 7q32.2)	8	59	53	60 (56-70)
	9	58	53	59 (55-69)
	10	55	51	58 (52-68)
	11	60	57	61 (42-73)
	12	56	52	57 (47-66)
	13	60	53	60 (54-70)
<i>PEG10</i> -DMR (Ch. 7q21.3)	14	56	55	56 (50-59)
	15	46	51	55 (50-59)
	16	54	53	53 (48-59)
	17	55	52	54.5 (50-59)
	18	50	50	50 (45-55)
<i>HI9</i> -DMR (Ch. 11p15.5)	19	21	42	48 (37-60)
	20	21	44	50 (39-64)
	21	19	41	46 (36-57)
	22	18	41	45 (36-55)
	23	19	35	45.5 (37-55)
	24	21	41	47 (38-58)
	25	21	43	46.5 (38-54)
	26	18	36	42.5 (37-55)
<i>Kv</i> -DMR (Ch. 11p15.5)	27	51	53	58 (49-66)
	28	53	57	61 (52-68)
	29	46	51	48 (41-54)
	30	49	55	48 (42-55)
	31	56	59	67 (55-72)
	32	57	60	64 (55-71)
<i>IG</i> -DMR (Ch. 14q32.2)	33	62	55	58 (49-68)
	34	59	54	54 (40-62)
	35	71	66	68 (54-78)
	36	55	53	53.5 (43-64)
<i>MEG3</i> -DMR (Ch. 14q32.2)	37	52	50	52 (43-56)
	38	55	51	55 (52-65)
	39	50	50	37 (32-55)
	40	57	52	60 (44-74)
	41	45	45	36 (26-47)
<i>SNRPN</i> -DMR (Ch. 15q11.2)	42	64	39	55 (50-60)
	43	58	35	49 (44-54)
	44	59	37	51 (46-57)
	45	59	37	52 (47-57)
	46	72	49	63 (58-68)
<i>GNAS</i> A/B-DMR (Ch. 20q13.32)	47	45	43	41 (34-45)
	48	43	42	40 (33-45)
	49	45	44	43 (35-47)
	50	43	40	38 (32-42)
	51	43	41	40 (33-45)
	52	43	40	38 (31-42)
	53	44	42	40 (32-44)

The hypomethylated and hypermethylated CpG sites are highlighted with light and dark gray backgrounds, respectively.

Figure 1

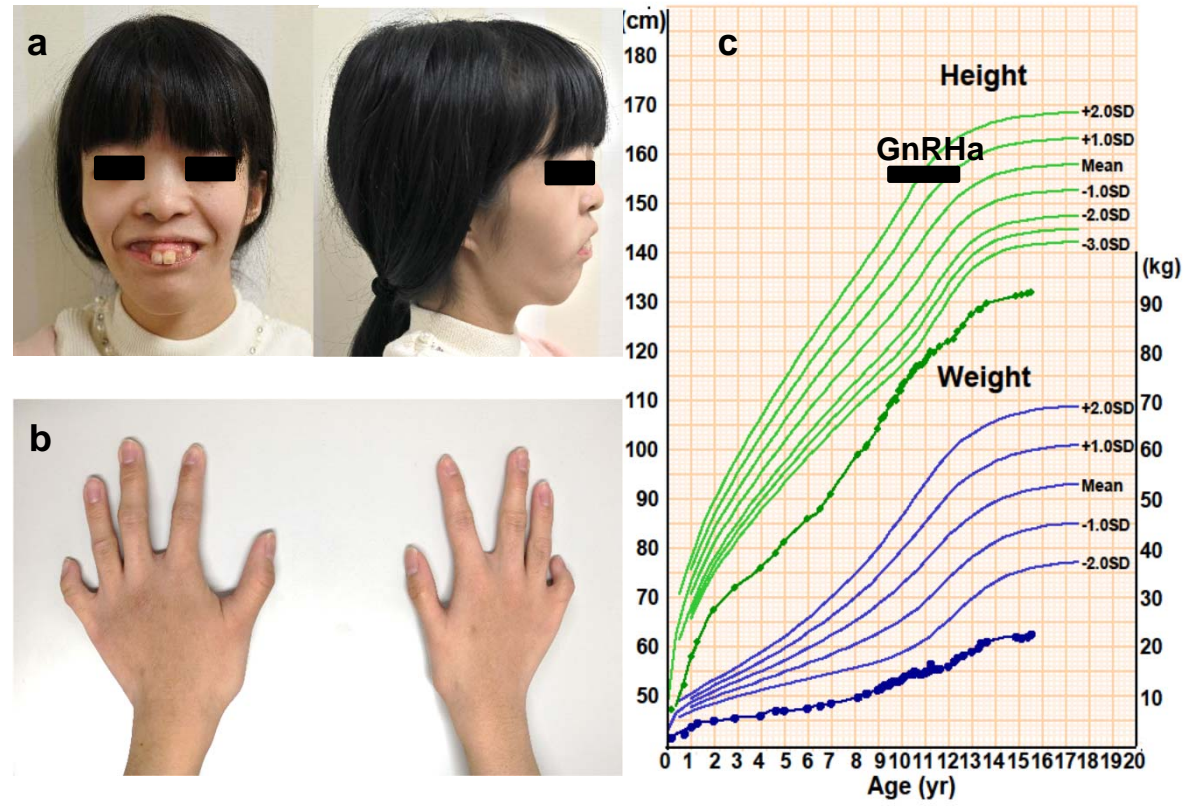


Figure 2

