

Case Report

Dynamic supination and hindfoot varus induced by chronic rupture of the tendons of both peroneus longus and brevis: a case report

Shohei MATSUBAYASHI, Ritsu TSUJIMOTO, Makoto OSAKI

Department of Orthopedic Surgery, Graduate School of Biomedical Sciences, Nagasaki University, Nagasaki, Japan.

Chronic rupture of both tendons of the peroneus longus and brevis is rare. Thus, it is difficult to diagnose and often overlooked. Since the peroneal tendons are the primary evertors of the foot and function as lateral ankle stabilizers, their rupture results in ankle sprain. We present a case with dynamic supination deformity during ambulation and hindfoot varus induced by chronic rupture of both tendons of the peroneus longus and brevis. We treated the patient with split anterior tibial tendon transfer and Dwyer calcaneal osteotomy. The dynamic supination deformity during ambulation and the hindfoot varus were improved, but a dorsal bunion remained, which was suggestive of residual dysfunction of the tendon of the peroneus longus.

ACTA MEDICA NAGASAKIENSIA 61: 81–85, 2017

Key words: chronic rupture of the peroneal tendons, ankle sprain, hindfoot varus, dynamic supination deformity during ambulation, split anterior tibialis transfer

Introduction

Chronic rupture of both tendons of the peroneus longus and brevis is rare¹⁾. Therefore, it is difficult to diagnose and often overlooked²⁾. Since the peroneal tendons are the primary evertors of the foot and function as lateral ankle stabilizers, their rupture causes ankle sprain in many cases^{3,4)}. It is important to confirm the alignment of the hindfoot in such cases, and dysfunction of the peroneal tendons should be considered when hindfoot varus is present⁵⁾.

Case report

The patient was a 13-year-old male who presented with inclination of the right ankle and repeated ankle sprains. The back of his right distal fibula had been cut by glass in an accident at 6 years old, and it was treated with myectomy and

skin suture by a physician. At 8 years old, he sprained his right ankle for the first time, and was treated with casting. He subsequently sprained his ankle once a month on average. At 9 years old, he was treated with casting after being diagnosed with a distal end fracture of the fibula, and he subsequently sprained his right ankle. He was treated with muscle strengthening exercises, which prevented further sprains. He initially visited our department at 10 years old.

On the first examination, there was no limitation in the range of motion of his bilateral ankle joints. The patient's left and right foot lengths were 21.5 and 20.8 cm, respectively, and his left and right calf circumferences were 30.0 and 27.5 cm, respectively. Manual muscle testing demonstrated that the only eversion muscle strength of the patient's right foot had decreased to level 3. The peroneal tendon was palpated at a site posterior to the lateral malleolus of the fibula, but not on the distal side. Right hindfoot varus was noted during standing. Manual inversion and eversion of the left hindfoot

Address correspondence: Shohei Matsubayashi, MD; Department of Orthopaedic Surgery, Graduate School of Biomedical Science, Nagasaki University, 1-7-1 Sakamoto Nagasaki City, Nagasaki 852-8501, Japan

Phone: +81-95-819-7321; Fax: +81-95-849-7325; E-mail: Shohei Matsubayashi: bayazarov@gmail.com

Received November 8, 2016; Accepted February 2, 2017

were possible, but the right hindfoot could not be everted.

On plain radiography, an avulsed bone fragment was seen at the distal end of the fibula. The right ankle joint was slightly unstable on the inversion stress test, but the bone fragment was stable (Fig. 1A). No instability was detected on the anterior drawer test. On the axial view, 20 degrees

varus of the right heel was observed (Fig. 1B). On MRI, the anterior talofibular (Fig. 2A) and calcaneofibular ligaments (Fig. 2B) were intact. The peroneal tendon was detected on the proximal side (Fig. 2C), but not the distal side. The avulsed bone fragment at the distal end of the fibula had fibrously fused (Fig. 2B).

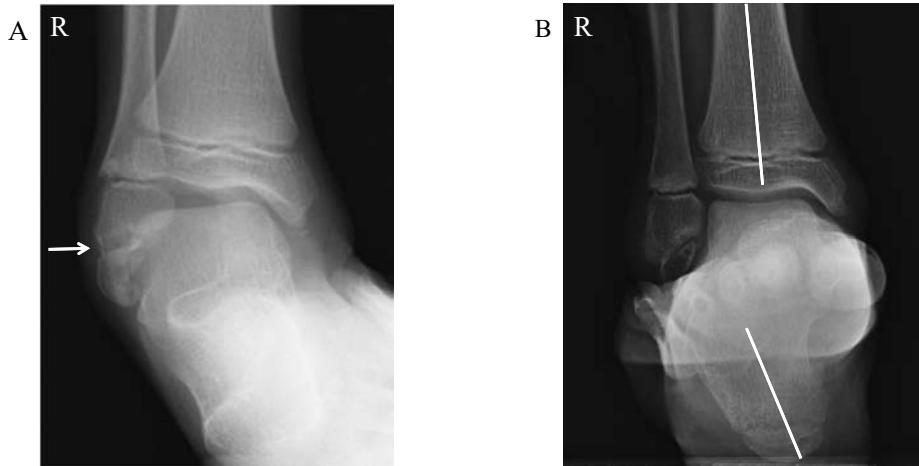


Figure 1A: Mild instability of the right ankle joint was noted on the inversion stress test. An avulsed bone fragment was present at the distal end of the fibula (arrow).
B: On an axial view, 20 degrees varus of the right heel was noted.

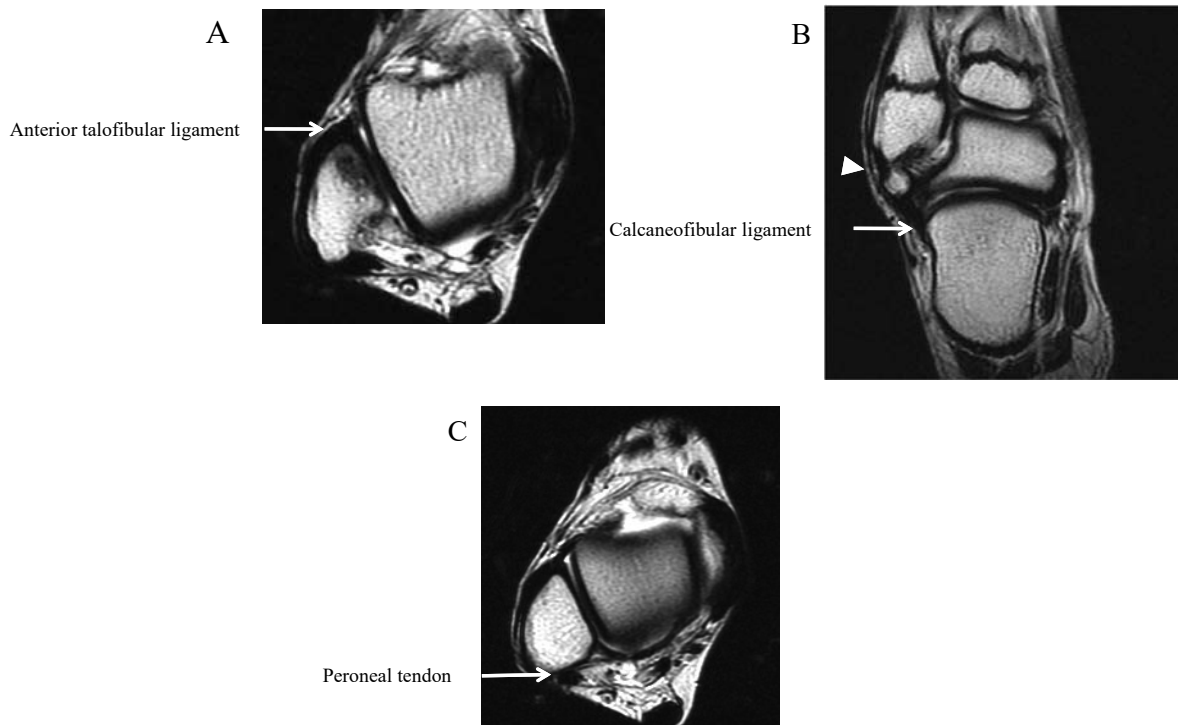


Figure 2A, B: On MRI, the anterior talofibular and calcaneofibular ligaments were retained (arrow). The avulsed bone fragment at the distal end of the fibula was fibrously fused (arrow head).
C: The peroneal tendon was confirmed on the proximal side, but unclear on the distal side.

Conservative appliance-based treatment was performed for 3 years in order to ensure that the patient retained the ability to perform hindfoot eversion, but his hindfoot varus gradually worsened from 20 to 26 degrees (Fig. 3A), and a dynamic supination deformity appeared during ambulation. The hindfoot varus and supination of the forefoot remained at the age of 13 years old.

The range of motion on plantar and dorsal flexion was not limited, and the right foot was supinated even under anesthesia (Fig. 3B). The lateral skin of the foot sole was thick, and a varus heel was noted. The dynamic supination deformity was treated with a split anterior tibial tendon transfer which two-thirds of the lateral anterior tibial tendon was transected from the base of the first metatarsal and transferred to the lateral cuneiform bone, and hindfoot varus was treated with Dwyer calcaneal osteotomy. The tendon of the peroneus longus was retained but adhered to the peroneal trochlea of the

calcaneus, being immobile. The tendon of the peroneus brevis was absent on the proximal side, and it was located distal to the peroneal trochlea and adhered to the trochlea together with the tendon of the peroneus longus. The regions of the tendons of the peroneus brevis and longus that were located distal to the peroneal trochlea exhibited fatty degeneration. Since the eversion of the calcaneus by Dwyer calcaneal osteotomy caused loosening of the tendon of the peroneus longus (Fig. 4A), the tendon was shortened by 2 cm around the peroneal trochlea and sutured to the distal tendons of the peroneus longus and brevis (Fig. 4B).

The dynamic supination deformity during ambulation had disappeared at one year after operation. The patient's hindfoot varus had improved, but a dorsal bunion remained (Fig. 5A). Improvement of the hindfoot varus (Fig. 5B) and the residual right dorsal bunion were also noted on radiography (Fig. 5C).

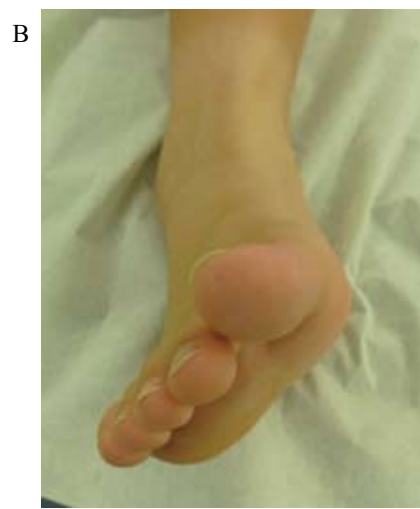
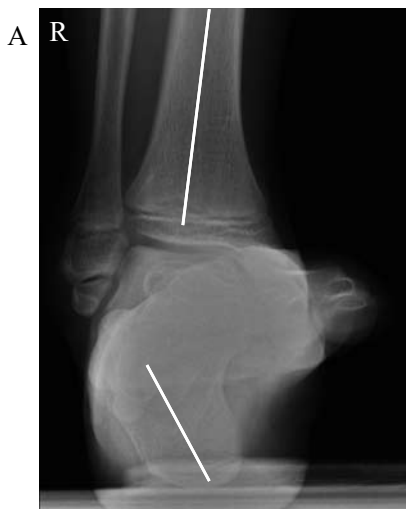
Figure 3A: The hindfoot varus had worsened to 26 degrees.
B: The right ankle was supinated even under anesthesia.

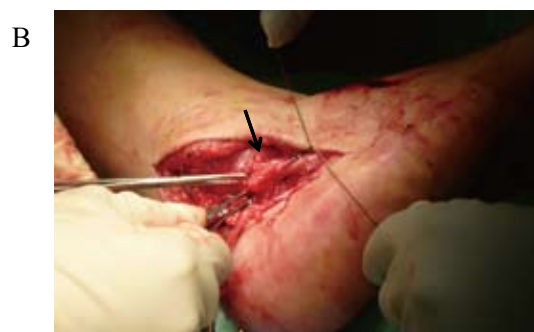
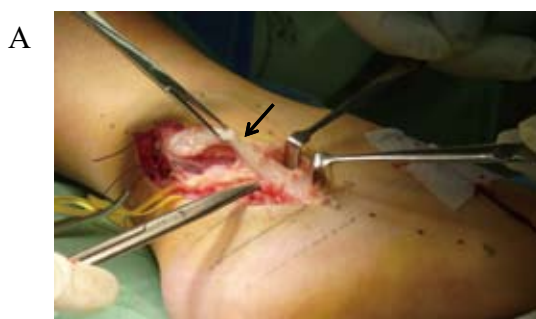
Figure 4A: The tendon of the peroneus longus was retained but adhered to the peroneal trochlea of the calcaneus, being immobile (arrow).
B: The tendon of the peroneus longus was shortened by 2 cm around the peroneal trochlea and was sutured to the distal tendons of the peroneus longus and brevis (arrow).

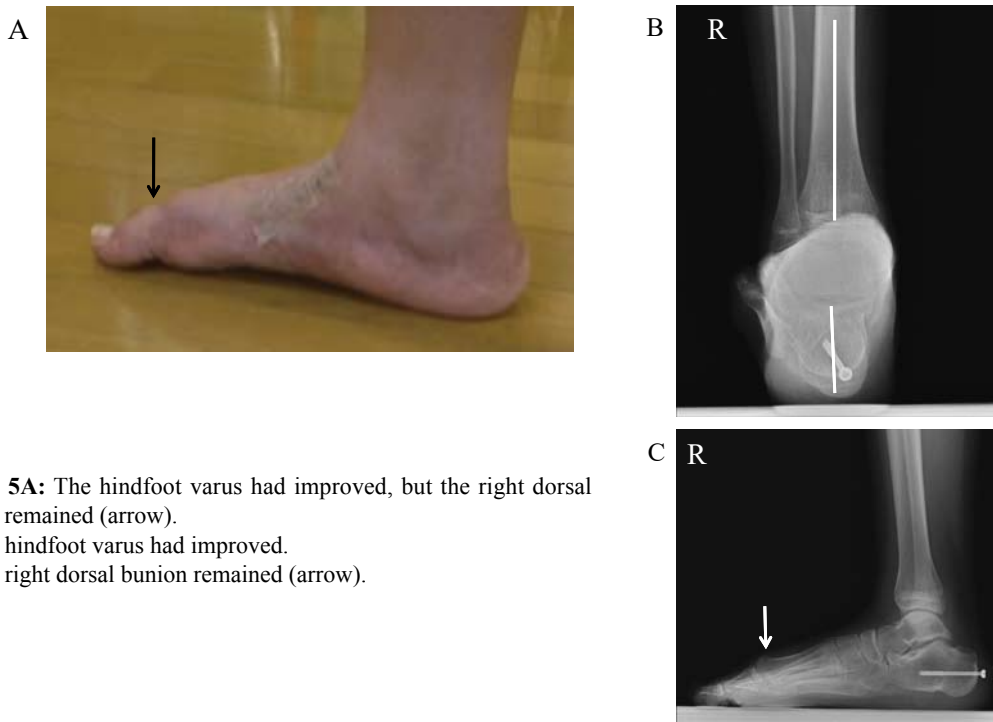


Figure 5A: The hindfoot varus had improved, but the right dorsal bunion remained (arrow).

B: The hindfoot varus had improved.

C: The right dorsal bunion remained (arrow).

Discussion

In the present case, the patient presented with repeated ankle sprains accompanied by hindfoot varus, and his eversion muscle strength had decreased. In addition, the distal tendons of the peroneus longus and brevis could not be identified on MRI. Based on these findings, chronic rupture of both tendons of the peroneus longus and brevis could be diagnosed.

Redfern and Myerson classified peroneal tendon injuries into 3 types¹⁾. In Type I, both tendons are grossly intact. In Type II, one tendon is torn, and the other is usable. In Type III, both tendons are torn or unusable. Our patient's injury was classified as Type III. Type III injuries require reconstruction of the peroneal tendons. Semitendinosus allografts of the tendons of the peroneus brevis and longus are sometimes used for such reconstructive procedures⁶⁾, but the use of allografts has not been approved in Japan. There are other reconstruction methods involving the use of the flexor digitorum longus and flexor hallucis longus^{7,8)}, but these approaches sacrifice other tendons, and only the tendon of the peroneus brevis can be reconstructed. It was unclear how much the residual tendons of the peroneus brevis and longus had retained their functions in the present case because a long time had passed since the injury. Thus, we abandoned the reconstruction of the peroneal tendons.

In a previous report, the anterior tibial tendon was trans-

ferred to the base of the second metatarsal to treat poliomyelitis-induced paralysis limited to the peroneal tendon⁹⁾. Our patient's ankle was supinated even at rest in our patient, which was suggestive overactivation of the anterior tibial tendon. Thus, we utilized this tendon. The split anterior tibial tendon transfer resolved supination at rest and dynamic supination deformity during ambulation. However, dorsal displacement of the first metatarsal remained. Therefore, total transfer might have been better than partial transfer.

When hindfoot varus is observed on reconstruction of the peroneal tendons, it has to be corrected simultaneously^{2,4)}. We performed Dwyer calcaneal osteotomy in the current case, which improved the patient's hindfoot alignment.

A dorsal bunion remained in the present case. A dorsal bunion is defined as a deformity of the foot caused by plantar flexion of the great toe and concomitant dorsiflexion of the first metatarsal¹⁰⁾. McKay reported 24 feet (22 patients) with dorsal bunions. The bunions were caused by either a weak or absent peroneus longus (18 feet) or by weakness of the triceps surae (16 feet). The peroneus longus acts as a plantar flexor of the ankle joint and the primary plantar flexor of the first metatarsal⁴⁾. Dysfunction of the tendon of the peroneus longus might have persisted in the present case. It was assumed that the dorsal bunion was already present before the operation, but it had been masked because the entire forefoot was supinated, and its presence became apparent after the forefoot supination was improved by the operation.

Conclusion

We treated a dynamic supination deformity during ambulation and hindfoot varus induced by chronic rupture of both tendons of the peroneus longus and brevis using a split anterior tibial tendon transfer and Dwyer calcaneal osteotomy, respectively.

The dynamic supination deformity during ambulation and the hindfoot varus were improved, but the dorsal bunion remained, which was suggestive of residual dysfunction of the tendon of the peroneus longus.

References

1. Redfern D, Myerson M. The management of concomitant tears of the peroneus longus and brevis tendons. *Foot Ankle Int* 25(10): 695-707, 2004
2. Brad D, Brain D. *OPERATIVE TECHNIQUES IN FOOT AND ANKLE SURGERY*. (Lippincott Williams & Wilkins, Philadelphia) pp 978-987, 2011
3. Abraham E, Stirnaman JE. Neglected rupture of the peroneal tendons causing recurrent sprains of the ankle. *J Bone Joint Am* 61(8):1247-1248, 1979
4. Philbin TM, Landis DS, Smith B. Peroneal tendon injuries. *J Am Acad Orthop Surg* 17(5):306-317, 2009
5. Manoli A 2nd, Graham B. The subtle cavus foot, "the underpronator". *Foot Ankle Int* 26(3):256-263, 2005
6. Pellegrini MJ, Adamas SB, Parekh SG. Reversal of peroneal tenodesis with allograft reconstruction of the peroneus brevis and longus: case report and surgical technique. *Foot Ankle Spec* 7(4):327-331, 2014
7. Borton DC, Lucas P, Jomha NM, Cross MJ, Slater K. Operative reconstruction after transverse rupture of the tendons of both peroneus longus and brevis. *J Bone Joint Br* 80(5):781-785, 1998
8. Wapner KL, Taras JS, Lin SS, Chao W. Staged reconstruction for chronic rupture of both peroneal tendons using hunter rod and flexor hallucis longus tendon transfer: a long-followup study. *Foot Ankle Int* 27(8):591-597, 2006
9. James CD. *Lovell and Winter Pediatric ORTHOPAEDICS*. 2nd ed. (Lippincott, Philadelphia) pp. 259-343, 1986
10. McKay DW. Dorsal bunions in children. *J Bone Joint Surg Am* 65(7): 975-980, 1983

