

[ CASE REPORT ]

## Peripheral Ulcerative Keratitis Associated with Granulomatosis with Polyangiitis Emerging Despite Cyclophosphamide, Successfully Treated with Rituximab

Yuya Fujita<sup>1</sup>, Shoichi Fukui<sup>1,2</sup>, Yushiro Endo<sup>1</sup>, Sosuke Tsuji<sup>1</sup>, Ayuko Takatani<sup>1</sup>, Toshimasa Shimizu<sup>1</sup>, Masataka Umeda<sup>1,3</sup>, Ayako Nishino<sup>1,4</sup>, Tomohiro Koga<sup>1,5</sup>, Shin-ya Kawashiri<sup>1,2</sup>, Naoki Iwamoto<sup>1</sup>, Kunihiro Ichinose<sup>1</sup>, Mami Tamai<sup>1</sup>, Hideki Nakamura<sup>1</sup>, Tomoki Origuchi<sup>1,6</sup>, Ryotaro Ueki<sup>7</sup>, Masafumi Uematsu<sup>7</sup>, Kaori Ishida<sup>8</sup>, Kuniko Abe<sup>8</sup> and Atsushi Kawakami<sup>1</sup>

### Abstract:

A 67-year-old Japanese man was diagnosed with granulomatosis with polyangiitis based on the presence of right maxillary sinusitis, proteinase 3 antineutrophil cytoplasmic antibody positivity, and right scleritis. A conjunctival biopsy specimen showed neutrophil-predominant infiltration around the vessels without granuloma. Because there was a risk of blindness, pulsed methylprednisolone and intravenous cyclophosphamide pulse therapy (IVCY) were started. However, it was ineffective, and peripheral ulcerative keratitis newly emerged. We promptly switched the treatment from IVCY to rituximab, and ophthalmologists performed amniotic membrane transplantation, which avoided blindness. The close and effective working relationship between physicians and ophthalmologists improved our patient's ocular prognosis.

**Key words:** ANCA-associated vasculitis, granulomatosis with polyangiitis, peripheral ulcerative keratitis, rituximab, scleritis, Wegener's granulomatosis

(Intern Med 57: 1783-1788, 2018)

(DOI: 10.2169/internalmedicine.0215-17)

### Introduction

Granulomatosis with polyangiitis (GPA) is a multisystem disorder characterized by necrotizing granulomatous inflammation and pauci-immune small-vessel vasculitis (1, 2). It is known that 50-60% of GPA patients have ocular involvement (3). Of the ocular involvement, scleritis, peripheral ulcerative keratitis (PUK), and orbital mass are common, and each can result in blindness (3). We present a characteristic case of GPA with ocular involvement that was refractory to

prednisolone and intravenous cyclophosphamide but for which rituximab was effective.

### Case Report

A 67-year-old Japanese man was admitted to our hospital complaining of ophthalmalgia and conjunctival hyperemia in his right eye and body weight loss. The ophthalmalgia and conjunctival hyperemia had emerged 15 months prior to this admission, and at that time, he was diagnosed with scleritis and treated with corticosteroid-containing eye drops and

<sup>1</sup>Department of Immunology and Rheumatology, Nagasaki University Graduate School of Biomedical Sciences, Japan, <sup>2</sup>Department of Community Medicine, Nagasaki University Graduate School of Biomedical Sciences, Japan, <sup>3</sup>Medical Education Development Center, Nagasaki University Hospital, Japan, <sup>4</sup>Center for Comprehensive Community Care Education Medicine, Nagasaki University Graduate School of Biomedical Sciences, Japan, <sup>5</sup>Center for Bioinformatics and Molecular Medicine, Nagasaki University Graduate School of Biomedical Sciences, Japan, <sup>6</sup>Department of Rehabilitation Sciences, Nagasaki University Graduate School of Biomedical Sciences, Japan, <sup>7</sup>Department of Ophthalmology and Visual Sciences, Nagasaki University Graduate School of Biomedical Sciences, Japan and <sup>8</sup>Department of Pathology, Nagasaki University Hospital, Japan

Received: September 13, 2017; Accepted: October 17, 2017; Advance Publication by J-STAGE: January 11, 2018

Correspondence to Dr. Shoichi Fukui, fukui-ngs@umin.ac.jp

tacrolimus-containing eye drops. His symptoms were not relieved. An ophthalmologist suspected that systemic disease might be present in addition to the scleritis and examined the patient in greater detail; proteinase 3 antineutrophil cytoplasmic antibody (PR3-ANCA) was revealed to be positive. A physician suspected scleritis associated with ANCA-associated vasculitis, and daily 30-mg prednisolone was thus initiated 12 months prior to this admission. The patient's symptoms improved temporarily, but his scleritis worsened with the tapering of prednisolone. He started taking daily 150-mg cyclosporine in addition to prednisolone at 11 months prior to this admission.

The weight loss began 11 months prior to this admission, amounting to a >10-kg reduction until this admission. He became aware of nasal congestion and was diagnosed with sinusitis three months prior to this admission. In addition, his right scleritis worsened, so he was admitted to our hospital. He had a long-standing history of hypertension, type 2 diabetes mellitus, and dyslipidemia. Five years earlier, he had undergone coronary artery bypass surgery for the treatment of a myocardial infarction. His eyes had not experienced any traumatic events. He did not have any family history of rheumatic diseases.

His physical examination on admission revealed the following: body temperature 36.8°C, blood pressure 107/63 mmHg, and pulse rate 71/min. Auscultation of the chest showed neither heart murmur nor crackles. Right-predominant bilateral conjunctival hyperemia was seen. There was no exophthalmos, saddle-nose deformity, or skin eruptions.

His laboratory test results were as follows: white blood cell (WBC) count 12,500/mL (neutrophils 67%, lymphocytes 22%, monocytes 10%, eosinophils 1%, and basophils 0%); hemoglobin 10.6 g/dL; platelets 41.8 /mL; C-reactive protein (CRP) 0.2 mg/dL (normal range <0.17 mg/dL); erythrocyte sedimentation rate (ESR) 85 mm/h (normal range 1-10 mm/h); and serum creatinine (Cr) 1.56 mg/dL (normal values <1.0 mg/dL). PR3-ANCA was elevated to 23 EU/mL (normal range: <12 EU/mL), but myeloperoxidase antineutrophil cytoplasmic antibody was negative. A urinalysis showed no hematuria and no casts.

On an ophthalmologic examination, his best-corrected visual acuity was counting fingers oculus dexter, 20/50 oculus sinister. Thinning of the sclera and a nodule with bleeding existed on the upper ear-side of his right eye, and the inflammation reached the periphery of the cornea (Fig. 1a-1, a-2). Optical coherence tomography showed macular edema in the patient's right eye (Fig. 2a). Fundoscopy showed white spots on his right retina. On a slit-lamp eye examination, no thinning of the cornea was observed (Fig. 3a). Computed tomography (CT) showed mucosal thickening at the patient's right maxillary sinus. Chest CT showed no notable findings, including no pulmonary nodules or interstitial lung disease. Magnetic resonance imaging of the head showed no hypertrophic pachymeningitis and no orbital masses. A kidney biopsy specimen showed no cres-

cent formation, arteritis, or fibrinoid necrosis. Mild mesangial expansions were seen, suggesting mild diabetic nephropathy.

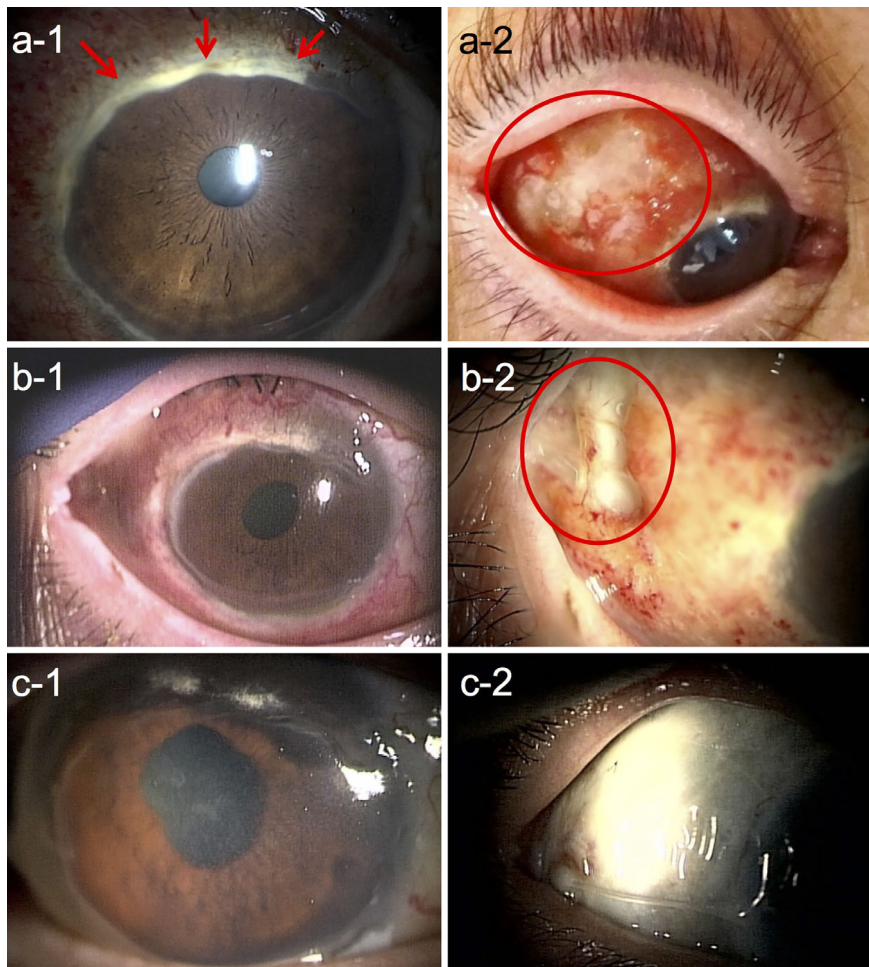
Because the patient had right maxillary sinusitis, positive PR3-ANCA, and right scleritis, we diagnosed GPA based on the Chapel Hill Consensus Conference criteria (4) and the European Medicines Agency algorithm (5) with exploratory surrogate markers for GPA. We concluded that the patient's chronic kidney disease was caused by diabetic nephropathy. We changed the cyclosporine to an increased dose of 60 mg/day oral prednisolone following pulsed methylprednisolone (1,000 mg/day for 3 consecutive days per week) twice and intravenous cyclophosphamide pulse therapy [IVCY; 900 mg (=15 mg/kg) per body once every 2 weeks] twice. As topical therapies, we continued corticosteroid-containing eye drops and tacrolimus-containing eye drops. An ophthalmologist administered intravitreal bevacizumab and performed a biopsy of the right conjunctiva. The right conjunctival biopsy specimen showed neutrophil-predominant infiltration of the blood vessels without granuloma (Fig. 4a, b). At two weeks after starting treatment, the patient was free from right ophthalmalgia, and his macular edema was improved (Fig. 2b), but conjunctival hyperemia in his right eye remained, and PUK newly emerged (Fig. 1b-1, 3b). In addition, the sclera became thinner (Fig. 1b-2), and opacity of the vitreous body emerged, which made it difficult to observe the fundus of the right eye. The risk of blindness of the right eye increased, becoming imminent because of the progression of the PUK.

We determined the IVCY to be ineffective and switched the treatment to rituximab (500 mg per body, 375 mg/m<sup>2</sup> per week for 4 weeks) (Fig. 5). In addition to rituximab, peritomy was performed for the PUK, and amniotic membrane transplantation was added to resolve the thinning of the sclera. Two weeks after the start of the rituximab regimen, the level of CD20-positive cells decreased from 23.7% to 0.1%. Four weeks after the start of the rituximab regimen, the patient's PUK was improved, and the hyperemia in his right eye had diminished (Fig. 1c-1, 1c-2, 3c). Although the opacity of the vitreous body was not improved and his best-corrected visual acuity was light perception oculus dexter, 20/200 oculus sinister, he narrowly avoided blindness.

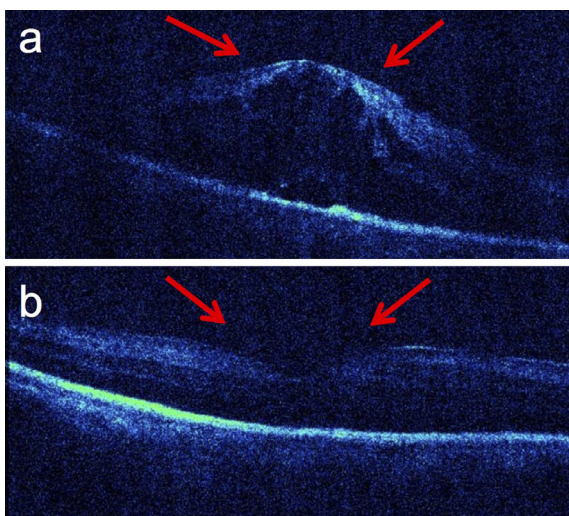
Because the level of CD20-positive cells had risen to 4.0% without worsening of the PUK or other symptoms eight months later, we added maintenance rituximab administered at 8-month intervals. Two years after the first administration of rituximab, the symptoms in the patient's eyes have never relapsed.

## Discussion

We herein report the case of a patient with GPA complicated with PUK and scleritis. The PUK emerged after the initiation of IVCY treatment and worsened rapidly. The appropriate judgement of the inefficacy of IVCY and the



**Figure 1.** Macroscopic findings of the patient's right eye (1: frontal view, 2: left gaze). On admission, a: inflammation spread near the periphery of the cornea (red arrows). Thinning of the sclera and a nodule with bleeding on the upper ear-side of the right eye were noted (red circle). After IVCY therapy and intravitreal bevacizumab, b: hyperemia remained, and the sclera became thinner (red circle). After rituximab therapy, peritomy, and amniotic membrane transplantation, c: hyperemia diminished, and ocular surface reconstruction progressed smoothly.

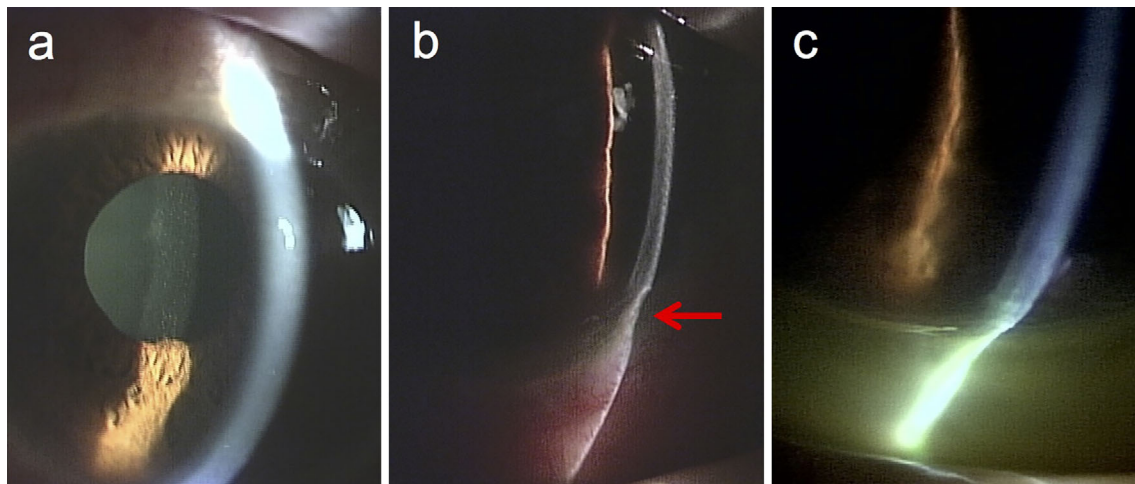


**Figure 2.** Optical coherence tomography findings. On admission, a: macular edema was seen in his right eye. After IVCY therapy and intravitreal bevacizumab, b: macular edema was improved (red arrows).

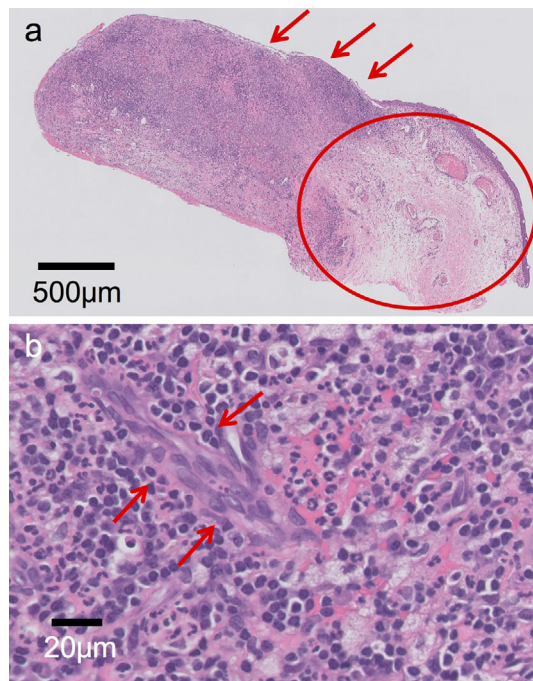
prompt switch from IVCY to rituximab led to the avoidance of blindness.

In ocular manifestations of ANCA-associated vasculitis, the frequency of scleritis is 75.0%, and that of PUK is 16.1% (6). Our patient had both scleritis and PUK without visceral organ involvement.

In general, treatment with a combination of a corticosteroid and cyclophosphamide results in remission for approximately 70-90% of GPA patients, and refractory patients are treated by rituximab (7), a monoclonal antibody directed against CD20, which leads to the depletion of peripheral B-lymphocytes (8). However, there are few prognostic factors to predict the effectiveness of treatment with a combination of a corticosteroid and cyclophosphamide for individual cases (9). Regarding GPA with ocular manifestations, rituximab has been reported to be effective for PUK or necrotizing scleritis with GPA (10-14). Because our patient was also refractory to corticosteroids and IVCY and because blindness was forthcoming, we promptly switched to rituximab. In refractory antibody-associated vasculitis (AAV) patients,



**Figure 3.** Slit-lamp eye examination findings. On admission, **a:** There was no thinning of the cornea. After IVCY therapy and intravitreal bevacizumab, **b:** Peripheral ulcerative keratitis (red arrow) newly emerged in the right eye. After rituximab therapy, peritomy, and amniotic membrane transplantation, **c:** peripheral ulcerative keratitis was improved.



**Figure 4.** Right conjunctival biopsy specimen. Low-power field, **a:** edema (red circle) and neutrophil-predominant inflammatory cell infiltration (red arrows). High-power field, **b:** neutrophil-predominant inflammatory cell infiltration around vascular endothelial cells (red arrows).

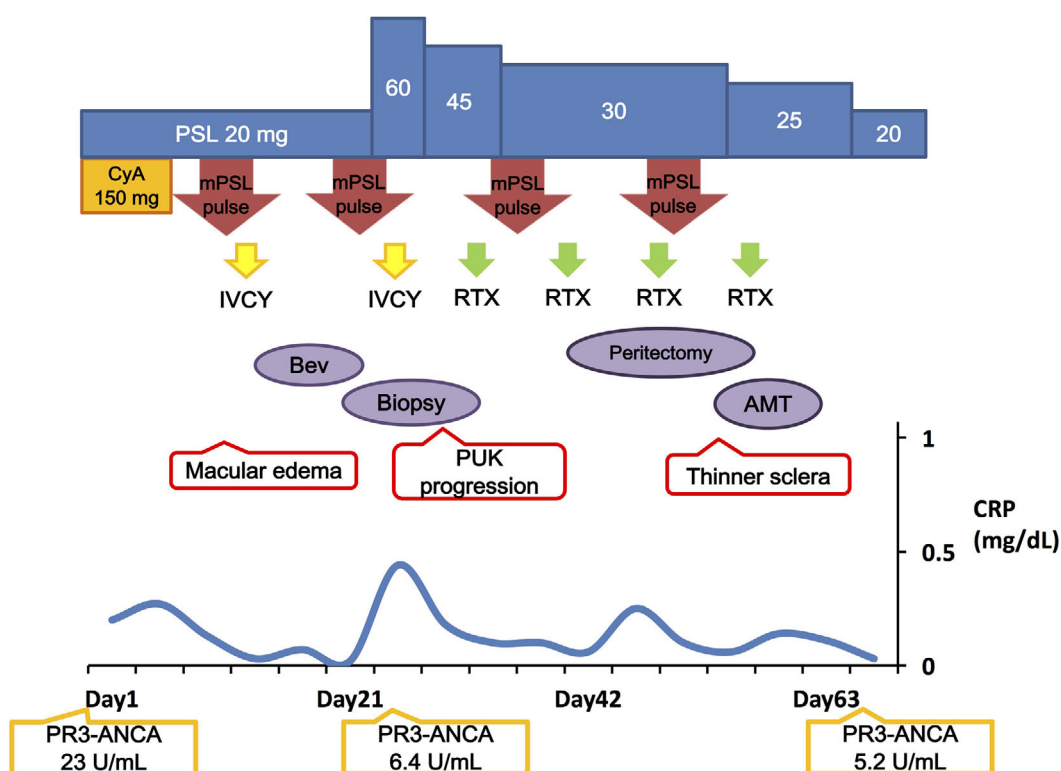
the median disease duration before starting rituximab was 72 months (15). In GPA patients with scleritis, the duration of systemic therapy prior to rituximab was 18-89 months (14). Given with these reports, switching to rituximab after performing IVCY twice within one month after the first session of IVCY therapy in our patient may have been too early. IVCY might take more than one month to show efficacy, and the duration for the evaluation of efficacy of IVCY might have been too short in the present case.

However, given that PUK was likely to cause blindness regardless of IVCY and mPSL pulse therapy, prompt switching to rituximab may have been justified. To our knowledge, there have been no reports in which IVCY was switched to rituximab within one month after the first round of IVCY therapy.

Histopathologically, both focal vasculitis (16) and granuloma (17) can cause scleritis and keratitis. Scleritis is thought to be a mixed lesion caused by both vasculitis and granuloma-related involvement (18). Rituximab was reported to be more effective for treating vasculitic manifestations (such as alveolar hemorrhage and renal disease) than granulomatous manifestations (such as orbital masses) (19). Vasculitic manifestations are related to ANCA originating from B cells, whereas granulomatous manifestations are related to CD4-positive T cells (18). This may influence the differences in the effects of rituximab between vasculitic and granulomatous manifestations. In our patient, the conjunctival biopsy specimen showed vasculitic lesions but no granulomas. This may be one of the reasons why rituximab was so effective in our patient. Following this hypothesis, as rituximab may be an ideal first choice for ophthalmic GPA with vasculitic manifestations, it is necessary to clarify the relationships between the efficiency of rituximab for GPA and the clinical and pathological aspects.

Intravitreal bevacizumab has demonstrated efficacy for macular edema (20). Macular edema in our patient was improved by intravitreal bevacizumab; however, PUK and opacity of the vitreous body of our patient emerged after intravitreal bevacizumab. It is relatively unlikely that intravitreal bevacizumab caused PUK and opacity of the vitreous body because PUK and opacity of the vitreous body have rarely been reported as adverse events of intravitreal bevacizumab (21).

Surgical intervention in cooperation with ophthalmologists was essential for avoiding blindness in the present case. Am-



**Figure 5.** The clinical course of the patient, a 67-year-old man. AMT: amniotic membrane transplantation, Bev: intravitreal bevacizumab, Biopsy: right conjunctival biopsy, CRP: C-reactive protein, CyA: cyclosporine, IVCY: intravenous cyclophosphamide pulse therapy, mPSL pulse: pulsed methylprednisolone, PR3-ANCA: proteinase 3 antineutrophil cytoplasmic antibody, PSL: prednisolone, PUK: peripheral ulcerative keratitis, RTX: rituximab

notic membrane transplantation in particular is known to be effective for ocular surface reconstruction (22). Amniotic membrane transplantation was also reported to be beneficial for treating severe PUK (23). Physicians' acknowledgement of ophthalmological strategies is needed for a close and effective working relationship between physicians and ophthalmologists.

### Conclusion

Accepting the ineffectiveness of IVCY and promptly switching from cyclophosphamide to rituximab helped avoid blindness in a patient with ocular involvements complicated with GPA. The close cooperation of physicians and ophthalmologists may improve the ocular prognosis of GPA patients with ocular involvement.

The authors state that they have no Conflict of Interest (COI).

### References

- Falk RJ, Gross WL, Guillemin L, et al. Granulomatosis with polyangiitis (Wegener's): an alternative name for Wegener's granulomatosis. *Arthritis Rheum* **63**: 863-864, 2011.
- Woywodt A, Haubitz M, Haller H, Matteson EL. Wegener's granulomatosis. *Lancet* **367**: 1362-1366, 2006.
- Pakrou N, Selva D, Leibovitch I. Wegener's granulomatosis: ophthalmic manifestations and management. *Semin Arthritis Rheum* **35**: 284-292, 2006.
- Jennette JC, Falk RJ, Bacon PA, et al. 2012 revised International Chapel Hill Consensus Conference Nomenclature of Vasculitides. *Arthritis Rheum* **65**: 1-11, 2013.
- Watts R, Lane S, Hanslik T, et al. Development and validation of a consensus methodology for the classification of the ANCA-associated vasculitides and polyarteritis nodosa for epidemiological studies. *Ann Rheum Dis* **66**: 222-227, 2007.
- Watkins AS, Kempen JH, Choi D, et al. Ocular disease in patients with ANCA-positive vasculitis. *J Ocul Biol Dis Infor* **3**: 12-19, 2010.
- Keogh KA, Ytterberg SR, Fervenza FC, Carlson KA, Schroeder DR, Specks U. Rituximab for refractory Wegener's granulomatosis: report of a prospective, open-label pilot trial. *Am J Respir Crit Care Med* **173**: 180-187, 2006.
- Specks U, Fervenza FC, McDonald TJ, Hogan MC. Response of Wegener's granulomatosis to anti-CD20 chimeric monoclonal antibody therapy. *Arthritis Rheum* **44**: 2836-2840, 2001.
- Reinhold-Keller E, Kekow J, Schnabel A, et al. Influence of disease manifestation and antineutrophil cytoplasmic antibody titer on the response to pulse cyclophosphamide therapy in patients with Wegener's granulomatosis. *Arthritis Rheum* **37**: 919-924, 1994.
- Onal S, Kazokoglu H, Koç A, Yavuz S. Rituximab for remission induction in a patient with relapsing necrotizing scleritis associated with limited Wegener's granulomatosis. *Ocul Immunol Inflamm* **16**: 230-232, 2008.
- Taylor SR, Salama AD, Joshi L, Pusey CD, Lightman SL. Rituximab is effective in the treatment of refractory ophthalmic Wegener's granulomatosis. *Arthritis Rheum* **60**: 1540-1547, 2009.

12. Huerva V, Sanchez MC, Traveset A, Jurjo C, Ruiz A. Rituximab for peripheral ulcerative keratitis with Wegener granulomatosis. *Cornea* **29**: 708-710, 2010.
13. Lower EE, Baughman RP, Kaufman AH. Rituximab for refractory granulomatous eye disease. *Clin Ophthalmol* **6**: 1613-1618, 2012.
14. Recillas-Gispert C, Serna-Ojeda JC, Flores-Suárez LF. Rituximab in the treatment of refractory scleritis in patients with granulomatosis with polyangiitis (Wegener's). *Graefe's Arch Clin Exp Ophthalmol* **253**: 2279-2284, 2015.
15. Jones RB, Ferraro AJ, Chaudhry AN, et al. A multicenter survey of rituximab therapy for refractory antineutrophil cytoplasmic antibody-associated vasculitis. *Arthritis Rheum* **60**: 2156-2168, 2009.
16. Charles SJ, Meyer PA, Watson PG. Diagnosis and management of systemic Wegener's granulomatosis presenting with anterior ocular inflammatory disease. *Br J Ophthalmol* **75**: 201-207, 1991.
17. Ahmed M, Niffenegger JH, Jakobiec FA, et al. Diagnosis of limited ophthalmic Wegener granulomatosis: distinctive pathologic features with ANCA test confirmation. *Int Ophthalmol* **28**: 35-46, 2008.
18. Aouba A, Pagnoux C, Bienvenu B, Mahr A, Guillevin L. Analysis of Wegener's granulomatosis responses to rituximab: current evidence and therapeutic prospects. *Clin Rev Allergy Immunol* **34**: 65-73, 2008.
19. Holle JU, Dubrau C, Herlyn K, et al. Rituximab for refractory granulomatosis with polyangiitis (Wegener's granulomatosis): comparison of efficacy in granulomatous versus vasculitic manifestations. *Ann Rheum Dis* **71**: 327-333, 2012.
20. Rajendram R, Fraser-Bell S, Kaines A, et al. A 2-year prospective randomized controlled trial of intravitreal bevacizumab or laser therapy (BOLT) in the management of diabetic macular edema: 24-month data: report 3. *Arch Ophthalmol* **130**: 972-979, 2012.
21. Fung AE, Rosenfeld PJ, Reichel E. The International Intravitreal Bevacizumab Safety Survey: using the internet to assess drug safety worldwide. *Br J Ophthalmol* **90**: 1344-1349, 2006.
22. Tseng SC. Amniotic membrane transplantation for ocular surface reconstruction. *Biosci Rep* **21**: 481-489, 2001.
23. Jia Y, Gao H, Li S, Shi W. Combined anterior chamber washout, amniotic membrane transplantation, and topical use of corticosteroids for severe peripheral ulcerative keratitis. *Cornea* **33**: 559-564, 2014.

The Internal Medicine is an Open Access article distributed under the Creative Commons Attribution-NonCommercial-NoDerivatives 4.0 International License. To view the details of this license, please visit (<https://creativecommons.org/licenses/by-nc-nd/4.0/>).