



Case series

Liver resection for metastases of tracheal adenoid cystic carcinoma: Report of two cases



Shintaro Hashimoto^{a,*}, Yorihiisa Sumida^a, Shuichi Tobinaga^a, Hideo Wada^a, Kouki Wakata^a, Takashi Nonaka^a, Masaki Kunizaki^a, Shigekazu Hidaka^a, Naoe Kinoshita^b, Terumitsu Sawai^c, Takeshi Nagayasu^a

^a Department of Surgery, Division of Surgical Oncology, Nagasaki University Graduate School of Biomedical Sciences, Japan

^b Department of Pathology, Division of Surgical Oncology, Nagasaki University Graduate School of Biomedical Sciences, Japan

^c Cardiopulmonary Rehabilitation Science, Division of Surgical Oncology, Nagasaki University Graduate School of Biomedical Sciences, Japan

ARTICLE INFO

Article history:

Received 22 January 2018

Accepted 1 May 2018

Available online 16 May 2018

Keywords:

Adenoid cystic carcinoma

Hepatic metastases

Tracheal tumour

ABSTRACT

INTRODUCTION: Tracheal adenoid cystic carcinoma (ACC) is rare and accounts for <1% of all lung cancers. Although ACC is classified as a low-grade tumor, metastases are frequently identified in the late period. Extrapulmonary metastases are rare, and their resection has rarely been reported.

PRESENTATION OF CASE: Case 1: A 77-year-old man underwent tracheal resection for ACC with postoperative radiation (60 Gy) 14 years before (at the age of 63). He underwent two subsequent pulmonary resections for metastases. Fourteen years after the first operation, he underwent extended right posterior segmentectomy with resection of segment IV and radiofrequency ablation for metastases of ACC to the liver. He was diagnosed with metastases to the kidney with peritoneal dissemination 4 years after the liver resection and died of pneumonia 2 years later. Case 2: A 53-year-old woman underwent a two-stage operation involving tracheal resection for ACC and partial resection of liver segments II and V for metastases of ACC to the liver. The tracheal margin was histopathologically positive. Postoperative radiation was performed, and she was tumor-free for 10 months after the liver resection.

DISCUSSION: Complete resection of tracheal ACC provides better survival. Radiotherapy is also recommended. However, the optimal treatment for metastases of ACC is unclear, especially because liver resection for metastases of tracheal ACC is rarely reported. Our two cases of metastases of tracheal ACC were surgically managed with good outcomes.

CONCLUSION: Liver resection for metastases of tracheal ACC may contribute to long survival.

© 2018 The Authors. Published by Elsevier Ltd on behalf of IJS Publishing Group Ltd. This is an open access article under the CC BY-NC-ND license (<http://creativecommons.org/licenses/by-nc-nd/4.0/>).

1. Introduction

Tracheal adenoid cystic carcinoma (ACC) is rare and accounts for <1% of all lung cancers [1]. Although ACC is characterized by slow growth and classified as a low-grade tumor [2], metastasis or local recurrence is frequently identified in the late period [3]. Maziak

et al. [3] reported that 45% of patients with tracheal ACC were diagnosed with metastases during follow-up in their study, and the mean period from the first treatment to diagnosis was 100 months. Sites of metastasis of tracheal ACC include the lung, liver, bone, brain, kidney, heart, skin, and abdomen. The optimal treatment for metastases of ACC has not been established.

Reports of hepatectomy for liver metastases of ACC, especially tracheal ACC, are rare [4–7]. We herein describe two rare cases of liver metastases of tracheal ACC that were managed surgically. It is reported in line with the PROCESS criteria [8].

2. Presentation of case

2.1. Case 1

A 77-year-old man underwent tracheal resection and reconstruction for tracheal ACC 14 years before (at the age of 63).

* Corresponding author. Present address: Division of Surgical Oncology, Department of Surgery, Nagasaki University Graduate School of Biomedical Sciences, 1-7-1 Sakamoto, Nagasaki 852-8501, Japan. Tel.: +0958197304.

E-mail addresses: shintahashimoto-ncd@umin.ac.jp (S. Hashimoto), y-sumida@nagasaki-u.ac.jp (Y. Sumida), sh.toby577@gmail.com (S. Tobinaga), gooddream44@gmail.com (H. Wada), kou-waka@hotmail.co.jp (K. Wakata), tnonaka@nagasaki-mc.com (T. Nonaka), kuniskasaki2002@yahoo.co.jp (M. Kunizaki), hidaka-s@nagasaki-u.ac.jp (S. Hidaka), daimonji@nagasaki-u.ac.jp (N. Kinoshita), sawai@nagasaki-u.ac.jp (T. Sawai), nagayasu@nagasaki-u.ac.jp (T. Nagayasu).

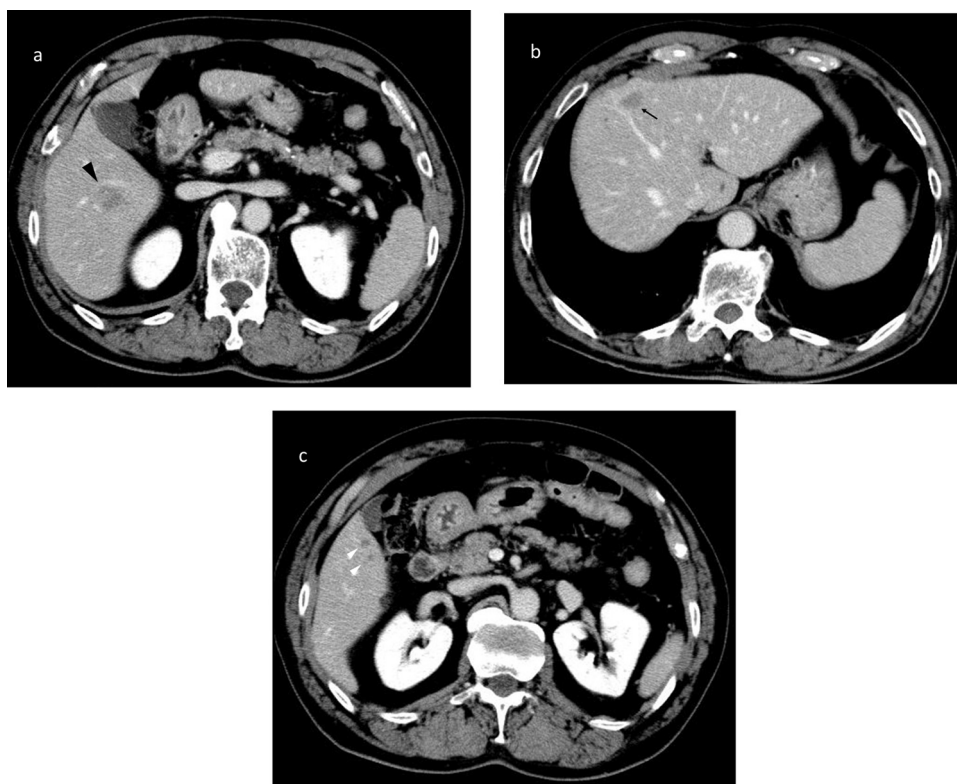


Fig. 1. Abdominal CT showed (a) a peripherally enhanced 3.5-cm mass in liver segments V/VI (black arrowhead) and (b) a peripherally enhanced 1.5-cm mass in segment IV (arrow). (c) CT also showed unenhanced masses in segments I, IV, V, and VII (white arrowhead).

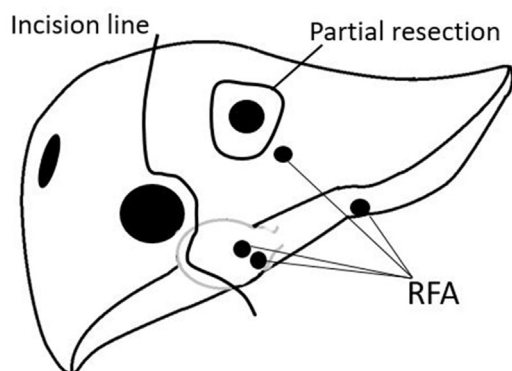


Fig. 2. The patient underwent extended right posterior segmentectomy with resection of segment IV and radiofrequency ablation for the lesions in segments I, IV, V, and VII.

Histopathologically, the margin was negative and no lymph node metastasis was found. Postoperative radiation therapy (60 Gy) was performed. He was diagnosed with solitary pulmonary metastases and underwent pulmonary partial resection 6 and 8 years after the original tracheal resection and reconstruction. Abdominal computed tomography (CT) showed 3.5- and 1.5-cm masses with peripheral enhancement in liver segments V/VI and IV, respectively (Fig. 1a-c). CT also showed unenhanced masses in segments I, IV, V, and VII. The patient's Eastern Cooperative Oncology Group (ECOG) performance status was 1. The result of an indocyanine green test was 12.1%. The laboratory data showed no evidence of organ disorder, including liver dysfunction. CT showed no other metastases or local recurrence. The patient was diagnosed with multiple liver metastases and underwent extended right posterior segmentectomy with resection of segment IV and radiofrequency ablation for the lesions in segments I, IV, V, and VII (Fig. 2). He was observed and

diagnosed with metastases to the bilateral kidney with peritoneal dissemination 3 years 8 months after the liver resection. Because of his poor activities of daily living and high age, conservative therapy was performed. He died of pneumonia 6 years 6 months after the liver resection (21 years after the first operation).

2.2. Case 2

A 53-year-old woman presented with complaints of wheezing. Chest CT revealed a tumor on the left posterior side of the upper trachea. Bronchoscopy showed a hypervascular tumor occupying the tracheal airway (Fig. 3). Bronchoscopic examination revealed a tracheal ACC. Abdominal CT revealed 2.5- and 1.0-cm masses in liver segments V and II, respectively. Dynamic magnetic resonance imaging of the liver showed 25- and 8-mm masses with peripheral enhancement in segments V (Fig. 4a) and II (Fig. 4b), respectively. The patient was diagnosed with metastases of tracheal ACC, and a two-stage operation was planned. First, she underwent tracheal resection, and the left thyroid and left recurrent nerve were resected in combination because of the neoplastic invasion. Histopathologically, the tracheal ACC was found to have invaded the thyroid, and the margin was diagnosed as positive due to preservation of the larynx. No lymph node metastasis was found. Postoperative radiation therapy (60 Gy) was performed. Two months after the first operation, a liver operation was planned. The patient's ECOG performance status was 1. The result of an indocyanine green test was 3.0%. The laboratory data showed no evidence of organ disorder, including liver dysfunction. She underwent laparoscopic partial hepatectomy of segments II and V. Histopathologically, the tumor showed a cribriform pattern and the specimens were diagnosed as metastases of ACC (Fig. 5). She remained tumor-free for 1 year after the liver resection (1 year 2 months after the first operation).

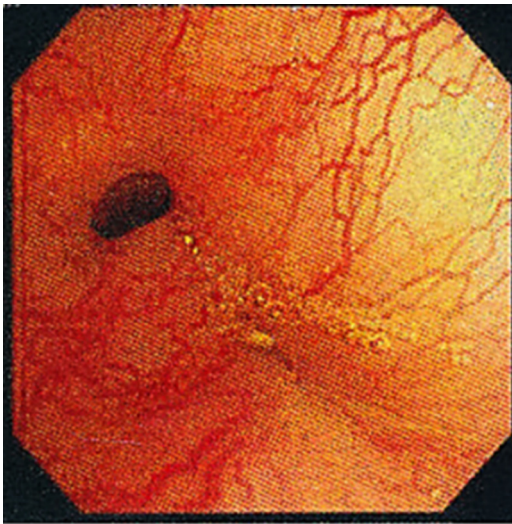


Fig. 3. Bronchoscopy showed a hypervascular tumor occupying the airway of the trachea.

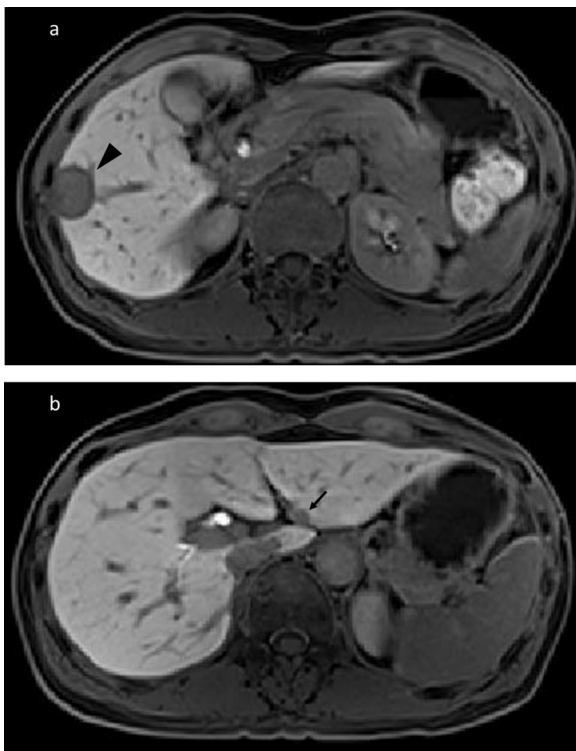


Fig. 4. Dynamic magnetic resonance imaging of the liver showed (a) a peripherally enhanced 25-mm mass in segment V (black arrowhead) and (b) a peripherally enhanced 8-mm mass in segment II (arrow).

3. Discussion

Tracheal ACC and squamous cell carcinoma together account for two-thirds of primary neoplasms of the airway [1]. Tracheal ACC characteristically progresses slowly, and it may metastasize and recur locally in the late phase [3]. Although the rate of complete resection is relatively low because of the infiltrative and invasive features of ACC, complete resection improves survival [1–3,9].

The effectiveness of postoperative radiation therapy for patients with incomplete resection of ACC has been reported, and some patients have survived for the long term with primary radiotherapy. The use of chemotherapy for unresectable tracheal ACC has

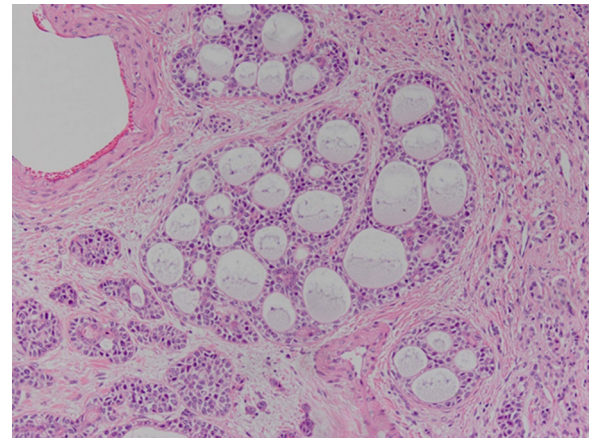


Fig. 5. Pathology of the liver metastatic specimen. The tumor showed a cribriform pattern identical to that of the primary tracheal tumor (hematoxylin and eosin stain, $\times 100$).

also been described in a few case reports [10,11]; however, there is no evidence that chemotherapy is useful.

In one study, metastases were identified in 45% of patients during follow-up and were diagnosed at a mean of 100 ± 79 months after initial therapy. The metastatic sites included the lung, liver, bone, brain, kidney, heart, skin, and abdomen [3]. Although some case reports of pulmonary resection for metastases of ACC have been published, liver resection for metastases of ACC [6], especially tracheal ACC, is rare. To the best of our knowledge, only one other case report has been published [7].

Park et al. [7] reported a case of hepatectomy for metastases 3 years after resection of tracheal ACC. The patient was followed up without progression or recurrence for >24 months. The authors discussed the validity of resection of metastases in patients presenting with no or few symptoms, suggesting that resection can be considered because of the relentless disease course and poor long-term outcome. The survival rate of patients with ACC after the primary resection is 79% at 5 years and 51% at 10 years [3]. In previous studies, 20%–47% of patients with tracheal ACC died of hematogenous metastases and 32%–37% died of local recurrence [1,3]. Surgical treatment for metastases of tracheal ACC can be considered if the primary region is controlled and all metastases can be treated by resection or another technique, such as radiofrequency ablation.

4. Conclusion

Tracheal ACC progresses slowly but metastasizes in the late phase. Surgical treatment for metastases of tracheal ACC can be considered if control of the primary region, resectability, acceptable organ function, and a good performance status are ensured. Long-term follow-up and management are necessary for early detection and treatment of metastases and local recurrence.

Conflicts of interest

None.

Funding

This research did not receive any specific grant from funding agencies in the public, commercial, or not-for-profit sectors.

Ethical approval

The report of cases was approved by the ethical committee of the Nagasaki University Hospital 16th April, 2018 and the admission number is 18041610.

Consent

Written consent to publish this case report was obtained from all patients.

Author contribution

Shintaro Hashimoto, Yori-hisa Sumida, and Shuichi Tobinaga were responsible for the study concept. Hideo Wada, Kouki Wakata, Takashi Nonaka, Masaki Kunizaki, and Shigekazu Hidaka collaborated in the patient's medical care. Terumitsu Sawai and Takeshi Nagayasu reviewed the manuscript. All authors approved the final article.

Registration of research studies

Researchregistry3603.

Guarantor

Yori-hisa Sumida.

References

- [1] F. Chen, M. Huang, Y. Xu, T. Li, K. Xie, L. Zhang, et al., Primary tracheal adenoid cystic carcinoma: adjuvant treatment outcome, *Int. J. Clin. Oncol.* 20 (4) (2015) 686–692.
- [2] H. Spencer, *Pathology of the Lung*, 4th ed., Pergamon Press, Oxford, 1985.
- [3] D.E. Maziak, T.R.J. Todd, S.H. Keshavjee, T.L. Winton, P.V. Nostrand, F.G. Pearson, Adenoid cystic carcinoma of the airway: thirty-two-year experience, *J. Cardiothorac. Surg.* 112 (6) (1996) 1522–1532.
- [4] S.S. Qureshi, M.S. Nadkarni, S.V. Shrikhande, S. Desai, K. Deodhar, M. Ramadwar, et al., Hepatic resection for metastasis from adenoid cystic carcinoma of parotid gland, *Indian J. Gastroenterol.* 24 (1) (2005) 29–30.
- [5] B.A. Zeidan, M.A. Hilal, M. Al-Gholmy, H. EL-Mahallawi, N.W. Pearce, J.N. Primrose, Adenoid cystic carcinoma of the lacrimal gland metastasising to the liver: report of a case, *World J. Surg. Oncol.* 4 (1) (2006) 66.
- [6] P.A. Sali, K.S. Yadav, K. Bushan, V. Rajpurohit, P.P. Varty, S. Sharma, A rare case of lacrimal adenoid cystic carcinoma with large hepatic and multiple pulmonary metastases with successful surgical treatment, *Int. J. Surg. Case Rep.* 20 (2016) 151–154.
- [7] I. Park, S.N. Lim, D.H. Yoon, H. Park, B. Sun, P.H. Lee, et al., Metastasectomy for hepatic metastases from adenoid cystic carcinoma of the trachea, *Gut Liver* 3 (2) (2009) 127.
- [8] R.A. Agha, A.J. Fowler, S. Rammohan, I. Barai, Orgill DP and the PROCESS group. The PROCESS statement: preferred reporting of case series in surgery, *Int. J. Surg.* 36 (Pt A) (2016) 319–323.
- [9] J. Honings, H.A. Gaissert, A.C. Weinberg, E.J. Mark, C.D. Wright, J.C. Wain, et al., Prognostic value of pathologic characteristics and resection margins in tracheal adenoid cystic carcinoma, *Eur J. Cardiothorac. Surg.* 37 (6) (2010) 1438–1444.
- [10] A.M. Allen, M.S. Rabin, J.J. Reilly, S.J. Mentzer, Unresectable adenoid cystic carcinoma of the trachea treated with chemoradiation, *J. Clin. Oncol.* 25 (34) (2007) 5521–5523.
- [11] M. Sasiya, N. Funa, M. Kamata, K. Furutani, A. Matsumoto, T. Kodaira, Unresectable adenoid cystic carcinoma of the trachea treated with chemoradiotherapy, *Clin. Oncol. (R. Coll. Radiol.)* 12 (4) (2000) 272.

Open Access

This article is published Open Access at [sciencedirect.com](https://www.sciencedirect.com). It is distributed under the [IJSCR Supplemental terms and conditions](#), which permits unrestricted non commercial use, distribution, and reproduction in any medium, provided the original authors and source are credited.