

Vitreomacular Interface: A case Series of Adhesion and Traction

Jeffery T. Curry,
OD, FAAO, ABO Dipl.

Lake City VAMC
Optometry Clinic,
North Florida/ South
Georgia Veterans Health
Administration

Michael Wingard,
OD, FAAO

McAllen, VA Outpatient Clinic,
Valley Coastal Bend Veteran
Health Administration

Abstract

The vitreomacular interface has historically been difficult to evaluate clinically. However, with the advent of optical coherence tomography (OCT), pathology at this interface is becoming easier to diagnose and monitor. Vitreomacular interface attachment can range from adhesions without foveal architectural changes, such as in vitreomacular adhesion (VMA), to tractions leading to architectural changes, such as in vitreomacular traction (VMT). Many of these cases can be observed and managed by optometry without consulting a retina specialist. This paper describes three cases of vitreomacular pathology, with a review of the grading system, presentations that have been shown to be associated with a higher incidence of spontaneous release, and treatment options.

KEYWORDS:

Optical coherence tomography, Vitreomacular adhesion, Vitreomacular traction, Epiretinal membrane, Macular hole, Retina

INTRODUCTION

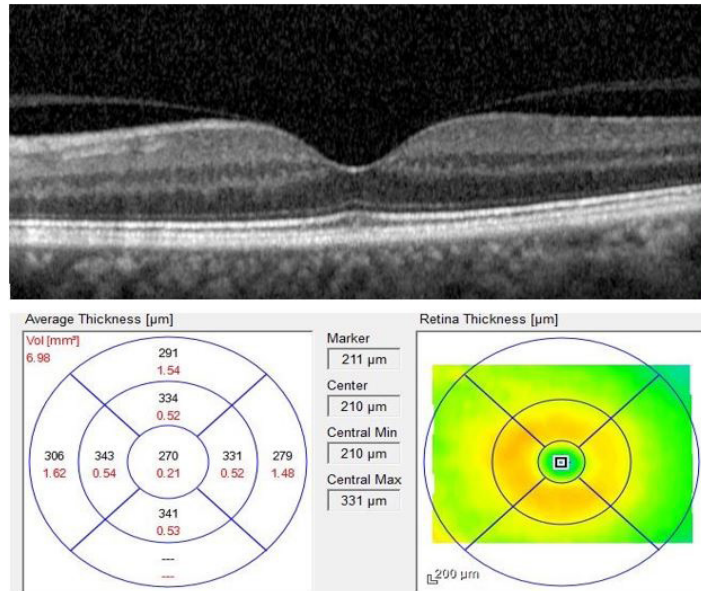
Vitreomacular interface pathology is thought to originate from an abnormal posterior vitreous detachment (PVD), specifically occurring when vitreous liquefaction and syneresis do not occur concurrently with weakening of the adhesion between the vitreous and retina. This can lead to an incomplete PVD and traction at points of stronger vitreoretinal adhesion, including at the fovea.¹ PVD is an active chronic process that begins as early as the fourth decade of life.² Vitreomacular attachment (VMA) occurs with incomplete PVD but no macular traction. Vitreomacular traction (VMT) occurs when an incomplete PVD results in residual vitreous attachment causing antero-posterior traction. The International Vitreomacular Traction Study (IVTS) Group published a VMT classification system based on anatomical findings using SD-OCT.³ OCT technology allows detailed examination of the macular layers, contour, and relationship of the macula to the vitreous so we can follow the pathology which was previously difficult to observe.^{4,5} OCT aids in the diagnosis and grading of VMA and VMT, and in the analysis of VMT presentations that are predictive of vitreous release by observing the focal width and angle of the traction, retinal layer involvement, or other related pathology.^{6,7,8} Three cases of vitreomacular interface adhesion and traction are presented below, demonstrating differing vitreomacular interface attachments with OCT.

CASE SERIES

Case 1

A 63-year-old white man presented to the clinic for an annual eye exam. He had a history of hypertension, controlled with losartan, and a 20-year history of diabetes type 2 with a recent A1C of 9.0 on metformin. His best corrected visual acuity (BCVA) through manifest refraction was 20/20 in both the right eye (OD) and left eye (OS). IOPs with Goldmann tonometry were 19 mmHg OD and 18 mmHg OS. The patient's anterior segment exam was within normal limits, with the exception of 2+ nuclear cataracts OU. Dilated fundus exam showed a flat macula with 3 dot blot hemorrhages temporal to the fovea OD. The macula OS was within normal limits. The retinal periphery was unremarkable for pathology OU. OCT showed a normal contoured fovea without edema OD. OCT assessment OS demonstrated a vitreomacular adhesion (VMA) (Figure 1). No treatment was necessary for asymptomatic VMA. The patient was informed of all findings, referred to his primary care provider for improved blood sugar control, and will continue to be followed.

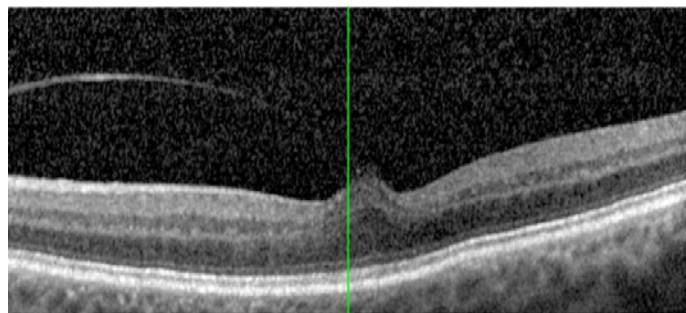
Figure 1: Top: OCT macular scan of caliper-measured adhesion of 1450 microns, without change in the foveal contour. Bottom: OCT thickness map showing no central edema.



Case 2

A 73-year-old white man presented complaining of bilateral blurry vision with distortion OS that had begun within the past week. He had a history of diabetes type 2 that was well-controlled with metformin. BCVA through manifest refraction was 20/25-2 OD and 20/25 OS. IOPs with Goldmann tonometry were 17 OD and 20 OS. The patient’s anterior exam was within normal limits, with the exception of mild asymmetry grade 1+ OD and 1 OS nuclear cataracts. Dilated posterior segment examination revealed normal findings in each eye, with the exception of a trace blunted foveal light reflex OS. OCT demonstrated vitreoretinal traction at the fovea without epiretinal membrane (ERM) formation, and little if any outer retinal involvement (Figure 2). The patient was counseled that the cataracts likely cause mildly decreased vision OU, but the distortion OS was due to VMT. He was dispensed an Amsler grid and scheduled for a 3-month follow-up.

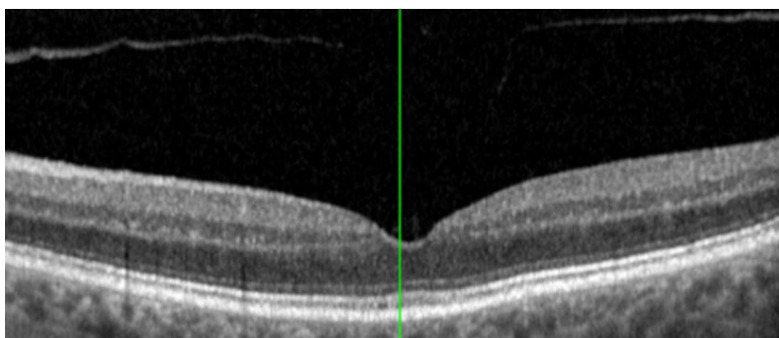
Figure 2: OCT macular scan of caliper-measured adhesion of 153 microns, with an altered foveal curvature secondary to traction. Traction is significant for a lack of ERM and limited outer retinal involvement.



Follow-up

Three months later, the patient reported less visual distortion OS over the previous several days. At this visit, BCVA was 20/25 OD and 20/20-2 OS. OCT demonstrated a released VMT OS, with complete detachment of the posterior hyaloid over the macular area and normal retinal anatomy (Figure 3). The patient was scheduled for annual follow-up.

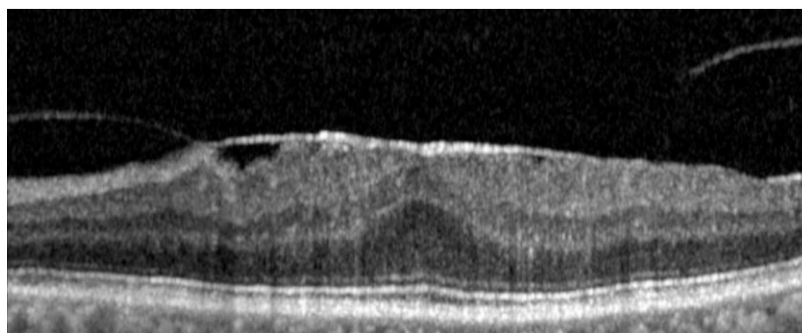
Figure 3: OCT macular scan of released traction, with return to the normal foveal contour.



Case 3

An active 94-year-old African-American man presented to the clinic for blurry vision OU with mild distortion OS. The patient's last eye exam was reported to be 5 years previously. He had a history of hypertension which was controlled with metropolol, high cholesterol controlled with simvastatin, and diabetes type 2 with a recent A1C of 7.0 controlled with metformin. BCVA through manifest refraction was 20/20 OD and 20/25 OS. IOPs with Goldmann tonometry were 8 OD and 10 OS. The patient's anterior segment examination was within normal limits with PCIOLs OD and OS. Dilated ophthalmoscopic fundus exam findings were normal OD, but there appeared to be an ERM OS. OCT confirmed the presence of an ERM with VMT OS (Figure 4). The patient was prescribed glasses and counseled concerning the ERM/VMT etiology of metamorphopsia and vision loss including a discussion concerning the risk/benefits of observation versus invasive treatment options. The patient was still visually functional and, when given the option of referral to a retinal specialist for further treatment, he declined. The risk of potential worsening including macular hole formation was discussed. The patient was dispensed an Amsler grid and scheduled for a 4-month follow-up. Two months later, the clinic was notified that the patient was deceased, secondary to causes unrelated to his ocular status, and follow-up was discontinued.

Figure 4: OCT macular scan of caliper-measured adhesion of 2581 microns with ERM.



DISCUSSION

Vitreomacular interface pathology is defined and graded based on the work of Duker *et al.* and The International Vitreomacular Traction Study (IVTS) Group.³ IVTS defined 2 separate classifications of incomplete vitreous detachment at the macula. The first classification, vitreomacular adhesion (VMA), is characterized by detachment of the perifoveal vitreous from the retinal surface with persistent vitreoretinal attachment within a 3 mm radius of the fovea, without any change in contour/anatomy of the retina. VMA is further subdivided as focal (attachment smaller than or equal to 1500 microns) or broad (attachment larger than 1500 microns). The second classification, vitreomacular traction (VMT), is defined as detachment of the perifoveal vitreous from the retinal surface with persistent vitreoretinal attachment within a 3 mm radius of the fovea, but includes changes to the normal contour of the fovea, potentially affecting any layer of the retina from the internal limiting membrane (ILM) to the retinal pigment epithelium (RPE). Like VMA, VMT is also subdivided into broad adhesions larger than 1500 microns, and focal adhesions smaller than or equal to 1500 microns. (Table 1)

Table 1

IVTS Adhesion grading scale			
	Fovea change	>1500 microns	<1500 microns
VMA	No contour change	Broad	Focal
VMT	Contour change	Broad	Focal

IVTS, International Vitreomacular Traction Study; VMA, vitreomacular adhesion; VMT, vitreomacular traction

IVTS further classified macular holes based on OCT measurements by defining a small full-thickness macular hole (FTMH) as smaller than or equal to 250 microns, a medium-sized hole as larger than 250 microns but smaller than or equal to 400 microns, and a large hole as larger than 400 microns. While the IVTS grading system is frequently referenced in VMA/VMT literature, the classic Irvine-Gasse grading system was developed prior to the availability of OCT and is based on fundoscopic appearance through biomicroscopy (Table 2).

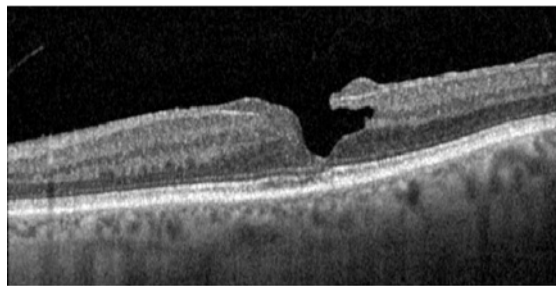
Table 2

IVTS Macular Hole defined with OCT	
Small	< 250 microns
Medium	>250 microns and <400 microns
Large	>400 microns

IVTS, International Vitreomacular Traction Study; OCT, optical coherence tomography

A partial-thickness or lamellar macular hole (LMH) may also occur with VMT. With ophthalmoscopy, LMH is often difficult to distinguish from FTMH. Both often appear as round well-defined orange or reddish lesions in the central macula. The distinction between LMH and FTMH is straightforward with OCT (Figure 5). With LMH, there is disruption of the outer retinal layers. Schisis between the outer plexiform layer and outer nuclear layer is common, but the photoreceptor layers remain intact.⁵

Figure 5: OCT macular scan demonstrating a lamellar macular hole.



VMA is most often asymptomatic and does not require treatment.^{3,9} Symptomatic VMT most commonly presents with decreased vision and metamorphopsia, photopsia, and/or micropsia; rarely, progressive visual field changes have been reported.^{10,11} VMT may require treatment to address symptoms, or to prevent or repair a macular hole. There is evidence in the literature that first-line treatment for VMT is observation. Wu *et al.* of The Pan American Collaborative Retinal Study Group reported that 21.4% of 168 eyes with VMT resolved without treatment, over a mean period of 12.3 months.¹²

John *et al.* reported that 32% of patients achieved spontaneous resolution of VMA/VMT, while 5% needed vitrectomy due to unresolved traction leading to a macular hole. The remaining 63% remained stable over a median follow-up time of 18 months.¹³

Through a literature review, Zhang *et al.* reported a wide variation (from 0 to 47%) in the rate of reported spontaneous resolution of VMT. Time of follow-up is a significant factor in the documented rates, with longer follow-up giving a higher percentage of resolution.¹⁴

Some clinical features, identifiable by OCT, suggest a higher likelihood of traction release without invasive treatment. Favorable factors include adhesions smaller than 400 microns, absence of ERM, and isolated inner retinal involvement (in-

ternal limiting membrane to the outer nuclear layer). Conversely, adhesions larger than 400 microns, presence of ERM, and significant outer retinal (Figure 6) (outer-nuclear layer through the retinal pigmented epithelial layer) involvement suggest that spontaneous resolution may not occur or that further treatment may be needed to resolve symptoms.^{6,7,8} The angle of attachment between the posterior hyaloid and the retina also plays a role in predicting spontaneous resolution of VMT. Theodossiadis *et al.* found that eyes experiencing spontaneous release of VMT generally had a wide angle between the posterior hyaloid surface at the fovea nasally (mean 50.58 degrees) and temporally (mean 51.25 degrees) (Figure 7), while eyes where VMT did not spontaneously release tended to have a small angle between the posterior hyaloid surface at the fovea nasally (mean 30.12 degrees) and temporally (mean 32 degrees) (Figure 8).⁶

Figure 6: OCT macular scan demonstrating significant outer retinal involvement and impending macular hole.

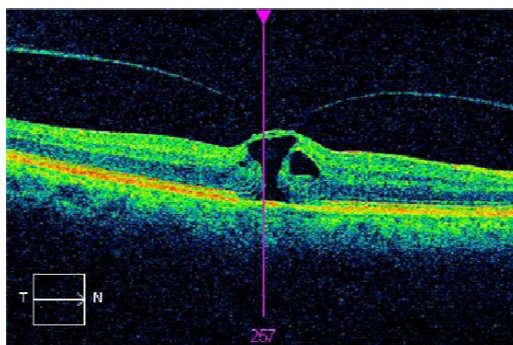


Figure 7: Large angle (A) created by the posterior hyaloid at the fovea in relation to a line parallel to the RPE.

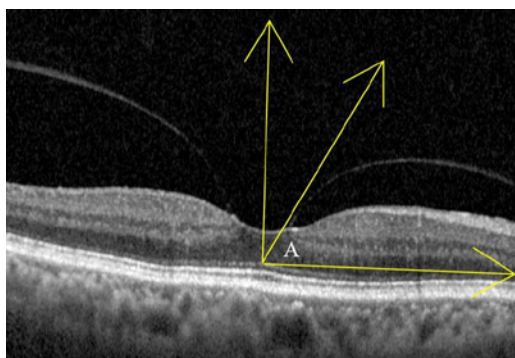
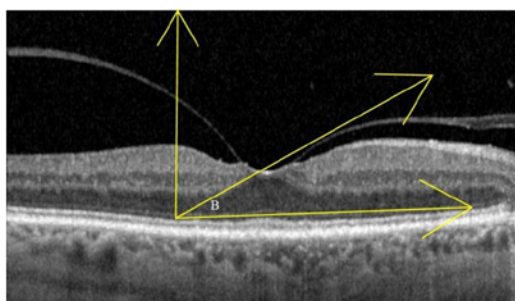


Figure 8: Small angle (B) created by the posterior hyaloid at the fovea in relation to a line parallel to the RPE.



Fundus examination and OCT alone do not allow an exact prediction of which tractions will spontaneously release or require further treatment. With anatomical changes leading to decreased vision, significant distortion, and/or macular hole formation, treatment options such as enzymatic vitreolysis, pneumatic vitreolysis, or vitrectomy with possible membrane peel should be considered as treatment options.

Ocriplasmin, a fragment of the plasmin enzyme, was approved for VMT treatment in 2012.^{9,15} The Microplasmin for Intravitreal Injection-Traction Release without Surgical Treatment (MIVI-Trust) trials demonstrated that 26.5%

of patients had VMT release within 28 days of treatment. The Ocriplasmin for Treatment of Symptomatic Vitreomacular Adhesion Including Macular Hole (OASIS) trial demonstrated 41.7% VMT resolution compared to a sham group at 28 days. Intravitreal injections pose small but known risks, and ocriplasmin is expensive and fails to achieve the therapeutic goal in a significant number of cases. Therefore, care must be taken when selecting patients to receive ocriplasmin.^{9,16} A literature review of published studies on the effective use of ocriplasmin indicates that success is much more likely within a fairly narrow subset of clinical findings: patients <65 years old, phakic lens status, adhesion diameter <1500 microns and the absence of ERM.⁸ If ocriplasmin is used with the goal of macular hole closure, it should be used in hole sizes smaller than 250 microns.^{17,18} [Mai]

Pneumatic vitreolysis (PVL) for symptomatic VMT involves the intravitreal injection of small quantities of expansive gases to induce the release of VMT, and in some cases closure of macular holes. While the exact mechanism of action is still unknown, it may involve a mechanical effect of the gas or could be caused by chemical mediators stimulated by the presence of the gas, which then stimulate PVD.^{19,20} The most common gas in use is perfluoropropane (C3F8). Sulfur hexafluoride (SF6) gas is also used, but is less effective. The best candidates for success are those with focal VMT, and grade 2 or smaller macular hole. In one study of 113 patients that compared VMT treatment with ocriplasmin, PVL with SF6, and PVL with C3F8, release of VMT occurred in 48% of ocriplasmin patients, 56% of SF6 patients and 84% of C3F8 patients.¹⁹ The procedure involves an anterior chamber paracentesis prior to the injection of expansive gases into the posterior chamber. Patients are instructed to avoid supine postures after the procedure. SF6 is absorbed faster and has a shorter duration in the eye, lasting about 12 days, while C3F8 lasts about 38 days.^{20,21}

VMT may require surgery when the patient is not a good candidate for PVL or enzymatic vitreolysis, especially when ERM is present. Surgery involves vitrectomy with possible internal limiting membrane peel with the goal of removing the tractional forces of VMT and ERM from the retinal surface.²² Vitrectomy with epiretinal membrane peel releases VMT and has over a 90% chance of closing macular holes.²³ A large-scale database review of electronic medical records from 16 different locations including 1,254 patients revealed modest visual acuity gains: logMAR 0.6 presurgery to logMAR 0.5 post surgery (20/80 to 20/63 gain). Thirty-three percent of the reviewed patients gained a logMAR of 0.3, which is approximately two Snellen lines.¹⁸ Surgery risks that must be considered include endophthalmitis, retinal tears, hemorrhage, increased ocular pressure, and cataract.^{24,25}

CONCLUSION

These three cases demonstrate a range of possible presentations of vitreomacular interface attachment as imaged with OCT. The first case was simple asymptomatic VMA found as a consequence of testing for other pathology. The second was a case with a low-risk presentation of minimally symptomatic VMT that released on its own without treatment. The third case was a symptomatic patient with higher-risk factors for retinal damage including ERM, broad traction, and outer retinal involvement. The third case demonstrates that a thorough risk/benefit discussion can lead to a patient being followed without burdening retinal specialists by over-referral.

As these cases also demonstrate, the vitreomacular interface abnormality continuum ranges from self-limiting asymptomatic VMA through symptomatic VMT that may require surgical intervention. Fortunately, a significant number of cases spontaneously resolve, or remain stable, and require nothing more than careful monitoring including serial OCT. Optometrists are ideally positioned to diagnose and monitor these patients, reserving referral to retinal specialty when indicated. ●

CORRESPONDING AUTHOR

Jeffery Curry, Email: jtc Curry@od.sco.edu

REFERENCES

- Johnson MW. Perifoveal vitreous detachment and its macular complications. *Trans Am Ophthalmol Soc.* 2005;103:537-567.
- Uchino E, Uemura A, Ohba N. Initial stages of posterior vitreous detachment in healthy eyes of older persons evaluated by optical coherence tomography. *Arch Ophthalmol.* 2001; 119(10):1475-1479
- Duker JS, Kaiser PK, Binder S, et al. The international vitreomacular traction study group classification of vitreomacular adhesion, traction, and macular hole. *Ophthalmology.* 2013;120(12):2611-2619.
- Mirza RG, Johnson MW, Jampol LM. Optical coherence tomography use in evaluation of the vitreoretinal interface: a review. *Surv Ophthalmol.* 2007;52(4):397-421.
- García-Layana A, García-Arumí J, Ruiz-Moreno JM, Arias-Barquet L, Cabrera-López F, Figueroa MS. A review of current management of vitreomacular traction and macular hole. *J Ophthalmol.* 2015;2015:809640. doi:10.1155/2015/809640
- Theodossiadis GP, Grigoropoulos VG, Theodoropoulou S, Datsiris I, Theodossiadis PG. Spontaneous resolution of vitreomacular traction demonstrated by spectral-domain optical coherence tomography. *Am J Ophthalmol.* 2014;157(4):842-851.e1. doi:10.1016/j.ajo.2014.01.011
- Almeida DR, Chin EK, Rahim K, Folk JC, Russell SR. Factors associated with spontaneous release of vitreomacular traction. *Retina.* 2015;35(3):492-497.
- Chatziralli I, Theodossiadis G, Grigoropoulos V, Datsiris I, Chatzirallis A, Theodossiadis P. Comparison of macular findings due to vitreomacular traction alone or in association with epiretinal membrane. *Eur J Ophthalmol.* 2017;27(1):86-92
- Dugel PU, Tolentino M, Feiner L, Kozma P, Leroy A. Results of the 2-year ocriplasmin for treatment for symptomatic vitreomacular adhesion including macular hole (OASIS) randomized trial. *Ophthalmology.* 2016;123(10):2232-2247.
- Bottós JM, Elizalde J, Rodrigues EB, Maia M. Current concepts in vitreomacular traction syndrome. *Curr Opin Ophthalmol.* 2012;23(3):195-201.
- Gospe SM, Bhatti MT, Chavis PS. Tug of war. *Surv Ophthalmol.* 2015;60(4):366-372.
- Wu L, Zas M, Berrocal M, et al. Anatomical and functional outcomes of symptomatic idiopathic vitreomacular traction: a natural history study from the Pan American Collaborative Retinal Study Group. *Retina.* 2016;36(10):1913-1918.
- John VJ, Flynn HW Jr, Smiddy WE, et al. Clinical course of vitreomacular adhesion managed by initially observation. *Retina.* 2014;34(3):442-446.
- Zhang Z, Dong F, Zhao C, et al. Natural course of vitreomacular traction syndrome observed by spectral-domain optical coherence tomography. *Can J Ophthalmol.* 2015; 50(2):172-179.
- Paul C, Heun C, Müller HH, Fauser S, et al. Impact of vitreoretinal interface architecture on successful vitreomacular traction resolution in eyes scheduled for intravitreal ocriplasmin therapy. *Retina.* 2017;37(7):1252-1260
- Khan MA, Haller JA. Ocriplasmin for treatment of vitreomacular traction: an update. *Ophthalmol Ther.* 2016;5(2):147-159
- Chatziralli I, Theodossiadis G, Xanthopoulou P, Miligkos M, Sivaprasad S, Theodossiadis P. Ocriplasmin use for vitreomacular traction and hole: A meta-analysis and comprehensive review on predictive factors for vitreous release and potential complications. *Graefes Arch Clin Exp Ophthalmol.* 2016;254(7):1247-1256
- Jackson TL, Donachie PH, Johnston RL; Vitreomacular Traction Study Group. Electronic medical record database study of vitrectomy and observation for vitreomacular traction. *Retina.* 2016;36(10):1897-1905.
- Chan CK, Mein CE, Crosson JN. Pneumatic vitreolysis for management of symptomatic focal vitreomacular traction. *J Ophthalmic Vis Res.* 2107;12(4):419-423.
- Steinle NC, Dhoot DS, Quezada Ruiz C, et al. Treatment of vitreomacular traction with intravitreal perfluoropropane (C3F8) injection. *Retina.* 2017;37(4):643-650.
- Day S, Martinez JA, Nixon PA, et al. Intravitreal Sulfur Hexafluoride Injections for the Treatment of Vitreomacular Traction Syndrome. *Retina.* 2016;36(4):733-737.
- Wickham L, Konstantinidis L, Wolfensberger T.J. Epiretinal membranes, Vitreomacular traction, and Cystoid macular edema. In: *Ryan's Retina*, 6th ed. London: Elsevier, 2018:2194-2212.
- Gaudric A, Tadayoni R. Macular hole. In: *Ryan's Retina*, 6th ed. London: Elsevier, 2018:2213-2232.
- Yu G, Duguay J, Marra K, et al. Efficacy and safety of treatment options for vitreomacular traction: A case series and meta-analysis. *Retina.* 2016; 36(7):1260-1270.
- Scholz P, Sitnilska V, Hess J, Becker M, Michels S, Fauser S. Comparison of resolution of vitreomacular traction after ocriplasmin treatment of vitrectomy. *Retina.* 2019;39(1):180-185.