



Cerebral Protection During Coronary Artery Bypasses Grafting in Bilateral Total Internal Carotids Occlusion: Case Report

Afshin Froutan¹, Mohammad Rezvan Nobahar², Hossein Rahimian³, Azita Chegini⁴ and Faranak Behnaz^{5,*}

¹Department of Anesthesiology and Cardiac Surgery, Besat Military Air Force Hospital, Tehran, Iran

²Department of Anesthesia of Erfan Hospital, Tehran, Iran

³Department of Cardiac Surgery, Besat Military Air Force Hospital, Tehran, Iran

⁴Blood Transfusion Research Center, High Institute for Research and Education in Transfusion Medicine, Tehran, Iran

⁵Anesthesiology Department, Shohada-e-Tajrish Hospital, Shahid Beheshti University of Medical Sciences, Tehran, Iran

*Corresponding author: Assistant Professor, Anesthesiology Department, Shohada-e-Tajrish Hospital, Shahid Beheshti University of Medical Sciences, Tehran, Iran. Email: faranak.behnaz@gmail.com

Received 2018 June 17; Revised 2018 October 27; Accepted 2019 January 13.

Abstract

Introduction: The best management for the patient with coronary artery disease (CAD) that requires emergent coronary bypass graft surgery (CABG) with bilateral total internal carotid artery occlusions previously reported. Here we report two successful cases of CABG with additional occlusion in the circle of Willis anterior or posterior communicating artery “incomplete cow” with on-pump technique and cerebral protection considerations.

Case Presentation: Bilateral carotid artery occlusion, coronary artery disease, and emergency operation with cardiopulmonary bypass are associated with increased stroke, especially when there is one additional occlusion of the cerebral artery in the circle of Willis. Routine preoperative carotid artery sonography and selective carotid angiography revealed bilateral total carotid occlusion in both cases in addition, CT-angiography also confirmed occlusions of right posterior communicating in the first case and left posterior communicating artery in the second case. Collateral circulation feeding in the intracranial circulations originated mainly from the vertebrobasilar system (compensatory phase) preoperative physical examinations showed no neurological deficit. Operation was done successfully with moderate hypothermia and different cerebral protection considerations and postoperative courses were uneventful and patients discharged from hospital seven days post operation.

Conclusions: Anesthesia should consider hemodynamic management and avoid significant tachycardia or bradycardia and severe hypertension or hypotension.

Keywords: Cardiopulmonary Bypass, Cerebral Protection, Carotid Occlusion

1. Introduction

Bilateral carotid artery occlusions, coronary artery disease, and emergency operation with cardiopulmonary bypass are associated with increased stroke (1, 2), especially when there is one additional occlusion of the cerebral artery in the circle of Willis. Carotid artery occlusion is reported in 10% - 20% of the patients undergoing coronary artery bypass grafting (CABG) and an estimated 30% of stroke is related to CABG (3).

Coronary revascularization in a patient with more than 90% carotid artery stenosis is associated with an increased risk of postoperative stroke, which On-pump surgery increases the risk of stroke (4-7).

Proper advanced-surgical procedure with moderate hypothermia and anesthesiology considerations for cere-

bral protection during CABG operation, such as volatile anesthetics, intravenous anesthetic agents, steroids, N-methyl-D-aspartate (NMDA) antagonists (8), thiopental infusion, α -stat strategy and ice-pack head surrounding (topical brain protection), maintenance of acceptable mean blood pressure (MBP), and cerebral oximetry in the presence of cerebrovascular diseases can minimize the risk of severe complications. Non-responsive severe angina to medical therapy necessitated urgent CABG in our patients with good perioperative anesthesia management. Operations were done without any events or cerebral complications. The purpose of these case reports was to assess the perioperative stroke and morbidity among patients who underwent coronary bypass surgery and had internal carotid artery occlusion.

2. Case Presentation

2.1. Case 1

A 62-year-old man presented with unstable angina, with a medical history of old MI (8 months ago), hypertension, hyperlipidemia, diabetes mellitus type II, smoking, and positive family history.

The preoperative evaluation showed severe three-vessel disease with left ventricular ejection fraction ~ 30%, mild mitral regurgitation, regional wall motion abnormality "RWMA" and moderate pulmonary hypertension.

Bilateral internal carotid arteries occlusion was demonstrated in preoperative evaluation using duplex scanning and carotid angiography.

Multi-slice spiral CT-angiography of both carotids and vertebral arteries, the circle of Willis and corresponding, confirmed these lesions and absent of right posterior communicating artery. No neurological deficits were found on clinical examination with normal brain CT (Figure 1).

2.2. Case 2

A 63-year-old man presented with unstable angina, with a past medical history of old MI (1 year ago), smoking, opium addiction, DM II, COPD, positive family history, and dizziness.

In the preoperative evaluation, we found severe three-vessel disease, LVEF 40%, RWMA, no valvular heart disease, and normal pulmonary artery pressure.

Except for dizziness and occasionally vertigo, no neurological sign and symptoms were found.

Bilateral total internal carotid arteries occlusion was demonstrated in preoperative evaluation using duplex scanning and carotid angiography. Multi slices spiral CT-angiography of extracranial and intracranial carotid and vertebral basilar CT-angiography confirmed these lesions and absent of left posterior communicating artery. No neurological deficits were found on clinical examination with normal brain CT.

2.3. Anesthetic Considerations

After standard monitoring, patients were medicated with midazolam (0.1 mg/kg) and fentanyl (3 mcg/kg), left radial artery catheterization with local anesthesia, for invasive blood pressure monitoring and arterial blood gas (ABG) analysis was done, then cerebral oximetry monitoring was initiated. The base of ABG was normal.

The general anesthesia was induced with: Etomidate 0.2 mg/kg, fentanyl 5 µg/kg, in titrated dose, cisatracurium 0.2 mg/kg, and then intubation was done.

After the induction, central venous catheter and pulmonary artery catheter from right internal jugular vein with supraclavicular and central approach were done and

a nasal gastric tube was inserted afterward. Maintenance of anesthesia kept with 0.4 - 0.6 ng ml⁻¹ of sufentanil, midazolam 20 - 100 mcg/kg/hr, and cisatracurium 0.03 mg/kg IV infusions. Bispectral index "BIS" monitoring for depth of anesthesia and temperature monitoring were initiated as well. A cold crystalloid Cardioplegia "A" Solution was used.

CABG was done with moderate hypothermia (nasopharyngeal temperature 33 - 34°C). To perform cardiopulmonary bypass for proper cerebral protection on cardiopulmonary bypass, we gave Thiopental infusion (2 - 3mg/kg/h), the use of external ice pack of skull; "ABG" analysis in α -stat strategic management of arterial blood gases was selected to control a normal range for pCO₂ (35 to 45 mmHg [4.7 to 6 kPa]) and pH (7.35 to 7.45) for maintaining PaCO₂ and pH within physiologic range during to protect cerebral autoregulation, control of blood sugar in the range of 100 - 140mg/dL with insulin infusion (9), preserved mean arterial blood pressure in the range 70 - 80 mmHg, preserved hematocrit in the range of 20 - 25, and keeping the BIS \geq 30 continuous cerebral oximetry monitoring in acceptable ranges.

For prevention of embolization of atheromatous material, air or fat, arterial filter were used during CPB.

During CPB, the pump flow rate was 2.4 L min⁻¹ m⁻² and perfusion pressure 50 - 80 mmHg. Before separation from CPB, the patients were rewarmed (nasopharyngeal temperature 37°C, bladder temperature \geq 36°C) and epinephrine 0.04 µg kg⁻¹ min⁻¹ was infused.

There were no events during CPB and the patient weaned from CPB machine after revascularization and re-warming with a minimal dose of Inotrope as explained above, with stable hemodynamics and acceptable ABG and electrolytes.

3. Discussion

Our cases had one additional cerebral artery occlusion of the circle of Willis "cow" with a more chance of stroke, which had done fortunately without any complications and with proper preoperatively management good planning for cerebral protection.

These cases and others strongly indicated that cerebral collateral circulation functionally predicts neurologically outcome of patients with severe carotid stenosis and totally occlusion of arteries.

Severe carotid disease in patients with CABG is generally unilateral and asymptomatic. Carotid revascularization may be justified in symptomatic or high-risk patients who suffer from bilateral severe stenosis (10). The mechanism of stroke in patients with total stenosis of the carotid artery may vary from the other CABG patients. There are different causes of stroke in patients with total occlusion of the carotid artery such as embolism from the

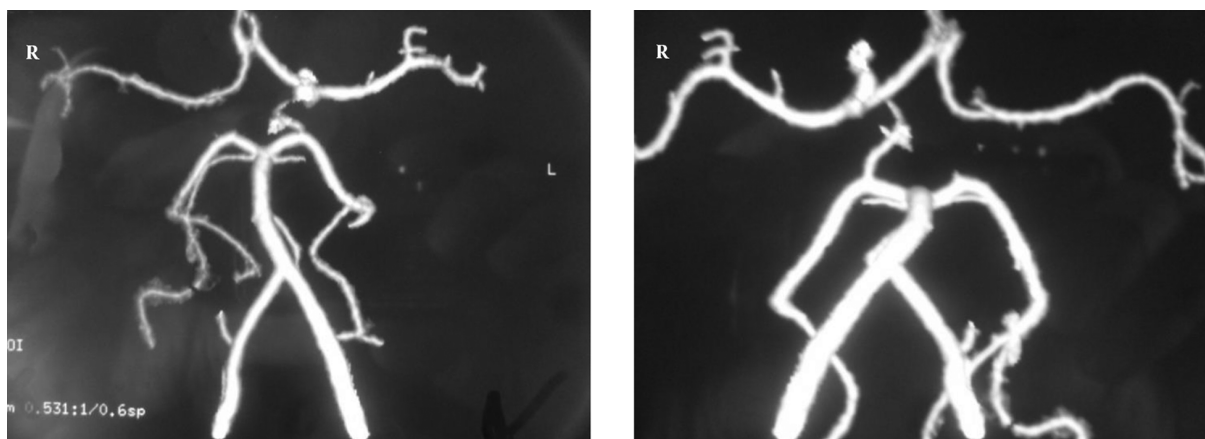


Figure 1. CT-angiography of brain in case 1 with absent of right posterior communicating artery seen in (a) and (b) showed left posterior communicating artery “incomplete COW”

heart via collateral circulation or from the blind stump of the occluded ICA and Low perfusion. Van Everdingen et al. showed that cerebral hemodynamic is very important in patients symptomatic ICA occlusion, which insufficient collateral supply and ICA occlusion can decrease perfusion pressure in the ipsilateral hemisphere and produce severe ischemia and infraction. Gold et al. suggested that two strategies of hemodynamic management, which incidence of combined cardiac and neurological complications, was lower in the high-arterial pressure group (4.8%) than in the low-pressure group (12.9%) ($P = 0.05$). The perioperative care in these patients is important, particularly the maintenance of perfusion pressure in the area supplied to the occluded carotid artery. Likewise, we tried to preserve cerebral flow. Osswald et al. illustrated successful CABG for a patient with asymptomatic bilateral ICA occlusion (Table 1). They used pulsatile high-flow extracorporeal circulation under moderate hypothermia and maintained a pressure mean of 80 mmHg (11).

Surgical timing is important for perioperative complications in patients with severe disease in both carotids and coronary lesion, especially stroke. The anesthesiologist should do preoperative medical therapy optimization, advanced monitoring, preservation of cerebral oxygenation, and stable hemodynamic during the surgery (15).

Anesthesia considerations include careful hemodynamic management, avoidance of significant tachycardia or bradycardia and severe hypertension or hypotension. Induction of anesthesia needs attention to narcotic-based inductions or careful titration of hypnotic agents, such as etomidate. Alpha-receptor agonists (Phenylephrine) and short-acting beta-receptor blockers (Esmolol) can also be effective in avoiding acute hemodynamic instability. Agents with significant beta-agonist such as ephedrine

and epinephrine should be administered cautiously to increase myocardial oxygen demand and myocardial ischemia. Pre-induction placement of invasive monitoring such as arterial blood pressure monitoring is recommended in order to tightly control the blood pressure during operation. Pre-induction placement of central access and monitoring may be suitable but it should be performed when the patient doesn't experience the stress or significant respiratory compromise (15).

3.1. Conclusions

These cases and others strongly indicated that cerebral collateral circulation functionally might neurologically predict the outcome of the patients with severe carotid stenosis and totally occlusion of arteries. Therefore, anesthesiologist should consider hemodynamic management and avoid significant tachycardia or bradycardia and severe hypertension or hypotension.

Acknowledgments

we are very thankful to cardiac surgeon, Department of Cardiac Surgery in Best Military Air Force Hospital, Tehran, Iran

Footnotes

Authors' Contributions: All authors meet the standard criteria of authorship based on the recommendations of the international committee of medical journal editors.

Conflict of Interests: None declared.

Funding/Support: None declared.

Table 1. Characteristics of Patients Who Underwent CABG Surgery with Bilateral Total Carotid Occlusion

	Patient	Age/Sex	CPB	Hypothermia	Neurologic Symptoms	Post-Operative Event	Treatment	Outcome	Considerations
Gravlee et al. (12)	1	56/M	Yes	Moderate	Yes	No	CABGX3	Home	-
	2	58/M	Yes	Moderate	Yes	No	CABGX4	Home	-
	3	56/M	Yes	Moderate	Yes	No	CABGX3	Home	-
Osswald et al. (13)	4	68/M	Yes	Moderate	No	No	CABGX3	Home	-
Mand'ak et al. (14)	5	74/F	Yes	Normothermia	Yes	No	CABGX2	Home	-
Ginay et al.	6	59/M	Yes	Moderate	No	No	CABGX2	Home	-
	7	62/M	yes	Moderate	No	No	CABGX4	Home	-
Case 1	8	62/M	Yes	Moderate	No	No	CABGX4	Home	Incomplete COW
Case 2	9	63/M	Yes	Moderate	Yes	No	CABGX5	Home	Incomplete COW

Abbreviations: CABG, coronary artery bypasses grafting; CPB, cardiopulmonary bypass; F, female; M, male.

References

- Hertzer NR, Loop FD, Taylor PC, Beven EG. Combined myocardial revascularization and carotid endarterectomy. Operative and late results in 331 patients. *J Thorac Cardiovasc Surg.* 1983;**85**(4):577-89. [PubMed: 6834875].
- Breslau PJ, Fell G, Ivey TD, Bailey WW, Miller DW, Strandness DJ. Carotid arterial disease in patients undergoing coronary artery bypass operations. *J Thorac Cardiovasc Surg.* 1981;**82**(5):765-7. [PubMed: 6975404].
- Abbaszadeh M. The impact of carotid artery disease on outcomes of patients undergoing coronary artery bypass grafting. *Rev Bras Cir Cardiovasc.* 2011;**26**(2):258-63. doi: 10.1590/S0102-76382011000200017. [PubMed: 21894417].
- Faggioli GL, Curl GR, Ricotta JJ. The role of carotid screening before coronary artery bypass. *J Vasc Surg.* 1990;**12**(6):724-9. discussion 729-31. doi: 10.1067/mva.1990.24458. [PubMed: 2243408].
- Rizzo RJ, Whittemore AD, Couper GS, Donaldson MC, Aranki SF, Collins JJ, et al. Combined carotid and coronary revascularization: The preferred approach to the severe vasculopath. *Ann Thorac Surg.* 1992;**54**(6):1099-108. discussion 1108-9. doi: 10.1016/0003-4975(92)90076-G. [PubMed: 1449293].
- Chang BB, Darling RC 3rd, Shah DM, Paty PS, Leather RP. Carotid endarterectomy can be safely performed with acceptable mortality and morbidity in patients requiring coronary artery bypass grafts. *Am J Surg.* 1994;**168**(2):94-6. doi: 10.1016/S0002-9610(94)80043-X. [PubMed: 8053534].
- Brener BJ, Brief DK, Alpert J, Goldenkranz RJ, Parsonnet V. The risk of stroke in patients with asymptomatic carotid stenosis undergoing cardiac surgery: A follow-up study. *J Vasc Surg.* 1987;**5**(2):269-79. doi: 10.1016/0741-5214(87)90135-2. [PubMed: 3820401].
- Liu H, Tariq R, Liu GL, Yu L. Pharmacological cerebral protection in cardiac surgery: An update. *J Anesth Perioper Med.* 2017;**4**(1):23-37. doi: 10.24015/JAPM.2017.0004.
- Johnsson P, Algotsson L, Ryding E, Stahl E, Messeter K. Cardiopulmonary perfusion and cerebral blood flow in bilateral carotid artery disease. *Ann Thorac Surg.* 1991;**51**(4):579-84. doi: 10.1016/0003-4975(91)90315-H. [PubMed: 2012416].
- Venkatachalam S, Shishhebor MH. Management of carotid disease in patients undergoing coronary artery bypass surgery: Is it time to change our approach? *Curr Opin Cardiol.* 2011;**26**(6):480-7. doi: 10.1097/HCO.0b013e32834a7035. [PubMed: 21822137].
- Suematsu Y, Nakano K, Sasako Y, Kobayashi J, Kitamura S, Takamoto S. Conventional coronary artery bypass grafting in patients with total occlusion of the internal carotid artery. *Heart Vessels.* 2000;**15**(6):256-62. doi: 10.1007/s003800070002. [PubMed: 11766062].
- Gravlee GP, Cordell AR, Graham JE, Hudspeth AS, Roy RC, Royster RL, et al. Coronary revascularization in patients with bilateral internal carotid occlusions. *J Thorac Cardiovasc Surg.* 1985;**90**(6):921-5. [PubMed: 3877850].
- Osswald BR, Vahl CF, Fleischer F, Hagl S. Successful revascularisation for unstable angina of a patient with asymptomatic bilateral internal carotid occlusion, 70% stenoses of the external carotid arteries, and other circulation disturbances. *Thorac Cardiovasc Surg.* 1997;**45**(4):200-3. doi: 10.1055/s-2007-1013723. [PubMed: 9323823].
- Mand'ak J, Lonský V, Dominik J, Brtko M, Kubíček J. [Surgical myocardial revascularization in a female patient with bilateral occlusion of the common carotid arteries]. *Rozhl Chir.* 2002;**81**(7):360-3. Czech. [PubMed: 12197172].
- Oakes DA, Eichenbaum KD. Perioperative management of combined carotid and coronary artery bypass grafting procedures. *Anesthesiol Clin.* 2014;**32**(3):699-721. doi: 10.1016/j.anclin.2014.05.005. [PubMed: 25113728].