






Spontaneously Healed Horizontal Root Fracture: A Case Report

Yasaman Rezvani ^a, Nahid Askarizadeh ^b, Azar Heydari ^c, Firouzeh Efafi ^d, Leila Eftekhari ^e, Parisa Zarnegarnia^d

^aAssistant Prof., Dept. of Periodontics, School of Dentistry, Shahid Beheshti University of Medical Sciences, Tehran, Iran.

^bAssociate Prof., Dept. of Periodontics, School of Dentistry, Azad University of Medical Sciences, Tehran, Iran.

^cAssistant Prof., Dept. of Endodontics, School of Dentistry, Shahid Beheshti University of Medical Sciences, Tehran, Iran.

^dDentist, Private Practice, Tehran, Iran.

^eAssistant Prof., Dept. of Pedodontics, School of Dentistry, Zanjan University of Medical Sciences, Zanjan, Iran.

Correspondence to Azar Heydari (email: Azarheydari1@gmail.com).

(Submitted: 15 August 2020 – Revised version received: 7 October 2020 – Accepted: 10 October 2020 – Published online: Fall 2020)

Objectives Root fracture occurs less frequently in comparison with other traumatic dental injuries, and accounts for about 0.5%-7% of all dental injuries in permanent dentition. Complications associated with root fracture include pulp necrosis, root resorption, and pulp canal obliteration. Maintaining tooth vitality is the mainstay of treatment of horizontal root fracture in permanent teeth.

Case In this study, a clinical case of horizontal root fractures in the middle third of maxillary right and left central incisors (teeth #11 and #21) of an 8-year-old girl is reported. The patient was followed-up for 3 years. The treatment plan was watchful waiting and after 3 years, the vitality tests were still positive, and no pathology was detected on control radiographs.

Conclusion Careful clinical examination, accurate diagnosis, and regular radiographic follow-ups are necessary for efficient treatment and successful outcome of teeth with horizontal root fractures.

Keywords Endodontics; Splints; Tooth Fractures; Wounds and Injuries; Wound Healing

Introduction

Root fracture occurs less frequently in comparison with other dental injuries, and accounts for 0.5%-7% of all dental injuries in permanent dentition. Falls, fights, or sport accidents are among the most common causes of root fractures.¹ Root fractures most commonly occur in the age of 11 to 20 years, and maxillary central incisors are affected in 75% of the cases.² Horizontal root fractures are commonly located in the middle third of the root.³

Root fractures are generally detected immediately after injury; but in some cases, they are identified following routine clinical or radiographic examinations.⁴ Based on a previous study, during horizontal root fracture, coronal fragment may be displaced in different directions. Generally, repositioning of the coronal fragment is the first step in treatment of a fractured root.³

Root fracture complications include pulp necrosis, root resorption, and pulp canal obliteration. Clinical management and regular patient follow-ups are necessary to achieve treatment success.⁵

This study reports two horizontal mid-root fractures in the right and left maxillary central incisors of an 8-year old girl, which were treated by repositioning and fixation. Optimal healing was noticed at the 3-year follow-up examination.

Case

An 8-year old girl with a chief complaint of displacement

of maxillary central incisors (teeth #11 and #21) secondary to trauma presented to the Pediatric Department of School of Dentistry, Azad University of Medical Sciences. The patient reported trauma to her face 10 days earlier. She had fell and hit the ground.

Radiographic examination indicated horizontal root fractures, and a distinct radiolucent line separating the root fragments in the middle third of both maxillary central incisors was also evident. Clinical examination revealed palatal displacement and pathological mobility (grade I of Miller's classification⁶) of both maxillary central incisors. There was no tooth discoloration or tenderness or pain on percussion or palpation. Soft tissue examination revealed no sign of a sinus tract. Vitality tests of the teeth were positive for electric pulp test and cold test.

Both right and left central incisors were repositioned, and the teeth were splinted to the lateral incisors using #14 stainless steel wire and composite resin for 4 weeks (Figure 1).

The treatment plan was watchful waiting; therefore, endodontic treatment was not performed for the teeth with horizontal mid-root fracture.

Regular follow-ups (clinical examination and bisect radiographs) were scheduled every 1 to 2 months. One-year radiograph of the teeth showed trabeculation at the fracture lines of the teeth, indicating hard tissue formation and preservation of pulp vitality in both fragments. After 3 years, the vitality tests were still positive and no pathology was found on control radiographs (Figure 2).

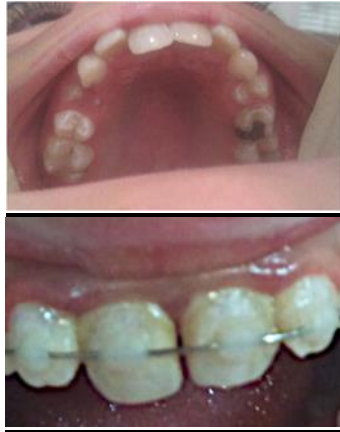

Figure 1-(a) Palatal displacement of right and left maxillary central incisors. (b) Repositioned and splinted teeth

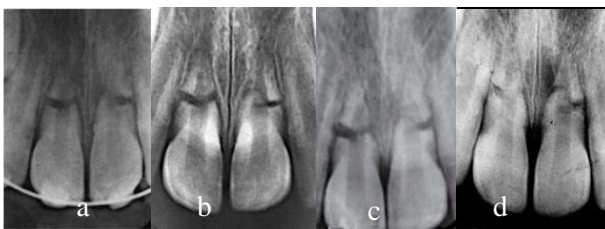


Figure 2- Periapical radiographs in the follow-ups: (a) 2 weeks after trauma, (b) 1 month after trauma, (c) 18 months after trauma, (d) 3 years after trauma

Discussion

Various etiologies have been described for root fractures such as motor vehicle accidents, sport injuries, violence, or malocclusion.^{7, 8} Anterior region of the maxilla (central incisors with completely formed roots) is the most common site of horizontal root fracture. Pulp, dentin, cementum, and periodontal ligament are involved in root fractures. Healing of horizontally fractured roots occurs in 74% of all cases with this type of injury.^{9, 10}

The initial supportive treatment consists of immediate repositioning of the displaced fragment and its stabilization with a passive splint. Also, the displaced fragment should be assessed radiographically.¹¹ In the case presented in this study, the patient reported trauma to her face 10 days earlier, although the teeth were repositioned and splinted using a semi-rigid wire for 4 weeks based on previous studies.¹²⁻¹⁴

In this type of fracture, the risk of damage to the pulp is lower in comparison with other dental traumatic injuries.¹¹ The pulp response during the healing process

often includes pulp canal obliteration or pulp necrosis.³ The pulp survival is not affected by the location of root fracture line¹² although the diastasis between the fragments plays a major role in pulpal necrosis.^{15, 16} The greater the displacement of the coronal segment, the higher the risk of coronal segment pulp necrosis because of the higher risk of impaired blood supply.¹⁷

Prognosis of teeth with horizontal root fractures depends on the extent of displacement of the coronal segment, the extent of fracture line, the occlusion, the pulp tissue status, and the general health status of the patient.¹⁵⁻¹⁸

According to the classification of Andreassen and Hjorting-Hansen for fracture healing, the healing process can occur in four different types¹²:

1. Healing with hard tissue fusion
2. Interposition of connective tissue
3. Interposition of connective tissue and bone
4. Formation of granulation tissue which is seen following pulp necrosis.

According to previous studies, in most cases, pulp remains vital and there is no need for endodontic treatment^{4, 5}; therefore, endodontic treatment was not performed for the teeth with horizontal mid-root fracture in this study. Watchful waiting strategy was chosen as the treatment plan followed by initial repositioning and splinting.

In our case, healing occurred gradually by the formation of hard tissue at the fracture line; thus, it may be concluded that long-term follow-up is important for patients with injuries since pathological changes may occur after several years following injury. At least one year of follow up¹⁴ to maximum 4 years of follow-up has been recommended in order to monitor the pulpal status of fractured roots.^{13, 17} In this study, the patient was monitored clinically and radiographically for 3 years in order to assess pulpal status because of the possibility of pulpal necrosis due to pulp infection, which would jeopardize tooth survival.¹³

Conclusion

Careful clinical examination, accurate diagnosis, and regular radiographic follow-ups are necessary for efficient treatment and successful outcome of teeth with horizontal root fractures.

Conflict of Interest

None Declared ■

References

1. Saroğlu I, Sönmez H. Horizontal root fracture followed for 6 years. *Dent Traumatol.* 2008 Feb;24(1):117-9.
2. Molina JR, Vann WF Jr, McIntyre JD, Trope M, Lee JY. Root fractures in children and adolescents: diagnostic considerations. *Dent Traumatol.* 2008 Oct;24(5):503-9.
3. Karhade I, Gulve MN. Management of horizontal root fracture in the middle third via intraradicular splinting using a fiber post. *Case Rep Dent.* 2016 Jan;2016:9684035.
4. Ozbek M, Serper A, Calt S. Repair of untreated horizontal root fracture: a case report. *Dent Traumatol.* 2003 Oct;19(5):296-7.

5. Shafie L, Farzaneh F, Hashemipour MA. Repair of horizontal root fracture: A case report. *Iran Endod J* . 2011 Sep;6(4):176-8.
6. Miller DD. Miller classification of marginal tissue recession revisited after 35 years. *Compendium of Continuing Education in Dentistry*. 2018 Sep;39(8).
7. Andrade ES, de Campos Sobrinho AL, Andrade MG, Matos JL. Root healing after horizontal fracture: a case report with a 13-year follow up. *Dent Traumatol*. 2008 Aug;24(4):e1-3.
8. Pickrell BB, Serebrakian AT, Maricevich RS. Mandible Fractures. *Semin Plast Surg*. 2017 May;31(2):100-7.
9. Panzarini SR, Pedrini D, Poi WR, Sonoda CK, Brandini DA, Monteiro de Castro JC. Dental trauma involving root fracture and periodontal ligament injury: a 10-year retrospective study. *Braz Oral Res*. 2008 Jul-Sep;22(3):229-34.
10. Oztan MD, Sonat B. Repair of untreated horizontal root fractures: two case reports. *Dent Traumatol*. 2001 Oct;17(5):240-3.
11. Malhotra N, Kundabala M, Acharaya S. A review of root fractures: diagnosis, treatment and prognosis. *Dent Update*. 2011 Nov;38(9):615-24.
12. Andreasen JO, Andreasen FM, Mejäre I, Cvek M. Healing of 400 intra-alveolar root fractures. 2. Effect of treatment factors such as treatment delay, repositioning, splinting type and period and antibiotics. *Dent Traumatol*. 2004 Aug;20(4):203-11.
13. Choi Y, Hong SO, Lee SR, Min KS, Park SJ. Healing after horizontal root fractures: 3 cases with 2-year follow-up. *Restor Dent Endod*. 2014 May;39(2):126-31.
14. DiAngelis AJ, Andreasen JO, Ebeleseder KA, Kenny DJ, Trope M, Sigurdsson A, et al. Guidelines for the Management of Traumatic Dental Injuries: 1. Fractures and Luxations of Permanent Teeth. *Pediatr Dent*. 2016 Oct;38(6):358-68.
15. Cantore S, Ballini A, Crincoli V, Grassi FR. Treatment of horizontal root fracture: a case report. *Cases J*. 2009 Jun;2:8101.
16. Cvek M, Tsilingaridis G, Andreasen JO. Survival of 534 incisors after intra-alveolar root fracture in patients aged 7-17 years. *Dent Traumatol*. 2008 Aug;24(4):379-87.
17. Hargreaves KM, Cohen S, Berman LH. Cohen's pathways of the pulp. 11th ed. St. Louis: Mosby Elsevier; 2016:676-7.
18. Andreasen JO, Andreasen FM, Andreasen L. Textbook and color atlas of traumatic injuries to the teeth. 5 ed, Wiley-Blackwell. 2019;(15):377-407 .

How to cite:

Yasaman Rezvani, Nahid Askarizadeh, Azar Heydari, Firouzeh Efafi, Leila Eftekhari, Parisa Zarnegarnia. Spontaneously Healed Horizontal Root Fracture: A Case Report. *J Dent Sch* 2019;37(4):143-145.