

## Soft tissue facial profile and anteroposterior lip positioning in Iranians

\*<sup>1</sup>Fataneh GhorbanyJavadpour<sup>2</sup>Mashaallah Khanemasjedi

<sup>1</sup>AssisantProfessor, Dept. of Orthodontics, School of Dentistry, Jondi Shapour University of Medical Sciences, Ahvaz, Iran. E-mail:fa.ghorbanyjavad@gmail.com

<sup>2</sup>Assistant Professor, Dept. of Orthodontics, School of Dentistry, Jondi Shapour University of Medical Sciences, Ahvaz, Iran.

### Abstract

**Objective:** Since orthodontic and orthognathic treatment planning in each ethnic group must be done according to the soft tissue facial characteristics regarded as beauty, they thus vary from country to country. The main purpose of this article was to determine the mean range of the middle third of soft tissue facial profile and anteroposterior lip positioning using 3 angular and 2 linear measurements in adult male and female Iranians to compare with European standards.

**Methods:** After clinical examination of 180 dental students, 70 Iranian adults who had normal occlusion aged between 21 to 29 years (mean:24.5 years) were selected (35 males and 35 females). After obtaining consent form, lateral cephalograms were taken in natural head position (NHP) (as seen in a mirror) and analyzed according to the Ricketts (E-Line), Tweed-Merrifield (Z-angle) and Holdaway (H-angle). For comparison of data with standards, the One-Sample-t-test and for comparison of measurements between groups, Independent Sample-t-test was used.

**Results:** Radiographic evaluation revealed that all Iranian samples had significant differences with European standards with no differences between males and females. In the Ricketts (E-Line) analysis, both upper ( $p < 0.001$ ) and lower ( $p < 0.01$ ) lips were behind the E-line. In the Tweed-Merrifield (Z-angle) analysis this angle in the Iranian sample was smaller ( $p < 0.001$ ) and in the Holdaway (H-angle) analysis our sample had smaller H-angle as well ( $p < 0.001$ ).

**Conclusion:** Iranian adults have retruded upper and lower lip position in both sexes and more convex profile than European standards; this may be due to a more retruded position of the chin and lips or more prominence of the nose in Iranian samples.

**Key words:** Holdaway analysis, Iranian adults, Lateral cephalogram, Ricketts esthetic analysis, Soft tissue profile, Tweed-Merrifield analysis.

**Please cite this article as:**

Ghorbany Javadpour F, Khanemasjedi M. Soft tissue facial profile and anteroposterior lip positioning in Iranians. *J Dent Sch* 2014; 32(2):90-95.

Received: 05.05.2013

Final Revision: 14.12.2013

Accepted: 17.12.2013

### Introduction:

Balance and harmony of different parts of the face are determined by both hard and soft tissues. Contemporary orthodontic therapy seeks to achieve functional and esthetic treatment goals. Tooth movement and orthognathic surgery are performed not only to attain appropriate occlusal relationships, but also to maximize the esthetic outcome (1). An esthetically pleasing smile is a key determinant of successful orthodontic treatment and patient satisfaction (2). In clinical orthodontic and orthognathic surgical planning, many special

assessments for soft tissue analysis of the face via Rickett's, Tweed-Merrifield and Holdaway analyses are done. White American-European standards may not be proper for evaluation of other ethnicities (3-5).

Attention to facial esthetics and role of the teeth has increased over the past decade because at present young adults experience more exposure to mass media due to the Internet and the World Wide Web. A large number of Iranian adults are seeking orthodontic treatment and orthognathic surgery; their perception of the facial profile and esthetic results of treatment has changed (4,5). The effect of the midface on esthetics is apparent

(6) and evaluation of anteroposterior position of the lips in orthodontic diagnosis and treatment planning is critical. As a general rule, we need to determine standard norms for Iranians prior to orthodontic treatment and orthognathic surgery like other ethnic groups (i.e. Middle Eastern, Korean (6-8), Japanese (9-12), Turkish (13, 14) Indian (15), Saudi Arabian (16), Chinese (17), Brazilian(18) and Croatian populations(19). Nevertheless, limited data on established cephalometric soft tissue norms for Iranian adults have been published. Only three studies were found on soft tissue features of Iranians (3,20-22).The aim of our study was to evaluate the midfacial soft tissue profile of the face in Iranian adults using Ricketts esthetic line, Tweed-Merrifield and Holdaway line analyses. Differences between males and females in this respect were also investigated.

### Methods:

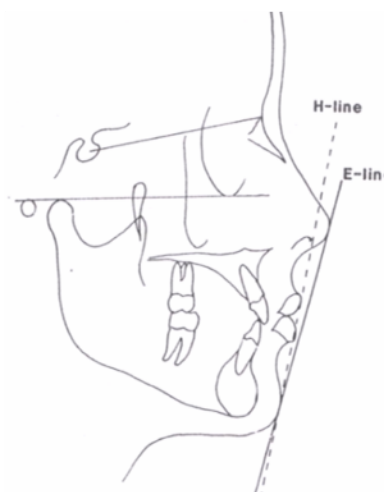
In this study, after clinical examination of 180 dental students, we selected 70 Iranian subjects (35 males and 35 females) with a mean age of 24.5 years (range 21-29 years). Informed consent was taken from all of them. Lateral cephalograms were taken in the NHP at one center and all with the same cephalometric unit (Planmeca Proline EC, Helsinki, Finland, PM-2002, 80 kVp and 25 Ma/ Sec).

The inclusion criteria were:

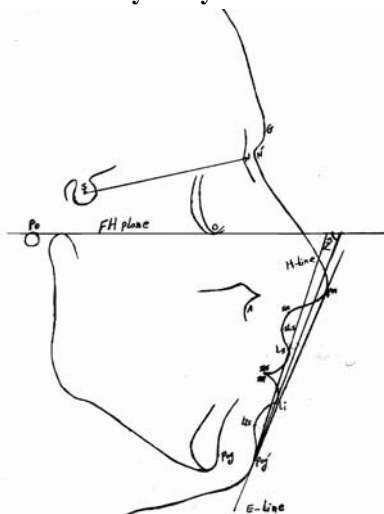
- 1-Iranian with Iranian parents.
- 2-Harmonic profile with normal competent lips.
- 3-CL I molar and canine relationship without crowding in the lower anterior teeth.
- 4-Normal overjet and overbite.
- 5-No history of orthodontic or prosthodontic treatment.
- 6-No history of maxillofacial surgery except for third molar surgery.
- 7-No history of rhinoplasty or other surgery of the face.

Lateral cephalograms were taken in NHP with lips in repose and the teeth in maximum intercuspation. Cephalometric tracing was done

on acetate tracing paper (8×10 inches 0.003 inch thick- Ortho Organizer Co., California, USA). Cephalometric tracing was done by hand and by one person and controlled by another. All measurements were controlled two weeks later for precise determination of landmarks and planes. Anteroposterior evaluation of the lips and facial profile was done via three reference lines namely the Esthetic-line of Rickett's, profile-arch of Hold away and Z-angle of Tweed-Merrifield. Three angular and two linear measurements were made on each cephalogram. The planes are shown in Figure 1 and angular and linear measurements are shown in Figure 2.



**Figure 1-Esthetic-line of Ricketts (E-line) and H-line in Holdaway analysis of soft tissue profile**



**Figure 2-Reference lines used for cephalometric analysis of Iranian subjects: H-line, esthetic line of Ricketts and Z-line**

**Z-Merrifield angle:**

In profile view, a line was drawn in contact with Pog' to the most prominent point of the upper or lower lip (that was more anterior). The angle between this line and the Frankfort horizontal line is named the Z-Merrifield angle. The range is 80-90 degrees. In an ideal profile, the upper lip must be in contact and the lower lip either in contact or behind this line.

**Holdaway ratio or H-line angle:**

This angle is formed between the soft-tissue facial line (N'-Pog') and the H-line (a line tangent to the Pog' and Ls). This angle shows skeletal convexity at point A and prominence of the upper lip and position of the chin point. The mean range of this angle varies between ethnic groups and is 7 to 15 degrees according to the skeletal convexity at point A.

**Anatomical landmarks:**

**N'**(soft tissue nasion): The point of greatest concavity in the midline between the forehead and the nose.

**Pn** (pronasal): The most prominent or anterior point of the nose (tip of the nose).

**Ls** (labi superior): A point indicating the mucocutaneous border of the upper lip, usually the most anterior point of the upper lip.

**Li** (labi inferior): The median point on the lower margin of the lower lip.

**Pog'** (soft tissue pogonion): The most prominent or anterior point on the soft tissue chin in mid sagittal plane.

**Po** (porion): The highest point on the upper margin of the external cutaneous auditory meatus.

**Or** (orbitale): The lowest point on the lower margin of each orbit.

**FH** (Frankfort horizontal line): The line connecting Po and Or.

The mean (and standard deviation) of each

measurement was calculated with SPSS 16. For comparison of data with standards, the One-Sample-t-test and for comparison of measurements between groups, Independent Sample-t-test was used.

**Results:**

This study aimed to assess the middle third facial soft tissue profile of Iranian adults using Ricketts, Tweed- Merrifield (Z-angle) and Holdaway (H-angle) analyses in males and females. Methodological cephalometric tracing errors were assessed with Dahlberg formula (24) on 15 pairs of measurements randomly selected from all observations. The errors ranged from 0.2 to 0.22 for angular cephalometric measurements and from 0.1 to 0.22 mm for linear measurements (Table 1).

**Table 1- Methodological cephalometric tracing errors with Dahlberg formula**

Parameters	Dahlberg values
Ls to E-plane	0.228
Li to E-Plane	0.1
Z-angle	0.228
H-angle	0.202

Our findings in this study showed significant differences between Iranian samples and standard tables with regard to lip position in relation to the esthetic Rickett's line. The upper lip was in a more retruded position ( $p < 0.001$ ) as was the lower lip ( $p < 0.01$ ). According to Tweed Merrifield analysis, the Z angle had significant differences and the chin point was in more retruded position ( $p < 0.001$ ). H-angle in Holdaway analysis was smaller than normal ( $p < 0.001$ ) (Table 2).

Reference lines were:

**E-line or esthetic line:**

A line connecting the tip of the nose (pn) and the most anterior point of the soft tissue chin (pog'); the lower lip in white individuals should fall

approximately 1 to 2mm and upper lip 4mm behind the E-line (23). There was no significant

difference between males and females in these parameters (Table3).

**Table 2- The mean (and standard deviation) values according to the Ricketts, Tweed-Merrifield and Holdaway analyses**

Ricketts analysis	Iranian Samples					Standard Samples		
	mean	SD	Range	Min	Max	mean	SD	p
Upper lip to E-line	-5.72	2.04	9.00	-11.00	-2.0	-4.00		$p<0.001$
Lower lip to E-line	-2.52	-2.73	11.50	-9.00	2.5	-2.00	0.60	$p<0.01$
Tweed-Merrifield analysis	73.58	6.09	25.00	60°	85°	80° (9)		$p<0.001$
Z-angle								
Haldaway analysis	14.9	3.33	14.00	8.00	22.0	(10) 7-15°	1.00	$p<0.001$
H-angle								

**Table 3-The mean (Standard Deviation) difference between Iranian males and females**

	Normal	Male (n=35)		Female (n=35)		t- value	p- value
	value	mean	SD	mean	SD		
Ls To E-plan	-4	-5.557	1.86	-5.88	2.22	-0.66	(0.506)
Li To E-plan	-2	-2.314	2.40	-2.72	3.05	-0.63	(0.531)
Z-angle	80°	73.02	5.97	74.14	6.25	0.762	(0.449)
H-angle	10° (7-14)	15.21	3.17	14.60	3.50	-0.768	(0.445)

## Discussion:

Today, more adult patients seek orthodontic and orthognathic surgery and thus, it is essential that like other ethnic groups the soft tissue facial norms of the society in question be used for assessments.

In our study, the simple and practical Ricketts esthetic analysis for evaluation of anteroposterior lip position in Iranians was used. After comparing our measurements of soft tissue facial analysis with standard tables, significant differences were noted in lip and chin position; in Iranian adults, there was a more retruded position of upper and lower lips in relation to E-line, similar to the findings of a study in northwest of Iran (21). Measurement of Z-angle in Tweed-Merrifield analysis and H-angle in

Holdaway analysis showed that anteroposterior chin position of Iranian samples was more retruded than white norms and had more convex profile compared to a similar study on Iranians in Dubai (3), another study on Iranian females (20) and a study in Mashhad (21). A study of Iranian children who lived in the USA by Hajighadimi in 1981 using Steiner's analysis for hard tissue cephalometric evaluation(22) and findings of Farahani on Iranian adolescents(26) showed that there was a more retruded position of the chin and convexity in the Iranian facial profile; these results were similar to those of a study on Turkish adults(13,14). A study from Japan by Alcalde found a more convex profile but with more protruded lips in Holdaway analysis (9). Another study on Korean adults in contrast to our study showed that Koreans had a

larger H-angle than normal (7). We must consider these differences in orthodontics and orthognathic surgery.

In Saudi Arabia, another study on soft tissue facial profile showed that Arabs had a more convex profile than normal and steeper mandibular plane angles (16). In Chinese, the Holdaway analysis showed less nose prominence and less soft tissue chin thickness as well as more protrusion of the upper and lower lips in Ricketts analysis (17) in contrast to our findings. In a study on facial soft tissue in Brazilians less convexity of the facial profile and more retruded position of the lips compared to standard norms were noted (18). In Holdaway analysis on Croatians there was more protruded lower lip position in females and no difference in position of the upper lip (19).

### **Conclusion:**

According to the Ricketts, Tweed-Merrifield and Holdaway analyses, Iranian adults in our study had more retruded upper and lower lip positions and more convex profiles than white standard

### **References:**

1. Sarver DM, Johnston MW. Radiographic cephalometry from Basics to 3-D Imaging .2<sup>nd</sup> Ed. Chicago: Quintessence Publishing Co. 2006; Chap 20:219-231.
2. Kalha AS, Latif A, Govardhan SN. Soft tissue cephalometric norms in a South Indian ethnic population. Am J Orthod Dentofacial Orthop 2008; 133: 876-881.
3. Taki AA, Oguz F, Abuhijleh E. Facial soft tissue values in Persian adults with normal occlusion and well-balanced faces. Angle Orthod 2009; 79:491-494.
4. AL-Gunaid T, Yamada K, Yamaki M, Saito I. Soft-tissue cephalometric norms in Yemeni men. Am J Orthod Dentofacial Orthop 2007; 132:576.e7-14.
5. Czarnecki ST, Nanda RS, Currier GF. Perceptions of a balanced facial profile. Am J Orthod Dentofacial Orthop 1993; 104: 180-187.
6. Ioi H, Shimomura T, Nakata SH, Nakasima A, Counts AL. Comparison of anteroposterior lip positions of the most-favored facial profile of Korean and Japanese people. Am J Orthod Dentofacial Orthop 2008; 134: 490-495.
7. Hwang HS, Kim WS, McNamara JA Jr. Ethnic differences in the soft tissue profile of Korean and European-American adults with normal occlusions and well-balanced faces. Angle Orthod 2002; 72: 72-80.

norms.

All of these findings show the importance of considering special characteristics of facial soft tissues and facial profile in ethnic groups for treatment planning in orthodontics and orthognathic surgery. This issue becomes more important when in treatment planning some teeth have to be extracted.

In new orthodontic concepts, soft tissue facial analyses have more importance than hard tissue analyses, and the effect of tooth extraction on anteroposterior position of the lips must be well considered especially in females.

### **Acknowledgements:**

This study was supported by a grant (number ETH-367) from Ahvaz Medical University.

The authors would like to thank the orthodontics department and special thanks to Dr. Moosavi and Dr. Gachkooban for their editorial assistance.

### **Conflict of Interest: "None Declared"**

8. Park IC, Bowman D, Klapper L. Acephalometric study of Korean adults. *Am J Orthod Dentofacial Orthop* 1989; 96: 54-59.
9. Alcalde RE, Jinno T, Orsini MG, Sasaki A, Sugiyama RM, Matsumura T. Soft tissue cephalometric norms in Japanese adults. *Am J Orthod Dentofacial Orthop* 2000; 118: 84-89.
10. Ioi H, Nakata SH, Nakasima A, Counts AL. Comparison of cephalometric norms between Japanese and Caucasian adults in anteroposterior and vertical dimension. *Eur J Orthod* 2007; 29: 493-499.
11. Miyajima K, McNamara JA Jr, Kimura T, Murata S, Iizuka T. Craniofacial structure of Japanese and European-American adults with normal occlusions and well-balanced faces. *Am J Orthod Dentofacial Orthop* 1996; 110: 431-437.
12. Ioi H, Nakata S, Nakasima A, Counts AL. Anteroposterior lip positions of the most-favored Japanese facial profile. *Am J Orthod Dentofacial Orthop* 2005; 128: 206-211.
13. SahinSağlamAM. Holdaway measurement norms in Turkish adults. *Quintessence Int* 2002; 33: 757-762.
14. Basciftci FA, Uysal T, Buyukerkmen A. Determination of Holdaway soft tissue norms in Anatolian Turkish adults. *Am J Orthod Dentofacial Orthop* 2003;123: 395-400.
15. Kalha AS, Latif A, Govardhan SN. Soft tissue cephalometric norms in a South Indian ethnic population. *Am J Orthod Dentofacial Orthop* 2008; 133: 876-881.
16. Al Barakati SF. Soft tissue facial profile of adult Saudis Lateral cephalometric analysis. *Saudi Med J* 2011; 32: 836-842.
17. Lew KK, Ho KK, Keng SB, Ho KH. Soft-tissue cephalometric norms in Chinese adults with esthetic facial profile. *J Oral Maxillofac Surg* 1992; 50: 1184-9: discussion 1189-1190.
18. Scavone H, Zahn-Silva W, do valle-Corotti KM, Nahás AC. Soft tissue profile in white Brazilian adults with normal occlusions and well-balanced faces. *Angle Orthod* 2008; 78: 58-63.
19. Anić-Milošević S, Lapter-Varga M, Dumancic J, ŠljajM. Analysis of the soft tissue profile in Croatians with normal occlusions and well-balanced faces. *Eur J Orthod* 2011; 33: 305-310.
20. Mafi P, Ghazisaeidi MR, Mafi A. Ideal soft tissue facial profile in Iranian females. *J Craniofac Surg* 2005; 16: 508-511.
21. Poosti M, Ramezanzadeh B, Salehi T, Rashed R. Retrospective evaluation of facial soft tissue cephalometric parameters in adolescents with normal occlusion. *Int J Orthod Milwaukee* 2010; 21: 15-18.
22. Hajighadimi M, Dougherty HL, Garakani F. Cephalometric evaluation of Iranian children and its comparison with Tweed's and Steiner's standards. *Am J Orthod* 1981;79: 192-197.
23. Jacobson A, Vlachos CH. Radiographic cephalometry from Basics to 3-D Imaging. 2<sup>nd</sup> Ed. Chicago: Quintessence 2006; Chap19: 212-214.
24. Dahlberg G. Statistical methods for medical and biological students. 1<sup>st</sup> Ed. London: Allen &Unwin Ltd. 1940; Chap 21: 217-222.
25. Nouri M, AsgharpourBazkiaei Z. Soft tissue cephalometric norms of 9 to 11 years old children in Qazvin. *JQUMS* 1999; 9: 10-23. [Persian]
26. Farahani M, Seifi M, Eslami Y. A comparison of cephalometric standards of Iranian and American Caucasian adolescents. *J Dent Sch* 2004; 22: 455-501. [Persian]