

The Perceptibility Curve Test Applied to CCD and Two Methods of Digitization of Dental Film-based Radiographs

¹Sima Nikneshan¹ Behrang Moghaddamzade^{*2}

¹Dept. of Oral & Maxillofacial Radiology, school of Dentistry, Shahid Beheshti University of Medical Sciences, Tehran, Iran.

²Dept. of Oral & Maxillofacial Radiology, school of Dentistry, Tehran University of Medical Sciences (International Campus), Tehran, Iran.

Abstract

Objectives: Several methods of image acquisition are accessible in dentistry. There is no overall acceptable method for image digitization so all different types of images can be comparable. The objective of this study was to compare the diagnostic accuracy of different methods of image digitization.

Methods: This accuracy diagnostic test study used perceptibility curve test which first introduced by de Balder was applied. In this test a test object is used which is usually made by aluminum. Different levels of thickness and number of holes in the test object were necessary to have different levels of contrast. Images from film and CCD and digitized images by means of CCD scanners and digital camera were prepared. Nine observers assessed the images. Data collected was delivered to SPSS 13 software and for each image acquisition method, interclass correlation coefficient was computed and compared to the gold standard.

Results: Mean sensitivity, specificity, positive and negative likelihood ratios in dependence on material thickness and the background gray value were calculated. In regions of high optical density the sensitivity for the film images was highest (0.994) following by CCD (0.905), scanner (0.889) and camera (0.821). Difference between CCD images and scanner images was not significant. In dark regions of no dark holes the sensitivity was highest for film images (0.832) following by CCD (0.798), camera (0.714) and scanner (0.615). Difference between film and CCD images was not significant.

Conclusion: The diagnostic quality of radiographic films was better than digital CCD sensors. For digitizing analog images scanners were better than digital cameras.

Key words: Dental, Digital, Radiography, ROC Curve

How to cite:

Nikneshan S, Moghaddamzade B. The perceptibility curve test applied to CCD and two methods of digitalization of dental film-based radiographs. *J Dent Sch* 2016; 34(1): 44-50.

Corresponding Author:
Moghaddamzade B.
Email:
behrangmoghaddamzade@gmail.com

Received: 23.06.2015
Accepted: 24.02.2016

Introduction

After introduction of digital radiography into dentistry several methods of image acquisition were accessible in the field of dentistry.

Direct digital images are widely obtained directly by CCD/CMOS or PSP sensors.

But in many instances such as insurance affairs and communication between dentists or dentists and patients they have to make

digital images from former analog films, which we call it indirect method of digitization and is widely done by digital cameras or CCD-based flat scanners (1).

Overall, digital cameras are used widely in dental clinics. Using digital cameras has too many advantages such as low price, wide accessibility and ease of use.

One of the most important characteristics of digital cameras is the resolution which is showed by megapixels. Practically digital

cameras are faster than scanners because the speed of scanners is related to the resolution which is selected by the user before scanning and using select higher resolutions takes much more time and vice versa (2).

In this article the diagnostic accuracy of different methods of image digitization was compared.

Methods

Perceptibility curve test

This study was an accuracy diagnostic test study. Perceptibility curve test first introduced by de Balder and colleagues in 1971. This test is a simple way to assess the details of a radiographic image which is acquiesced by means of different methods of image acquisition. In this test a test object is used which is usually made by aluminum. Different levels of thickness are necessary and there are a number of holes in the test object to have different levels of contrast.

Minimum thickness should not exceed 7mm and the distance between holes is about 10-30 microns.

Images are acquiesced by different levels of exposure parameters and in this test there should be observers to see the lowest perceptible details in image. The number of the holes each observer can see is the lowest perceptible points. Exposure parameters then will be calculated by means of test object application.

This test is widely used to perceive physical parameters of radiographic systems such as dose-response, functions modulation transfer, function signal-noise ratio, etc. which are affected by the characteristics of

an observer's clinical diagnosis in interpretation (3).

Test object

An aluminum step wedge (24mm*30mm) with 6 steps of different thickness (3-8mm) was prepared.

18 holes with different depths (0.005-0.30 mm) and diameter of 1mm were inserted into different steps (Figure 1).




Figure 1- An aluminum test object containing 18 holes

Each step divided into four rectangular compartments (6mmx5mm) so in each step there were four rectangular parts and three of them included a hole in different random areas and not touching the borders.

All holes were inserted by a computerized drilling machine (Chiron-Werke GmbH & Co.KG /Tuttlingen /Germany).

To achieve same radiopacities in each level an aluminum with 99 percent of density was used to be exposed as same as geometric clinical situation.

The tube distance to the test object was 400 mm. Central ray was perpendicular to the test object. All images was made by a (Kodak-Carestream 2100, Rochester NY USA) intraoral radiographic system.

Intraoral radiographic films (Kodak, Ektaspeed plus, Rochester NY) and CCD sensors (Planmecca dixi, Helsinki, Finland) were used. Pixel size was 0.0039 mm. Images were prepared in different exposure parameters and in a pilot study the best images due the contrast and density chose by

writers. Exposure parameters were comparable to clinical parameters.

The selected radiographs were digitized by a CCD-based scanner (Microtek, Scanmaker, i800, Hsinchu, Taiwan) with maximum resolution of 300dpi. The scanner surface was totally covered by a dark thick paper except step wedge area. Then the radiographic film within the dark thick cover was placed on a negatoscope (view box) and with a digital camera (Canon sx10, Canon Inc, Tokyo, Japan)

images with resolution of 2048x3648 were achieved.

The images of CCD sensor, camera and scanner converted to Tiff format and transferred to PowerPoint (PowerPoint 2007, Microsoft Corporation, Redmond, WA, USA) and one image showed to observers in a 15 inch laptop. (Sony corporation, Vaio, VGN-N250E) with 1024x768 pixels resolution in a semi dark room and to observe the radiographic film the monitor used as the negatoscope (view box) (Figure 2).




Figure 2- Images from CCD, Scanner digital camera and radiographic film from left to right

Nine observers which all were residents of oral and maxillofacial radiology were observed all images in five levels of confidence:

- 1- A dark spot is observable
- 2- A dark spot is probably observable
- 3- The observer is not confident about seeing a dark spot
- 4- A dark spot is probably not observable
- 5- A dark spot is not observable

All observations done in two sessions with an interval time of one month. There were no time limit for observations but the average time was 15 minutes.

All data's collected from observers delivered to SPSS software (SPSS 13.0, Chicago, IL, USA) then for each image acquisition method interclass correlation coefficient (ICC) was computed and compared to the gold standard.

Results

Mean sensitivity, specificity, positive and negative like hood ratios in dependence on material thickness (steps) and the background gray value were calculated.

In regions of high optical density (dark images, low gray value in background) the sensitivity for the film images was highest (0.994) following by CCD (0.905), scanner (0.889) and camera (0.821). Difference between CCD images and scanner images was not significant ($P > 0.05$) (Figure 3).

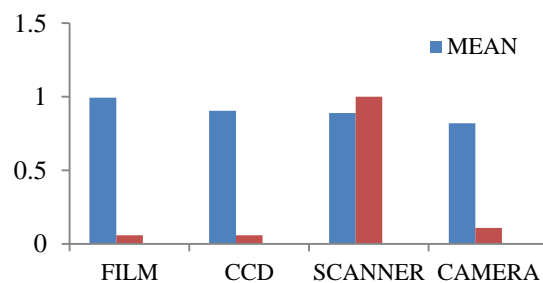


Figure 3- The sensitivity for high optical density areas.

In dark regions of no dark holes the sensitivity was highest for film images (0.832) following by CCD (0.798), camera (0.714) and scanner (0.615) Difference between film and CCD images was not significant. ($P > 0.05$) (Figure 4).

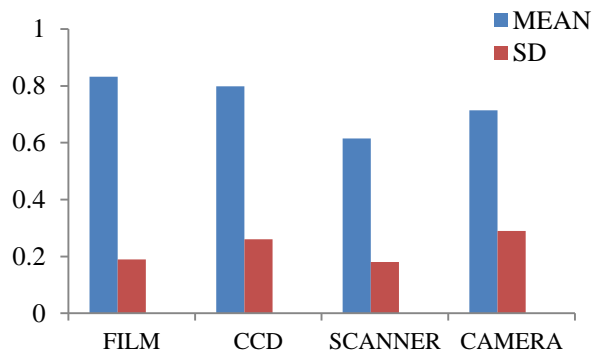


Figure 4- The sensitivity for areas not containing dark holes

About the total agreement between observers comparing to gold standard the results were highest for film images (0.895) following by CCD (0.824), camera (0.754) and scanner (0.750). The difference between camera and scanner was not significant. ($P > 0.05$) (Figure 5).

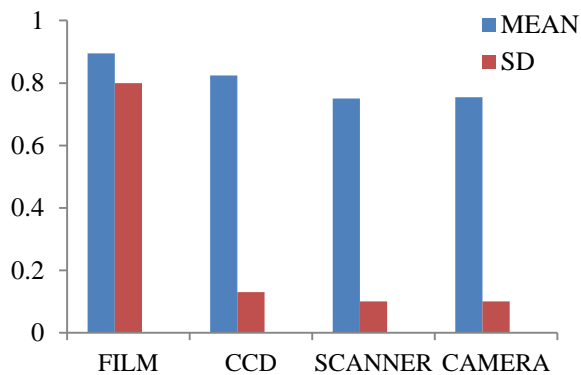


Figure 5- Total agreement between observers

The intra-observer and inter-observer reliability was highest in the field of CCD 83%, scanner 79%, film 75% and camera 62%.

At last receive operating characteristic analysis was performed for each observer and all observations per modality (SPSS 10.0.5, SPSS Inc., Chicago, IL, USA). The areas beneath ROC curves (AZ values) were compared using the paired Wilcoxon test. The confidence ratings for all images were averaged over all observers and both observations to produce mean ROC curves for each modality (Figure 6). Film images and CCD images was much more reliable than their digital counterparts.

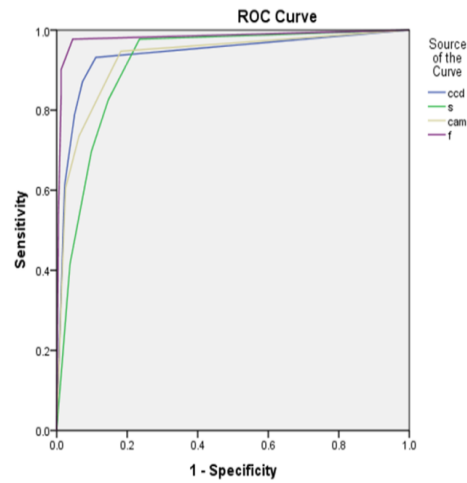


Figure-6 ROC curves

Discussion

The purpose of this study was comparing the diagnostic accuracy of different methods of image digitization. Despite too many studies has been performed on evaluating digital images' criteria and comparing them with film based images (4-8) there are a few studies focused on different methods of digitization and each one's pros and cons.

The perceptibility of low contrast objects on a test object is related to proximal caries diagnosis. Exposure parameters in current study was in normal range of clinical parameters (60-90kVp) so by means of standardization the observation conditions and test object you can compare the diagnostic accuracy of different methods of imaging (9) Digitalization process of an analog film was made by a CCD-based scanner with 300 dpi (359x285) which keep the balance between the volume of information and diagnostic information (10-11).

An *invitro* study (2001) showed that there is no significant difference between 300 dpi and 600 dpi digital images (12) Another problem we had was how to show a 300 dpi image in a monitor with 1024x768 resolution. So the scanner images had to magnify 7.7 times to be the same size as CCD images (861x1201) and digital camera (1166x920) on the computer's monitor.

Versteeg and colleagues (1997) showed only if you make digital images smaller the diagnostic information may be lost and if you magnify them they won't be affected (13).

In current study images from film and CCD were better for diagnosing low contrast objects than scanner and camera. It was the same as other studies (5, 14-16).

In this study digitized images from scanner and digital camera had more density than film and CCD images.

After increasing the density the latitude will be decreased and the contrast will be increased so the overall quality of the image will be less than film and CCD. In other studies same results had figured out (17-20).

Hangiandreou *et al.* (1998) figured out that scanners do not make diagnostic images because they decrease latitude (11). Shulze *et al.* (14) showed scanners do not make diagnostic images especially in darker areas.

We used Tiff format in PowerPoint program for image observation because they are widely used in teaching and telecommunications. And we used a 1024x768 monitor which is available in so many dental clinics (2).

The result of current study does not verify other studies in the field of digital cameras.

Davidson *et al.* (21) figured out digital cameras are not valid enough for digitalizing radiographic films. In that study the observers assessed the image quality subjectively not objectively by means of a step wedge.

Conclusion

The diagnostic quality of radiographic films was better than digital CCD sensors. And for digitizing analog images scanners are better than digital cameras.

Conflict of Interest: "None Declared"

References:

1. Grassl U, Schulze R KW. In vitro perception of low-contrast features in digital, film, and digitized dental radiographs. *Oral Surg Oral Med Oral Pathol Oral Radiol Endod.* 2007 May;103(5):694-701.
2. Prapayasadok S, Janhom A, Verochana K, Pramojanee S. Digital camera resolution and proximal caries detection. *Dentomaxillofacial Radiology.* 2006; 35:253-7.
3. Farman AG, Farman TT. A comparison of 18 different x-ray detectors currently used in dentistry. *Oral Surg Oral Med Oral Pathol Oral Radiol Endod.* 2005 Apr ;99(4):485-9.
4. Borg E, Grondahl K, Grondahl HG. Marginal bone level buccal to mandibular molars in digital radiographs from charge-coupled device and storage phosphor systems. An in vitro study. *J Clin Periodontol.* 1997 May ; 24(5):306-12.
5. Mistak EJ, Loushine RJ, Primack PD, West LA, Runyan DA. Interpretation of periapical lesions comparing conventional, direct digital and telephonically transmitted radiographic images. *J Endod.* 1998 Apr ; 24(4):262-6.
6. Nikneshan S, Abbas FM, Sabbagh S. Detection of proximal caries using digital radiographic systems with different resolutions. *Indian J Dent Res.* 2015 May;26(1): 5-10.
7. Vasconcelos TV, Santaella GM, Nascimento HA, Rovaris K, Ambrosano GM, Freitas DQ. Digital radiographs displayed on different devices: effect on the detection of vertical root fractures. *Int Endontic J.* 2016; 49(4): 386-92.
8. Nascimento HA, Neves FS, de-Azevedo-Vaz Duque TM3, Ambrosano GM, Freitas DQ. Impact of root fillings and posts on the diagnostic ability of three intra-oral digital radiographic systems in detecting vertical root fractures. *Int Endod J.* 2015 Sep;48(9):864-71.
9. Yoshiura K, Stamatakis H, Shi XQ, Welander U, McDavid WD, Kristofferson J, et al. The perceptibility curve test applied to direct dental digital radiography. *Dentomaxillofac Radiol.* 1998; 27:131-5.
10. Attaelmanan A, Borg E, Grondahl HG. Digitization and display of intraoral films. *Dentomaxillofac Radiol.* 2000 Mar;29(2):97-102.
11. Hangiandreou NJ, O Connor TJ, Felmlee JP. An evaluation of the signal and noise characteristics of four CCD-based film digitizers. *Med Phys.* 1998 Oct;25(10):2020-6.

12. Janhom A, van Ginkel FC, van Amerongen JP, van der Stelt PF. Scanning resolution and the detection of proximal caries. *Dentomaxillofacial Radiology*. (2001);30;166-71.
13. Versteeg CH, Sanderink GC, Geraets WG, Van der Stelt PF. Impact of scale standardization on images of digital radiography systems. *Dentomaxillofac Radiol*. 1997 Nov;26(6):337-43.
14. Schulze RK, Rosing ST, D Hoedt B. Contrast perception in digitized panoramic radiographs compared with their film-based origin. *Oral Surg Oral Med Oral Pathol Oral Radiol Endod*. 2002 Sep;94(3):338-94.
15. Haak R, Wicht MJ, Noack MJ. Conventional, digital and contrast-enhanced bitewing radiographs in the decision to restore proximal caries lesion. *Caries Res* 2001;35(3):193-9.
16. Fuge KN, Stuck AM, Love RM. A comparison of digitally Scanned radiographs with conventional film for the detection of small endodontic instruments. In *Endod J*. 1998 Mar;31(2):123-6.
17. Syriopoulos K, Sanderink GC, Velders XL, Van der Stelt PE. Radiographic detection of approximal caries: a comparison of dental films and digital imaging systems. *Dentomaxillofacial Radiology*. 2000;29,312-8.
18. Yoshiura K, Kawazu T, Chikui T, Tatsumi M, Tokumori K, Tanaka T, et al. Assessment of image quality in dental radiography, part 1: phantom validity. *Oral Surg Oral Med Oral Pathol Oral Radiol Endod*. 1999;87(1):115-22.
19. Parissis N, Kondylidou-Sidira A, Tsirlis A, Patias P. Conventional radiographs vs digitized radiographs: image quality assessment. *Dentomaxillofac Radiol*. 2005 Mar;34(6):353-6.
20. Shrout MK, Potter BJ, Yurgalavage HM, Hildebolt CF, Vannier MW. 35-mm film scanner as an intraoral dental radiograph digitizer I : A quantitative evaluation. *Oral Surg Oral Med Oral Pathol*. 1993 Oct;76(4):502-9.
21. Davidson HC, Johnston DJ, Christian ME, Harnsberger HR. Comparison of radiographic image quality from four digitization devices as viewed on computer monitors. *J Digit Imaging*. 2001 Mar;14:24-29.