

Diagnostic Accuracy of CT Scan for Detection of Cervical Lymph Node Metastasis in Oral Squamous Cell Carcinoma in Comparison with Histopathological Analysis After Neck Dissection

¹Hassan Mirmohammad Sadeghi¹ Alireza Pournabi^{*1} Mahshid Namdari²

¹Dept. of Oral & Maxillofacial Surgery, School of Dentistry, Shahid Beheshti University of Medical Sciences, Tehran, Iran.

²Dept. of Community Oral Health, School of Dentistry, Shahid Beheshti University of Medical Sciences, Tehran, Iran.

Abstract

Objectives: Presence/absence of cervical lymph node metastasis plays a critical role in prognosis and survival of patients with oral squamous cell carcinoma (SCC). This study was designed to assess the diagnostic accuracy of computed tomography (CT) scan for detection of cervical lymph node metastasis in oral SCC in comparison with histopathological analysis after neck dissection.

Methods: In this retrospective cross-sectional study, pathology and CT reports of 50 patients with oral SCC were retrieved from the archives of Taleghani and Shariati Hospitals and data regarding the site of involvement, lymph node metastasis, level of cervical involvement and size of involved lymph node were retrieved from patient files. The results of CT scan and pathology reports were compared and the accuracy, sensitivity, specificity, positive predictive value (PPV) and negative predictive value (NPV) of CT scan were calculated compared to the gold standard (pathology report). Basic statistics was used for analyze the data.

Results: The sensitivity of CT scan for detection of metastatic cervical lymph nodes was 69.23% compared to the pathology report (gold standard). The specificity, PPV and NPV were 27.02%, 25% and 71.42%, respectively. The diagnostic accuracy of CT scan was 38%.

Conclusion: Based on the results, CT scan is not reliable for detection of metastatic cervical lymph nodes in oral SCC, and more advanced techniques may be indicated for assessment of cervical lymph node involvement and deciding on the most efficient surgical approach in patients with oral SCC.

Key Words: Carcinoma, Lymph Nodes, Neck Dissection, Pathology; Squamous cell of head and neck

How to cite:

Mirmohammad Sadeghi H, Pournabi A, Namdari M. Diagnostic Accuracy of CT Scan for Detection of Cervical Lymph Node Metastasis in Oral Squamous Cell Carcinoma in Comparison with Histopathological Analysis After Neck Dissection. J Dent Sch 2016; 34(2): 90-9.

*Corresponding Author:

Pournabi A.

E-mail: drapournabi@gmail.com

Received: 04.04.2016

Accepted: 14.06.2016

Introduction

Oral cancer is the sixth most common cancer causing mortality worldwide and SCC is the most common type of oral cancer. Presence/absence of cervical lymph node metastasis plays a critical role in prognosis and survival of patients with oral SCC (1-5). Oral SCC is curable if diagnosed early and managed properly. However, OCLNM is the most common cause of oral SCC treatment failure. The prevalence of cervical lymph node metastasis in oral SCC has reported to be 34-50% (6). Tumor penetration depth is

the most important predictor of recurrence in the neck and patients with tumor penetration depth of more than 2mm have four times the risk of cancer recurrence (7,8). Oral SCC can occur in the oral mucosa or the tongue; SCC of the tongue has a lower survival rate compared to other types (6-8). Lymph node metastasis of the buccal SCC is lower than that of SCCs of other parts of the oral cavity (9,10). Buccal SCC has a relatively high recurrence as well (4,6,8).

Oral SCC most commonly metastasizes to the first, second, third, fourth and fifth layers of the neck, respectively and the frequency

of metastasis to level 4 varies from 3 to 28% depending on the location of the primary tumor (11,12). It has been well documented that oral SCC has a high prevalence of lymph node metastasis and patients with T1 (tumor smaller than 2cm in its largest dimension), T2 (tumor between 2-4cm in size in its largest dimension) and N0 (clinically undetectable lymph nodes with axial dimension ≤ 10 mm, radiographically undetected lymph nodes or axial lymph nodes without central necrosis) oral SCC have 19-46% and 35-57% prevalence of OCLNM, respectively revealed during surgery. If not managed properly, patients develop tumor recurrence in the neck, which has a high rate of mortality (7, 13-15). Presence of OCLNM in SCC of the tongue is an important prognostic factor and patients with cervical lymph node involvement (N+) must undergo neck dissection; however, neck dissection in patients with N0 is still a matter of debate (16,17). Risk of OCLNM of oral SCC is about 20% and it is the most important indication of selective neck dissection.

Accurate imaging can decrease the risk of undetected OCLNM (18). Computed tomography is an efficient method for assessment of cervical lymph node metastasis (19). The criteria for a metastatic lymph node on a CT scan is size larger than 11mm or hypodensity at the center associated with a reinforced rim or presence of three or more lymph node masses (20,21). In palpation, the criteria for a metastatic lymph node include a hard sessile lymph node larger than 10mm. It has been shown that level 2 is the most common and level 4 is the least common neck involvement, and level 4 involvement without one of the more superficial layers has not been reported (6).

Another study showed an association between OCLNM and tongue SCC and the highest prevalence was seen in levels 2, 3, 1 and 4 of the same side, respectively. Thus, supra omohyoid neck dissection (SOHND) is indicated in such cases (22) since neck dissection is the modality of choice for treatment of oral cancer metastasis.

Considering the importance of early detection and prompt management of OCLNM in oral SCC, this study sought to compare the pathology and CT scan reports of cervical lymph node metastasis of oral SCC following neck dissection.

Methods

This retrospective cross-sectional study was conducted on 50 oral SCC patients in Taleghani and Shariati Hospitals. Sample size was calculated to be 50 patients according to previous studies (23,24) and considering a confidence limit of 95% and accepting a difference of up to approximately 25% of the true value with %40 proportion of metastatic cervical lymph nodes using the Kappa Size package in R 3.2.3 software. Thus, 50 patients who underwent neck dissection due to oral SCC from 2007 to 2016 were selected using convenience sampling and their hospital records were retrieved from the archives. Their pathology reports and CT findings (provided by expert and experienced pathologists and radiologists) were evaluated and the extracted data were recorded in a checklist. Presence or absence of metastasis in the biopsy sample, level of cervical lymph node involvement and size of lymph nodes were retrieved from the pathology report of patients. Presence of lymphadenopathy and level of cervical

involvement were evaluated on CT scans as well. All CT scans of the neck had been taken with the same X ray unit (Activion 16, Toshiba, Japan) from the base of the skull to the clavicle with 5mm sections and the same surgeon had performed all surgical procedures. The criteria for a metastatic lymph node in our study was minimal axial diameter >11mm or nodes with central hypodensity and peripheral rim enhancement or conglomeration of three or more lymph nodes (25,26).

After filling out the checklist, the sensitivity, specificity, PPV, NPV and accuracy of CT scan for detection of cervical lymph node involvement were calculated as follows and compared with the gold standard, that was the pathology report of patients.

Sensitivity referred to how well positive lymph nodes were detected by CT scan and was calculated as
$$\frac{\text{True positive}}{\text{True positive} + \text{false negative}}$$

Specificity referred to how well negative lymph nodes were distinguished from intact nodes by CT scan and was calculated as
$$\frac{\text{True negative}}{\text{True negative} + \text{false positive}}$$

Accuracy referred to how well CT scan functioned with respect to detection of involved nodes and calculated as
$$\frac{\text{True positive} + \text{true negative}}{\text{Total}}$$

The PPV referred to the probability of a positively diagnosed node being actually positive and was calculated as
$$\frac{\text{True positive}}{\text{True positive} + \text{false positive}}$$

The NPV referred to the probability of a negatively diagnosed lymph node being actually sound and calculated as
$$\frac{\text{True negative}}{\text{True negative} + \text{false negative}}$$

The data were entered into SPSS version 16 and the mean, standard deviation, minimum and maximum values were calculated for the

quantitative variables. For qualitative variables, the frequency of each variable was reported. The kappa coefficient were calculated to assess the agreement between pathological and CT findings.

Result

Of 50 patients, 28 were males (56%) and 22 (44%) were females with a mean age of 62.6 ± 14.26 years (range 33-92 years). The mandible was the most common (19 cases, 38%) and the maxilla was the least common (5 cases, 10%) site of involvement. The tongue, lower lip and buccal mucosa were involved in 24% (n=12), 14% (n=7) and 14% (n=7) of the cases (Figure 1).

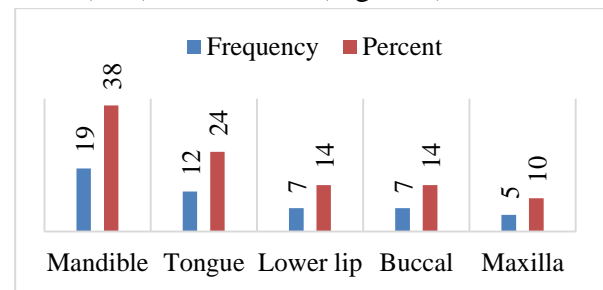


Figure 1- The frequency distribution of the sites of involvement

Of patients, 36 (72%) had positive and 14 (28%) had negative reports for presence of metastatic lymph node involvement in their CT scan report. However, of these patients, only the pathology report of 13 (26%) patients showed metastatic lymph nodes and the pathology report of the remaining 37 patients (74%) was reactive (non-metastatic) lymph node involvement.

Regarding the pre and post-operative staging of cancer (Figure 2), 40% (n=20) were in stage IVa (the highest frequency) and 10% (n=5) were in stage II (lowest frequency). The frequency distribution of patients in different stages of cancer preoperatively and postoperatively is presented in Table 1. In terms of postoperative cancer staging

(Figure 3), most patients (48%, 24 cases) were in stage IVa and the least number of patients were in stages I and III (4%, 2 cases). Level of cervical involvement had not been mentioned in the CT scan report of 14 patients. Level of cervical involvement in the remaining 36 patients based on their CT scan report is presented in Table 2.

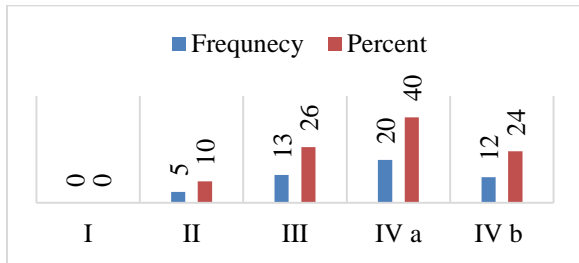


Figure 2- The frequency distribution of preoperative staging of SCC




Figure 3- The frequency distribution of postoperative staging of SCC

Table 1- The frequency distribution of patients based on preoperative and postoperative staging of cancer

	Stage	Frequency	Frequency percentage
Preoperative staging	I	0	0
	II	5	10
	III	13	26
	IVa	20	40
	IVb	12	24
Postoperative staging	I	2	4
	II	14	28
	III	2	4
	IVa	24	48
	IVb	8	16
Total		50	100

Table 2- The frequency distribution of level of cervical involvement based on the CT scan report of patients

Level of cervical involvement based on the CT scan report	Frequency	Percentage
Ia	6	16.7

Ib	11	30.6
II	17	47.2
III	2	5.5
Total	36	100

Level of cervical involvement had not been mentioned in the pathology report of 37 patients. Level of cervical involvement in the remaining 13 patients based on their pathology report is presented in Table 3.

Table 3- The frequency distribution of level of cervical involvement based on the pathology report of patients

Level of cervical involvement based on the pathology report	Frequency	Percentage
Ia	4	30.8
Ib	4	30.8
II	3	23.1
III	2	15.3
Total	13	100

Assessment of level of cervical involvement based on the CT scan report and the pathology report of patients showed that in level Ia, two patients (33.3%) had positive and four (66.7%) had negative results. These values were two (18.2%) and nine patients (81.8%) for level Ib, three (17.6%) and 14 (82.4%) for level II and 100% and 100% for level III, respectively. Accurate diagnosis of level of cervical involvement according to the CT scan in comparison with the pathology report (gold standard) was noted in two patients (18%) with level Ia, one patient (5%) with level IIa and two patients (100%) with level III involvement.

The most common level of cervical involvement was level Ib (41.6%) in the SCC of the mandible, II (83.3%) in the SCC of the tongue, Ib (60%) in the SCC of the buccal mucosa, Ia (66.7%) in the SCC of the lower lip and II (50%) in the SCC of the maxilla (Table 4). Comparison of CT findings with the pathology report (gold standard) is shown in Figure 4. In 60.1%

(n=17) of males, the CT scan report was positive for a metastatic lymph node while this rate was 77.27% (n=17) in females. In 28.57% of males, the pathology report showed metastatic lymph node involvement while this value was 22.72% (n=5) in females. In 25% (n=9) of patients with a positive CT scan report for a metastatic lymph node, the pathology report was also positive (true positive). In 75% (n=27), although the CT scan report was positive, the pathology report was negative (false positive). In 28.6% (n=4), metastatic lymph node was not shown on the CT scan report but their pathology report was positive (false negative). In 71.4% (n=10) both CT scan and pathology reports were negative (true negative). Based on these values, the sensitivity of CT scan for detection of metastatic lymph node involvement based on the pathology report (gold standard) was 69.23% while its specificity was 27.02%, its

PPV was 25% and its NPV was 71.42%. The diagnostic accuracy of CT scan was calculated to be 38%. The calculated kappa statistics was equal to -0.02 (P=0.8), which revealed low agreement between CT and pathological findings.

Figure 4- CT findings in comparison with the pathology report (gold standard)

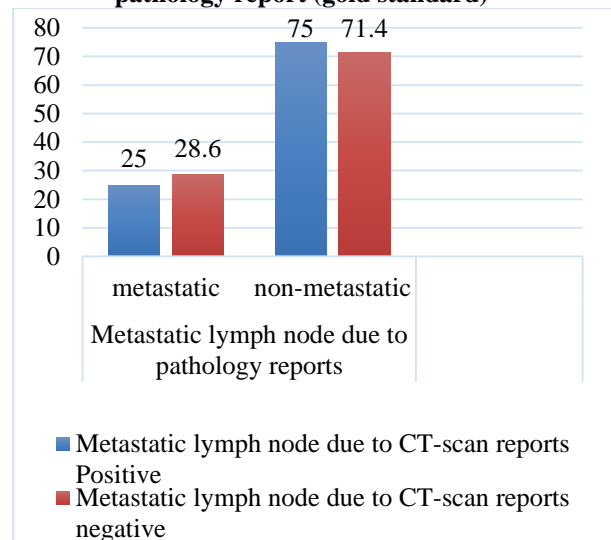


Table 4- The frequency distribution of level of cervical involvement based on the site of oral SCC

		Site of SCC									
		Mandible		Tongue		Buccal mucosa		Lower lip		Maxilla	
Level of cervical involvement in CT scan		Frequen cy	Percenta ge	Frequen cy	Percenta ge	Frequen cy	Percenta ge	Frequen cy	Percenta ge	Frequen cy	Percenta ge
Ia		2	16.7	0	0	1	20	2	66.7	1	25
Ib		5	41.6	2	16.7	3	60	0	0	1	25
II		3	25	10	83.3	1	20	1	33.3	2	50
II		2	16.7	0	0	0	0	0	0	0	0
I											

Discussion

Cervical metastasis is the most important predictor of the prognosis of SCC of the head and neck region (27). Therefore, neck dissection in patients with the head and neck SCC is among the most important steps of treatment. Merritt et al. (28) compared palpation and CT scan and reported the sensitivity and specificity of 75% and 83% for palpation and 81% and 83% for CT scan, respectively. Giancarlo et al. (29) compared

palpation with ultrasound and found no significant difference in their diagnostic accuracy. Kassekh et al. (30) showed that clinical examination at the time of surgery did not help the detection of involved cervical lymph nodes. The accuracy of palpation for detection of cervical lymph node involvement has reported to be 60-80% in the literature (3,5,31). In our study, the results showed that the sensitivity of CT scan for detection of cervical lymphadenopathy was 69.23% based on the

results of the pathology report (gold standard); its specificity, PPV and NPV were 27.02%, 25% and 71.42%, respectively. The diagnostic accuracy of this test was 38%. The low diagnostic accuracy obtained in our study shows that CT scan is not highly reliable for detection of cervical lymph node metastasis or differentiation of metastatic from reactive lymph nodes. Considering the importance of detection of cervical lymph node metastasis and its critical role in the selection of the surgical approach, prognosis and patient survival, alternative methods with higher sensitivity and specificity such as position emission tomography (PET) scan and sentinel node biopsy (SNB) are required for this purpose. However, a previous study showed that PET scan had no superiority over CT for staging of N0 patients (32). Therefore, a future study is recommended to compare the efficacy of PET scan with that of CT scan and SNB for this purpose.

Fakih et al. (33) in a randomized clinical trial showed that tongue SCC had a higher survival rate in patients who underwent neck dissection. Kligerman et al. (7) showed a higher recurrence rate in patients who did not undergo neck dissection. Similarly, our findings showed that neck dissection was appropriate considering the level of involvement of the neck and should be preferably performed. Many of the pre- and post-operative findings were the same in our study and the results showed that the SOHND approach was indicated in many patients.

Shear et al. (34) reported that size of tumor, site of involvement and degree of differentiation were among the main predictors of prognosis. Yamamoto et al. (35) reported that lymphatic metastasis was

the most important predictor of prognosis. Another study showed that OCLNM had no association with tumor dimensions but was correlated with the depth of penetration of tumor. Also, the presence of OCLNM was correlated with histopathological grade and degree of differentiation of lesion. Rate of OCLNM is higher in deep, penetrating lesions followed by the exophytic lesions and metastasis has been more commonly reported in levels 1-3 and SOHND should be performed in such patients (36). Patients with OCLNM have five times the risk of mortality compared to SCC patients without OCLNM. Risk of OCLNM was reported to be 23% in a study by Amarel et al, (37) and 21% in a study by Kligerman et al. (7). In another study, the prevalence of metastasis was 60% in T1, 69% in T2, 100% in T3 and 39% in T4. Oral SCC, especially in the early stages, often invades or metastasizes to cervical lymph nodes (38). Huang et al. (39) concluded that tumor thickness more than 4mm and poor histological grade indicated higher risk of OCLNM. In the current study, risk of OCLNM was 28.6%, which was in agreement with the rates reported in the above-mentioned studies (7,37). Considering the fact that risk of OCLNM increases the morbidity and mortality, selection of the most appropriate diagnostic and treatment modalities can greatly help early management of SCC. Based on the current results and those of previous studies regarding the high prevalence of OCLNM, it seems that in patients with levels 1-3 of cervical involvement with higher risk of OCLNM, risk of distant metastasis can be decreased by performing SOHND. Byers et al. (11) showed that risk of level 4 cervical involvement in the primary tongue cancer was high and extended SOHND (levels 1-4)

was the most appropriate approach in such patients. They concluded that the risk of levels 4 and 5 involvement of the same side and involvement of the other side was relatively low and radiotherapy was effective for levels 1, 2 and 3 of the involved side. They reported that radiotherapy for level 4 of the involved side and levels 1 and 2 of the contralateral side seemed more logical. It should be noted that Byers et al. (11) reported level 4 involvement in 16% of the cases without involvement of more superficial levels. Since the risk of involvement of levels 4 and 5 is low and our results also showed low rate of involvement of levels 4 and 5 as well as the highest rate of involvement seen in levels 1-3, it can be

concluded that SOHND is indicated in patients with oral SCC.

Conclusion

Within the limitations of this study, CT scan was not highly reliable for detection of metastatic cervical lymph nodes in oral SCC and more advanced techniques may be indicated for assessment of cervical lymph node involvement and deciding on the most efficient surgical approach.

Conflict of Interest: “None Declared”

References:

1. Parkin DM, Bray F, Ferlay J, Pisani P. Global cancer statistics, 2002. *CA Cancer J Clin.* 2005 Mar-Apr;55(2):74-108.
2. Hodder SC, Evans RM, Patton DW, Silvester KC. Ultrasound and fine needle aspiration cytology in the staging of neck lymph nodes in oral squamous cell carcinoma. *Br J Oral Maxillofac Surg.* 2000 Oct;38(5):430-6.
3. Sarvanan K, Bapuraj JR, Sharma SC, Radotra BD, Khandelwal N, Suri S. Computed tomography and ultrasonographic evaluation of metastatic cervical lymph nodes with surgicoclinicopathologic correlation. *J Laryngol Otol.* 2002 Mar;116(3):194-9.
4. D’Souza O, Hasan S, Chary G, Hoisala VR, Correa M. Cervical lymph node metastases in head & neck malignancy-a clinical/ultrasonographic/histopathological comparative study. *Indian J Otolaryngol Head Neck Surg.* 2003 Apr;55(2): 90-93.
5. Haberal I, Celik H, Goçmen H, Akmansu H, Yoruk M, Ozeri C. Which is important in the evaluation of metastatic lymph nodes in head and neck cancer: Palpation, Ultrasonography or computed tomography? *Otolaryngol Head Neck Surg.* 2004 Feb;130(2):197-201.

6. Woolgar JA, Rogers S, West CR, Errington RD, Brown JS, Vaughan ED. Survival and patterns of recurrence in 200 oral cancer patients treated by radical surgery and neck dissection. *Oral Oncol.* 1999 May;35(3):257-65.
7. Kligerman J, Lima RA, Soares JR, Prado L, Dias FL, Freitas EQ, et al. Supraomohyoid neck dissection in the treatment of T1/T2 squamous cell carcinoma of the oral cavity. *Am J Surg.* 1994 Nov;168(5):391-4.
8. Asakage T, Yokose T, Mukai K, Tsugane S, Tsubono Y, Asai M, et al. Tumor thickness predicts cervical metastasis in patients with stage I/II carcinoma of the tongue. *Cancer* 1998 Apr;82(8):1443-8.
9. Coppen C, de Wilde PC, Pop LA, van den Hoogen FJ, Merks MA. Treatment results of patients with a squamous cell carcinoma of the buccal mucosa. *Oral Oncol.* 2006 Sep;42(8):795-9.
10. Diaz EM Jr, Holsinger FC, Zuniga ER, Roberts DB, Sorensen DM. Squamous cell carcinoma of the buccal mucosa: one institution's experience with 119 previously untreated patients. *Head Neck.* 2003 Apr;25(4):267-73.
11. Byers RM, Weber RS, Andrews T, McGill D, Kare R, Wolf P. Frequency and therapeutic implications of "skip metastases" in the neck from squamous carcinoma of the oral tongue. *Head Neck.* 1997 Jan;19(1):14-9.
12. Woolgar JA. Detailed topography of cervical lymph-node metastases from oral squamous cell carcinoma. *Int J Oral Maxillofac Surg.* 1997 Feb;26(1):3-9.
13. Kowalski LP, Bagietto R, Lara JR, Santos RL, Silva JF, Magrin J. Prognostic significance of the distribution of neck node metastasis from oral carcinoma. *Head Neck.* 2000 May;22(3):207-14.
14. Keski-Säntti H, Atula T, Törnwall J, Koivunen P, Mäkitie A. Elective neck treatment versus observation in patients with T1/T2 N0 squamous cell carcinoma of oral tongue. *Oral Oncol.* 2006 Jan;42(1):95-100.
15. Lim YC, Lee JS, Koo BS, Kim SH, Kim YH, Choi EC. Treatment of contralateral N0 neck in early squamous cell carcinoma of the oral tongue: elective neck dissection versus observation. *Laryngoscope.* 2006 Mar;116(3):461-5.
16. Montes DM, Schmidt BL. Oral maxillary squamous cell carcinoma: management of the clinically negative neck. *J Oral Maxillofac Surg.* 2008 Apr;66(4):762-6.

17. Huang SF, Kang CJ, Lin CY, Fan KH, Yen TC, Wang HM, et al. Neck treatment of patients with early stage oral tongue cancer: comparison between observation, supraomohyoid dissection, and extended dissection. *Cancer*. 2008; 112: 1066-1075.
18. Atula TS, Grenman R, Varpula MJ, Kurki TJ, Klemi PJ. Palpation, Ultrasound and Ultrasound –Guided Fine Needle Aspiration Cytology in the assessment of cervical lymph node status in Head and Neck cancer patients. *Head Neck*. 1996 Nov-Dec;18(6):545-51.
19. Takashima S, Sone S, Nomura N, Tomiyama N, Kobayashi T, Nakamura H. Nonpalpable lymph nodes of the neck. Assessment with US and US-guided Fine Needle Aspiration Biopsy. *J Clin Ultrasound*. 1997 Jul-Aug;25(6):283-92..
20. Takes RP, Righi P, Meeuwis CA, Manni JJ, Knegt P, Marres HA, et al. The value of ultrasound with ultrasound- guided fine needle aspiration biopsy compared to computed tomography in the detection of regional metastasis in the clinically negative neck. *Int J Radiat Oncol Biol Phys*. 1998 Mar;40(5):1027-32.
21. Righi PD, Kopecky KK, Caldemeyer KS, Ball VA, Weisberger EC, Radpour S. Comparison of Ultrasound- Fine Needle Aspiration and Computed Tomography in patients undergoing elective neck dissection. *Head Neck*. 1997 Oct;19(7):604-10.
22. Hamakawa H, Takemura K, Sumida T, Kayahara H, Tanioka H, Sogawa K. Histological study on pN upgrading of oral cancer. *Virchows Arch*. 2000 Aug;437(2):116-21.
23. Kolokythas A, Park S, Schlieve T, Pytynia K, Cox D. Squamous cell carcinoma of the oral tongue: histopathological parameters associated with outcome. *Int J Oral Maxillofac Surg*. 2015 Sep;44(9):1069-74.
24. Amar A, Curioni OA, Franzi SA, Ortelado DK, Rapoport A. Neck dissection in squamous cell carcinoma of the tongue. *Braz J Otorhinolaryngol*. 2005 Jan-Feb;71(1):29-31.
25. Sarvanan K, Bapuraj JR, Sharma SC, Radotra BD, Khandelwal N, Suri S. Computed tomography and ultrasonographic evaluation of metastatic cervical lymph nodes with surgico-clinicopathologic correlation. *J Laryngol Otol* 2002 Mar;116(3):194–9.
26. Geetha NT, Hallur N, Goudar G, Sikkerimath BC, Gudi SS. Cervical lymph node metastasis in oral squamous carcinoma preoperative assessment and histopathology after neck dissection. *J Maxillofac Oral Surg* 2010 Mar;9(1):42-7.
27. Ferlito A, Rinaldo A, Devaney KO, MacLennan K, Myers JN, Petruzzelli GJ, et al. Prognostic significance of microscopic and macroscopic extracapsular spread from metastatic tumor in the cervical lymph nodes. *Oral Oncol* 2002 Dec; 38(8):747-51.

28. Merritt RM, Williams MF, James TH, Porubsky ES. Detection of cervical metastasis: a meta-analysis comparing computed tomography with physical examination. *Arch Otolaryngol Head Neck Surg.* 1997 Feb;123(2):149-52.
29. Giancarlo T, Palmieri A, Giacomarra V, Russolo M. Pre-operative evaluation of cervical adenopathies in tumours of the upper aerodigestive tract. *Anticancer Res.* 1998 Jul-Aug;18(4B):2805-9.
30. Kassekh CH, Johnson JT, Myers EN. Accuracy of intraoperative staging of the N0 neck in squamous cell carcinoma. *Laryngoscope.* 1995 Dec;105(12 Pt 1):1334-6.
31. Sundar R, Rajesh P. Evaluation of clinical assessment, Ultrasonography and CT for detecting cervical lymph node metastasis in oral CA. *J Maxillofac Oral Surg* 2007; 6(4):70-3.
32. Schöder H, Carlson DL, Kraus DH, Stambuk HE, Gönen M, Erdi YE, et al. 18F-FDG PET/CT for detecting nodal metastases in patients with oral cancer staged N0 by clinical examination and CT/MRI. *J Nucl Med.* 2006 May;47(5):755-62.
33. Fakhri AR, Rao RS, Patel AR. Prophylactic neck dissection in squamous cell carcinoma of oral tongue: a prospective randomized study. *Semin Surg Oncol.* 1989;5(5):327-30.
34. Shear M, Hawkins DM, Farr HW. The prediction of lymph node metastases from oral squamous carcinoma. *Cancer.* 1976 Apr;37(4):1901-7.
35. Yamamoto E, Miyakawa A, Kohama G. Mode of invasion and lymph node metastasis in squamous cell carcinoma of the oral cavity. *Head Neck Surg.* 1984 May-Jun;6(5):938-47.
36. Jin WL, Ye WM, Zheng JW, Zhou L, Zhu HG, Zhang ZY, et al. Occult cervical lymph node metastases in 100 consecutive patients with cN0 tongue cancer. *Chin Med J (Engl).* 2008 Oct 5;121(19):1871-4.
37. Amaral TM, da Silva Freire AR, Carvalho AL, Pinto CA, Kowalski LP. Predictive factors of occult metastasis and prognosis of clinical stages I and II squamous cell carcinoma of the tongue and floor of the mouth. *Oral oncology.* 2004 Sep;40(8):780-6.
38. Werner JA, Du`nne AA, Myers JN. Functional anatomy of the lymphatic drainage system of the upper aerodigestive tract and its role in metastasis of squamous cell carcinoma. *Head Neck.* 2003 Apr;25(4):322-32.
39. Huang CH, Chu ST, Ger LP, Hou YY, Sun CP. Clinicopathologic evaluation of prognostic factors for squamous cell carcinoma of the buccal mucosa. *J Chin Med Assoc.* 2007 Apr;70(4):164-70.