

Assessment of the Inferior Mandibular Canal's Position by Cone-Beam Computed Tomography

Mohammad Mehdi Aghdasi¹ Nima Sheikhdavodi² Mahkameh Moshfeghi*¹
 Mohammad Asna ashari³

¹Dept. of Radiology, School of Dentistry, Shahid Beheshti University of Medical Sciences, Tehran, Iran.

²Dentist, Tehran, Iran.

³Dept. of Endodontics, School of Dentistry, Shahid Beheshti University of Medical Sciences, Tehran, Iran.

Abstract

Objectives: It is important to know the exact location and anatomic variety of inferior alveolar nerve canal for different procedures of mandibular surgeries. The aim of the present study was to evaluate inferior mandibular canal's anatomic position by Cone-beam Computed Tomography (CBCT).

Methods: In a cross sectional study, CBCT were taken and assessed from 130 patients (260 semi-arch) referring to the radiologic department of Shahid Beheshti Dental Faculty. Three points including 1cm before mental foramen (point A), under second molar's furcation (point B) and 1cm after mandibular foramen on the inferior alveolar canal (point C) were chosen. The canal diameter, length and the distance between the canal and inferior border of mandible were measured. SPSS version 19 software used for data analysis. T and variance tests evaluated the role of age, gender, canal length and jaw side.

Results: Mean age of patients was 43.73 ± 13.25 . Canal length, 61.71 ± 4.95 ml and canal diameter was 2.94 ± 0.58 mm. The distance between the canal and the inferior border of mandible was 9.47 ± 2.23 mm. There was a significant difference in gender and age for all parameters. The distance between the canal and the inferior border in C point and at mental foramen in cases with short and long canal length showed a significant difference. ($p \leq 0.012$)

None of the variables showed significant difference between right and left sides.

Conclusion: The anatomic position of mandibular canal is related to gender and canal length, and independent to age and side.

Key words: Mandibular canal, Anatomic position, CBCT (Cone-beam Computed Tomography).

Aghdasi MM, Moshfeghi M, Shikhdavodi N, Asna Ashari M. Assessment of the Inferior Mandibular Canal's Position by Cone-Beam Computed Tomography. J Dent Sch 2016; 34(1): 1-8.

Corresponding Author:
 Moshfeghi M.

Email:
 mahkameh_moshfeghi@yahoo.com

Received: 13.05.2015
 Accepted: 08.02.2016

Introduction

Inferior mandibular canal is an anatomical structure placed symmetrically in mandibular bone.

This canal hosts the inferior alveolar artery, vein and nerve and is situated from the mandibular foramen in the ramus to the mental foramen.

Differences in canal height and other anatomic varieties encountered in mandibular canal may be very important for surgeons. For example, it is crucial to protect inferior alveolar nerve during mandibular osteotomy surgeries, as well as in implant placement process (1).

Therefore, it is important to always take in consideration anatomic varieties of this nerve and its canal.

Due to OPG restrictions, studies which used this type of imaging could not be considered valid. Using CBCT, which is an advanced technology, increased the validity of studies in this field (2).

Numerous studies with different purposes have been carried out on the mandibular canal.

Angel et al. (3) have evaluated the alveolar canal variations and their relation with age and gender using CBCT. Images were taken from 165 patients between 18 and 80 years old. Alveolar canal position was determined on points: mandibular foramen on axial dimension, inferior alveolar canal and mental foramen on coronal dimension. Then, regression analysis was performed to evaluate age and gender effects on the variations, which was not significant. According to this study's results, finally the conclusion was that none of gender and age affects alveolar canal's position.

Zografos et al. (4) has divided in types all kind of mandibular canals. In the first type, the canal passes near the apexes of the first and second molars; in the second one the canal passes at the middle level between teeth apex and the inferior border of mandible, and in the third case the canal passes near the inferior border of mandible, which with 40% occurrence, makes it the most frequent type of mandibular canal.

The knowledge of canal length and particularly its position at different points of the pathway, and also the awareness of canal changing points help dentists recognize high risk regions. This concern takes a particular importance especially in endodontic, implant and third molar surgeries (5).

In comparative analyses between genders or ages, morphometric study by means of Panoramic radiography reveals the differences and inherent alterations in the evaluated groups, and has become a useful tool in research that analyzes the craniofacial complex development process (6).

Cone beam computed tomography (CBCT) is reportedly useful in determining the position of IAC. Kamburoglu et al. (7) noted that CBCT boasts of much higher accuracy than Panoramic images and calipers. In investigating the position of the canal around the mandibular first molars, they concluded-after evaluating 50 patients with intact dentition-that IAC is positioned about 4.9 mm from the buccal cortical bone and 17.4 mm from the upper cortical bone of the mandible .

With the daily increasing number of implant surgeries and important side effects such as paresthesia after inferior alveolar nerve injury (8), and also the relation between radiographic findings and the anatomic reality of canal position regarding the importance of these concerns in clinical and Para clinical diagnosis in dentistry, beside the fact that until now no other study has been carried on in our country with these characteristics, this study was done with the purpose of evaluating the anatomic position inferior mandibular canal via CBCT imaging.

Methods

In this analytic cross sectional study, 130 CBCT taken from patients with teeth over 18 years old who referred to Shahid

Beheshti Dental School during 2012-2013, have been assessed. The patients enrolled were 18 to 63 years old. The inclusion criteria were age above 18, presence of second molar, and also not having any kind of pathology or jaw fractures. In addition, all images with bad quality and cases in which the bone border appeared altered were removed from the research. To perform the imaging, samples were irradiated by New Tom VGi machine (Quantitative Radiology, Verona, Italy). In order to obtain similar and standard images, in all cases the patient was placed in a vertical position, using chin rest and head strap to hold the head position still during the whole procedure. All imaging was made at 110 kVp and 3-5mAs, using a 15×15 FoV. As a matter of quality, all used images were similar and the slice thickness was 2mm in all studies taken in consideration. Measurements were effectuated on computer monitor by the official software related to the machine (NNT) and with 0.1 mm precision. 20 images were reevaluated by an examiner, which results were compared with the primary results. According to the statistics expert, the difference obtained from the data was not considerable.

The distance between the mandibular foramen (C') and the center of mental foramen (A') with 0.1 mm precision was measured as mandibular canal length (A'C').

The mandibular canal diameter was measured at three points: 1cm in front of mandibular foramen (C), under the second molar's furcation (B) and 1cm behind the mental foramen (A), at 0.1 mm precision.

The distance between the point in the center

of mental foramen and the inferior border of mandible was measured.

The distance between the inferior wall of mandibular canal and inferior border of mandible was measured at three points A, B and C, with 0.1 mm precision.

The mentioned measurement were obtained and registered for both sides of the patients (9) (Figure 1).

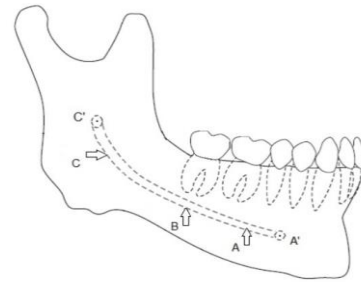


Figure 1- Schematic view of mandible and inferior mandibular canal and the measurement points.

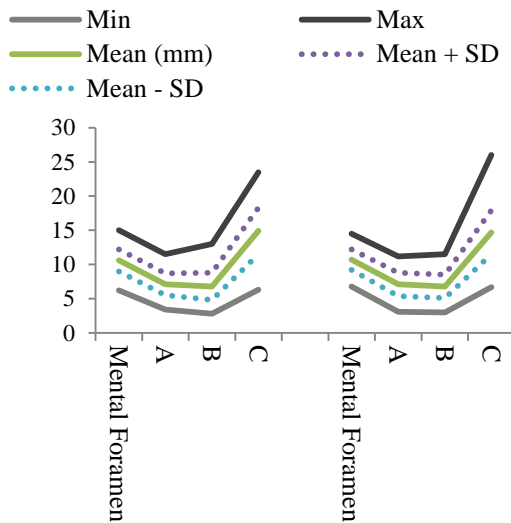
(A': center of mental foramen, C': center of mandibular foramen, A: 1cm behind the mental foramen, B: Under the second molar's furcation, C: 1cm in front of mandibular foramen)

The data analyze was performed by SPSS 22. The effects of age and gender on the parameters of the position of the inferior mandibular canal were evaluated using multiple linear regression model with enter method. The correlation between right and left sides of parameters were evaluated using Pearson correlation coefficient. Type I error was determined at 0.05, whereas with a P-value equal or inferior to 0.05, the difference was considered significant.

Results

The overall patients mean age was 43.73±13.25. Women's mean age was evaluated at 40.5±13.9 and men's mean age at 48±11.76. Also the oldest subject was 63 and the youngest one 18 years old. In this

study, the mandibular canal length at the right side was 59.6 ± 4.24 mm for women and 64.2 ± 4.81 mm for men. For the left side, this was 59.9 ± 4.42 mm for women and 64.5 ± 4.14 mm for men. The mean of distances between the mandibular canal and the inferior border of mandible at points A, B and C was respectively 6.94 ± 1.58 mm, 6.74 ± 1.78 mm and 14.75 ± 3.34 mm. Graph 1 which shows schematically in each side the path and the risings and fallings of the canal, was designed via the parameters of distances between the canal and the inferior border of mandible and their minimum, maximum, mean and standard deviation.



Graph 1- Schematic path of the inferior mandibular canal obtained from 4 vertical variables

The canal diameter’s mean was measured: at point A 2.65 ± 0.49 , at point B 2.76 ± 0.48

and at point C it was 3.41 ± 0.77 mm. The distances’ mean between mandibular canal and the inferior border of mandible was also measured at point A, B and C, and it was respectively 6.94 mm, 6.74mm and 14.75mm.

The results showed that in all measured parameters, there were significant differences between men and women ($p \leq 0.012$); and among all the mentioned parameters, the Mean Difference showed significant difference clinically: the mandibular canal length in both right and left sides (in men 4.6mm more than women), and also the distance between the mandibular canal and the inferior border of mandible at C point in both right and left sides (in men 2.6 more than in women).

There was not any statistical correlation between age and the parameters ($p \geq 0.383$)

Regarding the comparison of variables with canal length, in both sides, two variables: the canal distance from mental foramen and also the canal distance from the inferior border at point C among the persons with short canal length (less than 55mm) and those with long canal length (more than 65mm) showed significant differences. In a way that it could be stipulated that in people having longer canal, the beginning and the end of the canal are more distant from the inferior border of mandible, and a deeper curve is seen in the canal.

Table 1- Statistical results of significant variables of inferior mandibular canal based on mm between short and lengthy canals

Parameters	Canal Length	Canal Length	Side	P Value	Mean Difference
Distance between Mental foramen to inferior border	Less than 55mm	Over 65mm	Left	0.046	1.4
			Right	0.012	1.48
Distance between canal and inferior border at C point	Less than 55mm	Over 65mm	Left	0.006	3.84
			Right	0.001	4.65

As it was expected, none of variables showed a significant difference between right and left sides. This statistical outcome is another confirmation that inferior mandibular canal is symmetrical. The reliability score was 0.85.

Table 2- Correlation between inferior mandibular canal and inferior mandibular border in men based on length and sides

Variables	Side	Minimum	Maximum	Mean	Standard deviation	
Mandibular canal length	Right	51.3	81	64.20	4.81	0.290
	Left	51.6	77.4	64.56	4.14	
Distance between Mental foramen to inferior border	Right	7.6	14.5	11.52	1.32	0.128
	Left	6.9	14	11.12	1.53	
Distance between Mandibular canal and inferior border at A point	Right	5.2	14	7.75	1.73	0.190
	Left	5.5	11	7.8	1.3	
Distance between Mandibular canal and inferior border at B point	Right	3	10.8	7.25	1.72	0.361
	Left	3.4	11.1	7.38	1.78	
Distance between Mandibular canal and inferior border at C point	Right	9.1	26	16.23	3.11	0.334
	Left	6.4	23.2	16.62	3.30	

Table 3- Correlation between inferior mandibular canal and inferior mandibular border in women based on length and sides

Variables	Side	Minimum	Maximum	Mean	Standard deviation	Statistical result
Mandibular canal length	Right	44.8	68.3	59.64	4.29	0.274
	Left	40.7	68.5	59.96	4.42	
Distance between Mental foramen to inferior border	Right	6.8	14	10.25	1.42	0.143
	Left	6.2	15	10.25	1.61	
Distance between Mandibular canal and inferior border at A point	Right	3.1	11.1	6.55	1.66	0.416
	Left	3.4	11.5	6.58	1.75	
Distance between Mandibular canal and inferior border at B point	Right	3.3	11.5	6.56	1.79	0.164
	Left	2.8	13	6.44	2.07	
Distance between Mandibular canal and inferior border at C point	Right	6.7	20.9	13.61	2.86	0.313
	Left	6.3	23.5	13.61	2.99	

Discussion

Although there are only a few reports about this subject, inferior alveolar nerve damage is one of the most important side effects of posterior mandibular and ramus surgeries, such as wisdom tooth surgery or bone harvesting (10).

Silva et al. (11) evaluated at 8.3% the rate of sensory disorders after osteotomy surgeries in posterior of mandible. These disorders

occur when the osteotomy site is near the inferior alveolar canal.

In this study, we used the panoramic curve function in the software to establish the sagittal plane connecting and measuring the distance between mandibular foramen and the mental foramen. We then selected our points and created a cross sectional view from that particular points. With that view in each point we measured mandibular canal diameter and the distance between that point

to the inferior border of mandible. All the data were reported with 0.1 mm precision.

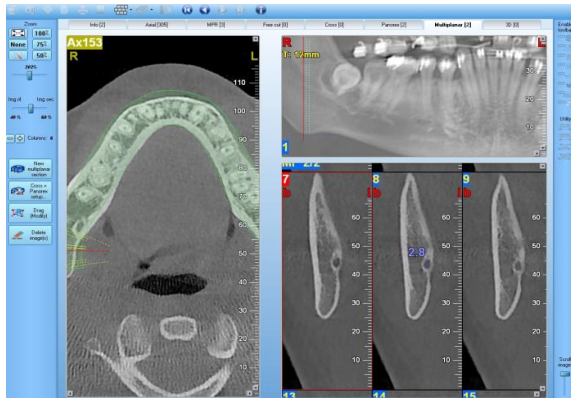


Figure 2- Measuring method in CBCT software using multiplanar section

Obradovic et al. (12) had reported 2.7 mm for the mandibular canal diameter. In the present study, this value is 2.95mm, which corresponds to the limits of the previous one. The difference in results may be due to race difference among people in the two studies and also the difference in their ages. In the present study, the cases had passed their limit of growth completion and they showed no bone growth changes, whereas in Obradovic research (1993), mandibles were chosen from different range of ages. In a research done by there was no significant correlation between age and the inferior mandibular canal, but there was a significant difference between the gender and the canal length; those results were exactly repeated in our study (13).

In the research done by Angel et al.(3) in 2011 and Amorim et al.(14) in 2009, no significant difference has been seen between vertical parameters of inferior mandibular canal in different group of age. But in the present study this result was obtained.

In order to give comparability with studies that were done with panoramic image

system, in those canals with oval shape in cross sectional view, we measured vertical diameter, whether it was larger or smaller.

In this study, it has been determined that concerning canal width variations on its pathway, in both gender, the beginning of the canal at point A has the smallest width (2.65 mm) and on its way toward point C (with 3.41 mm mean), its width increases. At point B, it has been measured 2.76 mm. In a research done by Ikeda et al.(15) in 1996 the maximum canal diameter was 4.1 mm, the mean value was 3.4 mm, and the minimum diameter of mandibular canal was reported at 2.2 mm.

In this study, The mean distance from the foramen to the inferior mandibular border varied from 6.8 to 14, which is near 7.07 to 11.54 mm found by Von Arx et al.(16) in 2011.

Levine et al. (17) showed that bucco-lingual position of inferior mandibular canal is related to age and gender; and in older and Caucasian people meanly there is shorter distance between the buccal side of canal and the border of mandibular canal, which correlates with the results of our study.

In their study, de Oliveira *et al.* (18) reported that in 75% of patients subject to the study, the mandibular canal diameter was between 2.1 and 4mm (18). In our study we obtained between 1.8 and 4.1, which correlates to Oliveira's study.

Conclusion

As the results showed, the anatomic position of mandibular canal is related to gender and canal length, and independent to age and side.

Acknowledgement: “None Declared”

Conflict of Interest: “None Declared”

References:

1. Mraiwa N, Jacobs R, van Steenberghe D, Quirynen M. Clinical assessment and surgical implications of anatomic challenges in the anterior mandible. *Clin Implant Dent Relat Res.* 2003;5(4):219-25.
2. Kumar V, Ludlow J, Soares Cevidanes LH, Mol A. In vivo comparison of conventional and cone beam CT synthesized cephalograms. *Angle Orthod.* 2008 Sep;78(5):873-9.
3. Angel JS, Mincer HH, Chaudhry J, Scarbecz M. Cone-beam Computed tomography for analyzing variations in inferior alveolar canal location in adults in relation to age and sex. *J Forensic Sci.* 2011 Jan;56(1):216-9.
4. Zografos J, Kolokoudias M, Papadakis E. [The types of the mandibular canal]. *Hell Period Stomat Gnathopathoprosopike Cheir.* 1990 Mar;5(1):17-20.
5. Gomes AC, Vasconcelos BC, Silva ED, Caldas Ade F Jr, Pita Neto IC. Sensitivity and specificity of Pantomography to predict inferior alveolar nerve damage during extraction of impacted lower third molars. *J Oral Maxillofac Surg.* 2008 Feb;66(2):256-9.
6. Akgul AA, Toygar TU. Natural craniofacial changes in the third decade of life: a longitudinal study. *Am J Orthod Dentofacial Orthop.* 2002 Nov;122(5):512-22.
7. Kamburoglu K, Kilic C, Ozen T, Yuksel SP. Measurements of mandibular canal region obtained by cone-beam computed tomography: a cadaveric study. *Oral Surg Oral Med Oral Pathol Oral Radiol Endod.* 2009 Feb;107(2):e34-42.
8. Kim ST, Hu KS, Song WC, Kang MK, Park HD, Kim HJ. Location of the mandibular canal and the topography of neurovascular structures. *J Craniofac Surg.* 2009 May;20(3):936-9.
9. Haghani J, Torabi M, Mehdizadeh M. Evaluation of the morphology and anatomy of mandibular canal in panoramic radiography of patient over 25 years old. *J Dent Sch.* 2009; 27(3): 128-35.
10. Parikh SN. Bone graft substitutes: past, present, future. *J Postgrad Med.* 2002 Apr-Jun;48(2):142-8.
11. Silva FM, Cortez AL, Moreira RW, Mazzonetto R. Complications of intraoral donor site for bone grafting prior to implant placement. *Implant Dent.* 2006 Dec;15(4):420-6.

12. Obradovic O, Todorovic L, Pesic V, Pejkovic B, Vitanovic V. Morphometric analysis of mandibular canal: Clinical aspects. *Bull Group Int Rech Sci Stomatol Odontol*. 1993 Jul-Sep;36(3-4):109-13.
13. Rashid SA, Jamal Ali. Morphometric analysis of mandibular canal course and position in relation to gender and age of Iraqi sample using digital panoramic imaging. *J Bagh Coll Dent*. 2011; 23: 92-99.
14. Amorim MM, Borini CB, Haiter-Neto F, Caria PHF. Morphological description of mandibular canal in panoramic radiographs of Brazilian subjects: Association between anatomic characteristic and clinical procedures. *Int J Morphol* 2009; 27(4): 1243–3248.
15. Ikeda K, Ho KC, Nowicki BH, Haughton VM. Multiplanar MR and anatomic study of the mandibular canal. *AJNR Am J Neuroradiol*. 1996 Mar;17(3):579-84.
16. Von Arx T, Matter D, Buser D, Bornstein MM. Evaluation of location and dimensions of lingual foramina using limited cone-beam computed tomography. *J Oral Maxill of ac Surg*. 2011 Nov;69(11):2777-85.
17. Levine MH, Goddard AL, Dason TB. Inferior alveolar nerve canal position: a clinical and radiographic study. *J Oral Maxill of ac Surg*. 2007 Mar;65(3):470-4.
18. de Oliveira-Santos C, Souza PH, de AzambujaBerti-CoutoS, Stinkens L, Moyaert K, Rubira-Bullen IR, et al. Assessment of variations of the mandibular canal through cone beam computed tomography. *Clin Oral Investig*. 2012 Apr;16(2):387-93.