

Treatment of a horizontally impacted permanent incisor in a 9-year-old girl: A Case Report

Shiva Shekarian,^a and Mohammad Behnaz^{b*}

^aDental Student, School of Dentistry, Shahid Beheshti University of Medical Sciences, Tehran, Iran.

^bDepartment of Orthodontics, School of Dentistry, Shahid Beheshti University of Medical Sciences, Tehran, Iran.

*Correspondence to: Behnaz M. (email: behnaz1357@yahoo.com).

(Submitted: 28 September 2016 – Revised version received: 08 December 2016 – Accepted: 20 December 2016 – Published online: Winter 2017)

Impaction of maxillary central incisors is not common. Treatment of an impacted central incisor is challenging as it relates to facial esthetics and dental function.

Although impaction of permanent teeth is rarely diagnosed in mixed dentition period, an impacted central incisor is usually diagnosed when there is a delay in the eruption of tooth.

Tooth impaction may result from a number of local etiological factors such as lack of space for eruption, presence of supernumerary teeth, disturbances in the path of eruption and presence of pathological cysts. Management options for such teeth include (1) surgical extraction and moving the lateral incisor to replace the central incisor and changing the anatomy of other teeth, (2) extraction of the impacted tooth followed by bridge or implant placement, (3) surgical repositioning of the impacted tooth, and (4) orthodontic correction of the impacted tooth.

The purpose of this article was to describe surgical exposure and orthodontic treatment of a horizontally impacted permanent maxillary central incisor, parallel to the occlusal plane in a 9-year-old girl. The impacted tooth was surgically exposed and traction was done with orthodontic intervention.

Keywords: tooth, impacted, orthodontic extrusion, incisor

Introduction

Naturally, permanent teeth erupt at the right time in the oral cavity. But sometimes, for various reasons, this eruption may encounter some difficulties and the tooth may become impacted in the alveolar bone. The maxillary central incisors are the most important teeth in the mouth considering their role in facial appearance, esthetics, pronunciation, mastication, and psychological health.¹

The etiology of tooth impaction has been described to be multifactorial, involving genetics and environmental factors² such as lack of space in the alveolar process, abnormal frenum, over-retained primary teeth, trauma, ankylosis, supernumerary teeth, tumors [such as odontoma,² local cysts, ectopic development of tooth germ,³ crown or root malformation³ and disturbances in the path of eruption.⁴

Odontomas may block the path of tooth eruption. They vary in size and type. Trauma at an early age, before permanent tooth eruption, may damage the root-forming cells of the unerupted permanent tooth germ and attenuate productivity rate of the root portion, and also change the tooth orientation in the alveolar process. This results in development of a dilacerated tooth, which will not usually erupt unaided.⁵

If a tooth does not erupt in the appropriate age into the oral cavity, especially when there is disturbance in eruption sequence, its position must be checked using radiographs. One of the possibilities in these cases is deviation from normal eruption path and impaction. The most commonly impacted maxillary teeth include canines, followed by the central incisors. Impaction of the maxillary incisor teeth occurs infrequently (0.06%–0.2%).⁶

The impaction of a permanent tooth usually occurs during mixed dentition period, but is mainly diagnosed at a later age. However, impaction of central incisors is usually diagnosed when there is a delay in the eruption of tooth during this

period.⁷ When a central incisor fails to erupt within one year after the normal eruption time, especially when the adjacent teeth have erupted, there is no excuse to delay treatment.³

The impaction of a central incisor can affect esthetics, phonetics, mastication and psychology in a young patient and this may be frightening for parents. On the other hand, retained impacted teeth may be ankylosed or can cause root resorption of the adjacent teeth due to deviation of eruption path.

Treatment options for an impacted central incisor include extraction and restoration with a bridge or dental implant later when growth has ceased, extraction and closure of the space by substituting the lateral incisor for the central incisor with subsequent prosthetic restoration and surgical exposure, orthodontic space opening, and traction of the impacted central incisor into its proper position.⁸ Clinicians should consider treatment goals that minimize injuries to the dentition and the periodontium.⁹

This article describes surgical exposure and orthodontic treatment of a horizontally impacted permanent maxillary central incisor, parallel to the occlusal plane in a 9-year-old girl. The impacted tooth was surgically exposed and traction was done with orthodontic intervention.

Case Report

A 9-year old female patient in the early mixed dentition period was referred to a private clinic with major complaint of unerupted right maxillary central incisor. The patient was physically healthy and had no history of dental trauma. She had a symmetric facial pattern but an asymmetric smile. Extra-oral examination revealed a convex profile, decreased vertical facial height, increased nasolabial angle, competent lips and decreased tooth show (Fig. 1).

Intra-oral examination revealed the following (Fig. 1): The patient had Class I molar relationship, and the maxillary

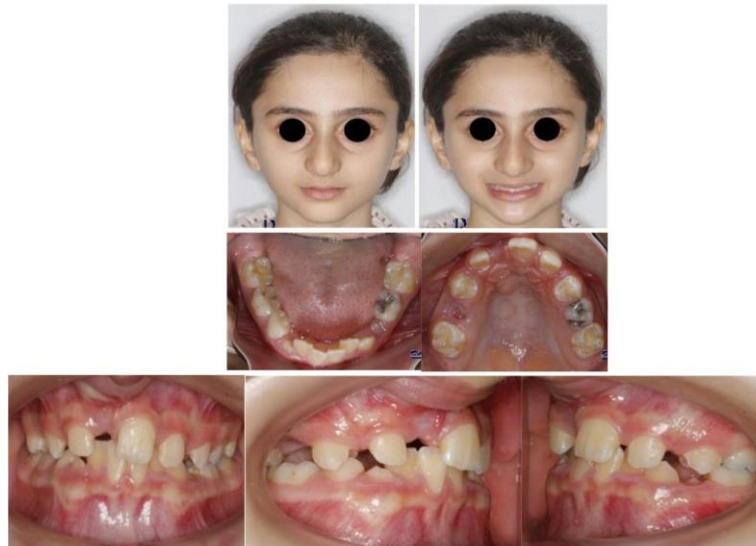


Fig 1. Pretreatment photographs.

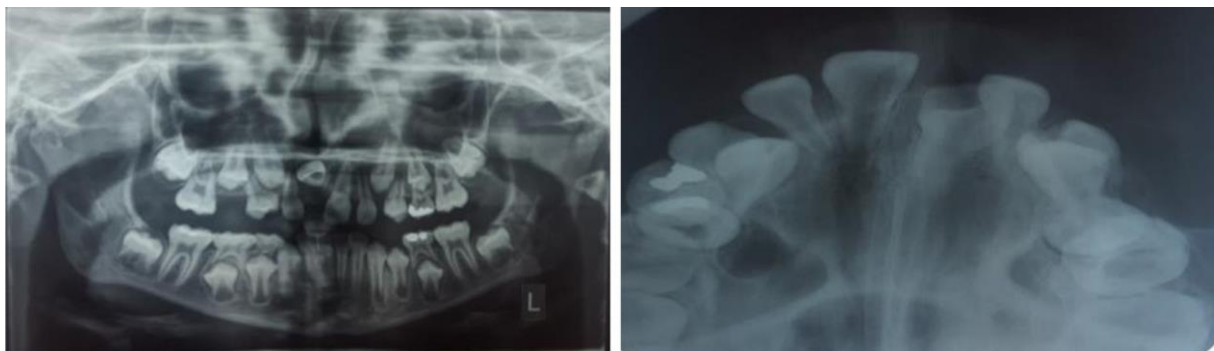

Fig 2. Pretreatment panoramic and occlusal radiographs.

midline was found to shift to the right and the adjacent teeth had drifted into the impacted central incisor space. The patient had maxillary constriction. Overjet was 2 mm and overbite was 4 mm. The lower teeth had moderate crowding.

Panoramic radiograph showed a horizontally impacted central incisor parallel to the occlusal plane almost on the floor of the nasal cavity in such a way that the crown was labially and the root was palatally positioned. To understand the exact position of the tooth, occlusal radiograph and cone beam computed tomography (CBCT) scans were obtained, which showed the proximity of the tooth to the floor of the nasal cavity (Figs. 2 and 3).

In the first step, to resolve the maxillary constriction and gain enough space for central incisor, a removable expansion appliance, with a midpalatal screw, was used. Simultaneously, the left lateral incisor moved distally by a finger sprig. Thus, enough space was regained for the traction of the impacted central incisor.

Next, a Nance appliance, with a posterior direction hook (the hook in the acrylic button), was placed on the first molars. The impacted central incisor was exposed by a closed surgical exposure technique, and an orthodontic button with a wire was bonded to the palatal surface of the tooth in a way that the wire was out of the gingiva.

Palatal force was applied using an elastic thread from the bonded button to the soldered hook of the Nance appliance. Gradually, the tooth became more vertical and parallel to other anterior teeth. Nevertheless, it was covered with alveolar bone and gum.

In the next step, other erupted incisors and premolars were bonded, and the leveling and alignment procedure was performed. Then, a push coil was placed between the left central incisor and right lateral incisor to hinder these teeth from moving to the impacted central incisor space. Vertical forces were applied to the right central incisor using elastic threads, although the main arch wire was 0.017–0.025 inch stainless steel. After the appearance of tooth in the oral cavity, the bonding braces of the central incisor were placed in the arch using auxiliary wires. At the same time, fixed orthodontic treatment was accomplished to relieve lower jaw crowding.

At the end of the treatment, maxillary and mandibular teeth were leveled and aligned and Class I ideal occlusion was obtained. The duration of treatment was 23 months and the patient was followed for 18 months after the completion of treatment. Hawley retainers were used for the retention period. The patient was requested to use these retainers full-time in the first four months following completion of treatment. Due to no relapse in position of teeth in both jaws,

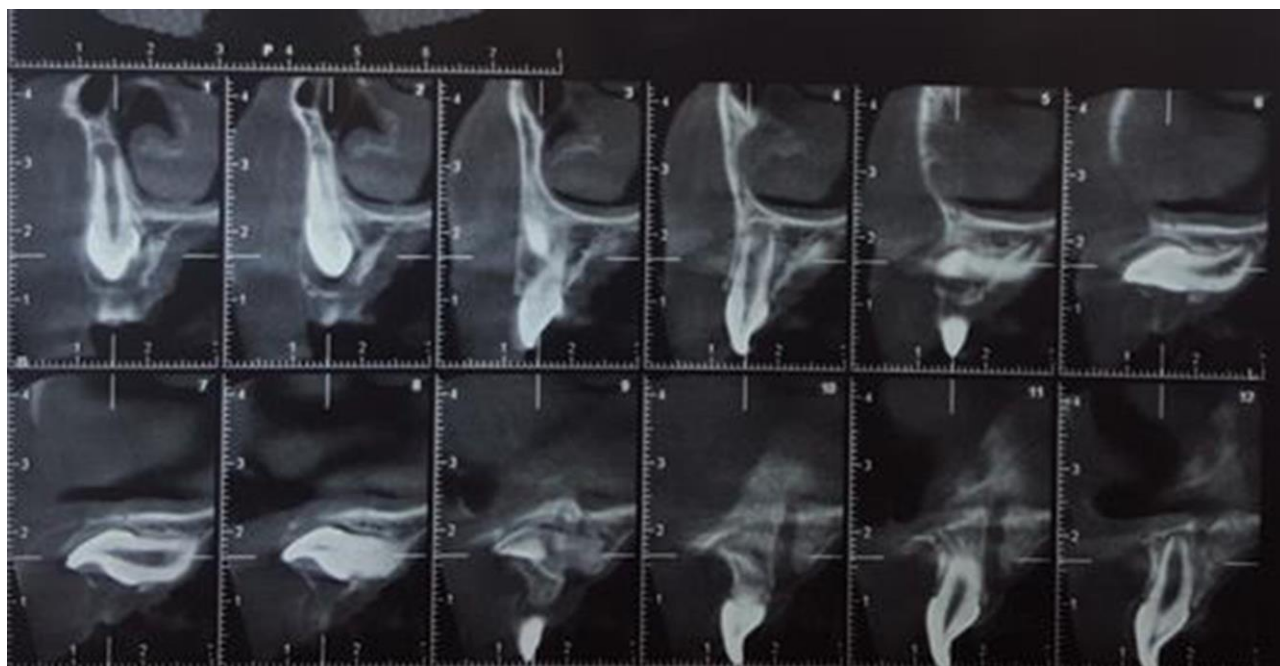


Figure 3. Pretreatment CBCT.

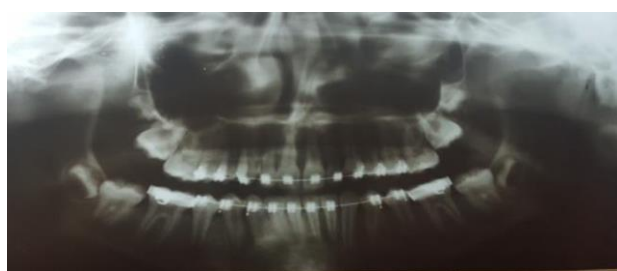

Fig 4. Final panoramic radiograph.

duration of usage of these retainers decreased for the next six months. All the data indicated successful treatment (Fig. 4). the retention period, no root resorption or central incisor rotation or intrusion was found.

Discussion

Impaction is defined as a phenomenon in which a tooth cannot erupt into its functional position. Central incisor is an important tooth in terms of function and esthetics. Unerupted central incisor can hinder the alveolar bone growth.¹⁰ Thus, the alveolar bone growth must be considered as an important part of the impacted central incisor management. Impacted teeth can cause serious dental and esthetic difficulties as well as psychological problems especially in anterior regions.² Furthermore, remaining of the impacted tooth may cause cyst formation such as dentigerous cyst, root displacement and resorption, periodontal problems in adjacent teeth and referral pain.⁴

When the central incisor is impacted, it is usually located in the middle faciolingual part of the alveolus. In most cases, the tooth is oriented vertically as its position in the arch. In some patients however, the tooth is located horizontally and parallel to the occlusal plane,² making it more difficult to treat.

There are different treatment plans for management of an impacted central incisor, including:

1. Extraction of impacted tooth and tooth restoration with an implant or a bridge.
2. Extraction of impacted tooth and closure of the space by substituting the lateral incisor and then prosthetic restoration of lateral incisor.
3. Surgical exposure of impacted tooth and traction of the tooth to its proper position by orthodontic treatment.¹¹

The first option requires a waiting period for completion of patient growth. Thus, the central incisor impaction is diagnosed at an early age and the patient and his/her parents are emotionally affected.⁵ If this treatment is performed before the completion of growth, there will be a disharmony between the implant (or bridge) and the surrounding tissues due to the growth of tissues surrounding the implant (or bridge), which can affect the patient's esthetics. However, some studies have suggested that before performing this treatment, the impacted tooth must be brought to its position with orthodontic treatment for proper bone height. The second option is not acceptable due to the following esthetic reason: since the lateral incisor is smaller than the central incisor in terms of mesiodistal width, prosthodontic restoration cannot create appropriate esthetics.¹² Surgical exposure and orthodontic traction, although are difficult procedures for orthodontists, save the patient's natural tooth and retain his/her esthetics. This method is the most practical among all. In our patient, after surgical exposure, the central incisor was brought to the arch by the orthodontists.

Movement of an impacted central incisor would be impossible because of ankylosis and external root resorption.¹³ Furthermore, even successfully treated patients can have irregular root formation, resorbed root or an unesthetic gingival margin after alignment.¹⁴ However, these complications did not occur in our patient. Our treatment objectives were:

(I) to create a stable functional occlusion and (II) establish adequate attached gingiva and symmetric gingival margins for both central incisors.³

Conclusion

Maxillary right central incisor was successfully brought to the arch by closed surgical exposure and orthodontic traction. The treatment results showed acceptable occlusion and stability. Thus, the prognosis of orthodontic-surgical

treatment for such deeply impacted incisors is good if proper management is done.

Conflict of Interest

None Declared.

References

1. Shi X, Xie X, Quan J, Wang X, Sun X, Zhang C, et al. Evaluation of root and alveolar bone development of unilateral osseous impacted immature maxillary central incisors after the closed-eruption technique. *Am J Orthod Dentofacial Orthop.* 2015;148:587–598.
2. Sun H, Hu R, Ren M, Lin Y, Wang X, Sun C, et al. The treatment timing of labial inversely impacted maxillary central incisors: a prospective study. *Angle Orthod.* 2016;86:768–774.
3. Pinho T, Neves M, Alves C. Impacted maxillary central incisor: surgical exposure and orthodontic treatment. *Am J Orthod Dentofacial Orthop.* 2011;140:256–265.
4. Sant'Anna EF, Markezan M, Sant'Anna CF. Impacted incisors associated with supernumerary teeth treated with a modified Haas appliance. *Am J Orthod Dentofacial Orthop.* 2012;142:863–871.
5. Chaushu S, Becker T, Becker A. Impacted central incisors: factors affecting prognosis and treatment duration. *Am J Orthod Dentofacial Orthop.* 2015;147:355–362.
6. Deshpande A, Prasad S, Deshpande N. Management of impacted dilacerated maxillary central incisor: a clinical case report. *Contemp Clin Dent.* 2012;3:S37–S40.
7. Uematsu S, Uematsu T, Furusawa K, Deguchi T, Kurihara S. Orthodontic treatment of an impacted dilacerated maxillary central incisor combined with surgical exposure and apicoectomy. *Angle Orthod.* 2004;74:132–136.
8. Tanaka E, Hasegawa T, Hanaoka K, Yoneno K, Matsumoto E, Dalla-Bona D, et al. Severe crowding and a dilacerated maxillary central incisor in an adolescent. *Angle Orthod.* 2006;76:510–518.
9. Frank CA. Treatment options for impacted teeth. *J Am Dent Assoc.* 2000;131:623–632.
10. Cesur MG, Esenlik E, Findik Y. Impacted maxillary central incisors associated with bilateral mesiodentes: a case report. *Biol Med.* 2014;6:1–5.
11. Thosar NR, Vibhute P. Surgical and orthodontic treatment of an impacted permanent central incisor: a case report. *J Indian Soc Pedod Prev Dent.* 2006;24:100–103.
12. Chawla HS, Kapur A. Orthodontic management of faciolingual horizontally impacted maxillary central incisor. *J Indian Soc Pedod Prev Dent.* 2009;27:65–69.
13. Sabri R. Treatment of a Class I crowded malocclusion with an ankylosed maxillary central incisor. *Am J Orthod Dentofacial Orthop.* 2002;122:557–565.
14. Chaushu S, Brin I, Ben-Bassat Y, Zilberman Y, Becker A. Periodontal status following surgical-orthodontic alignment of impacted central incisors with an open-eruption technique. *Eur J Orthod.* 2003;25:579–584.

How to cite:

Shekarian S, Behnaz M. Treatment of a Horizontally Impacted Permanent Incisor in a 9-Year-Old Girl: A Case Report. *J Dent Sch.* 2018;35(1):32–35.