

## Effect of Intra-Canal Direct Current Electric Stimulation on Orthodontic Tooth Movement: An Experimental Study in Canines

Abdolrahman Showkatbakhsh<sup>1</sup> Farnaz Younessian\*<sup>2</sup> Omid Dianat<sup>3</sup> Seyed Sadra Izadi<sup>4</sup> Mohammadreza Badiee<sup>2</sup> Mehrdad Showkatbakhsh<sup>5</sup> Alireza Akbarzadeh Baghban<sup>6</sup>

<sup>1</sup>Dept. of Orthodontics, School of Dentistry, Shahid Beheshti University of Medical Sciences, Tehran, Iran.

<sup>2</sup>Dentofacial Deformities Research Center, Research Institute of Dental Sciences, Shahid Beheshti University of Medical Sciences, Tehran, Iran.

<sup>3</sup>Dept. of Endodontic, School of Dentistry, Shahid Beheshti University of Medical Sciences, Tehran, Iran.

<sup>4</sup>Dept. of Clinical Sciences, Faculty of Veterinary Medicine, University of Tehran, Tehran, Iran.

<sup>5</sup>PhD Student of Electrical engineering, University of southern California, California, USA.

<sup>6</sup>Dept. of Basic Sciences, Faculty of Rehabilitation School of Rehabilitation Sciences, Shahid Beheshti University of Medical Sciences, Tehran, Iran.

### Abstract

**Objectives:** The purpose of this study was to evaluate whether intra-canal application of controlled direct electric current (DEC) could accelerate the amount of orthodontic tooth movement (OTM) in young adult mixed breed dogs.

**Methods:** Fourth premolars of both jaws of five young adult mixed breed dogs were divided into two groups of control and experimental groups. Orthodontic force was applied to both groups using an active NiTi push coil spring. Direct electric stimulation (15 $\mu$ A DC) was conducted by intra-canal usage of electric potential (1.5v). The experimental teeth were compared with controls in terms of clinical OTM results measured with an electronic caliper every two weeks (four time intervals). The animals were sacrificed one month (T2) or two months (T4) after initiation; and tissue sections were decalcified for histological evaluation. The data were analyzed using SPSS 16, Shapiro-Wilk test and paired t-test.

**Results:** Measurements revealed a statistically significant increase in OTM at electrically stimulated sites compared to the control sites in just one time interval (T3: after four weeks) ( $P < 0.05$ ). Histological sections also showed increased osteoblastic and osteoclastic activity at tension and compression sides of the experimental group compared to the control group, respectively at both time intervals (T2 and T4).

**Conclusion:** Direct intra-canal electric current applied by a miniature electric device is effective for increasing the rate and amount of OTM in canine experimental model.

**Key Words:** Electric Stimulation; Tooth Movement; Osteogenesis; Bone Resorption.

### How to cite:

Showkatbakhsh A, Younessian F, Dianat O, Izadi S.S, Badiee M, Showkatbakhsh M, Akbarzadeh Baghban A. Effect of Intra-Canal Direct Current Electric Stimulation on Orthodontic Tooth Movement: An Experimental Study in Canines. J Dent Sch 2016;34(3):157-67.

\*Corresponding Author:  
Younessian F  
E-mail:  
farnaz.younessian@gmail.com

Received: 08.09.2016  
Accepted: 29.09.2016

## Introduction

In an effort to accelerate OTM, several methods including different drug injections, ultrasound, low-level lasers, etc. have been investigated (1-8). After understanding the piezoelectric nature of bone, several studies were done to evaluate the formation and remodeling of bone and the surrounding

tissues by direct electrical stimulation (9,10). It has been stated that application of low DEC (15 $\mu$ A) significantly increases the rate of osseointegration, periodontal healing, fracture fixation, osteogenesis in healing tooth sockets and OTM (11-17). Regarding accelerated tooth movement, it has been shown that by a combination of electrical current and mechanical force, teeth moved

significantly faster than those treated by force alone (10). Bone formation was observed near the anode (periodontal ligament tension site); whereas, enhanced bone resorption occurred near the cathode electrode (periodontal ligament compression site), and the overall rate of bone remodeling accelerated significantly (10). From the molecular perspective, the mechanism of this effect is described mainly by the changes in micro-environment around the cells and direct alterations in cellular activities (18,19). However, despite clear confirmation of the significant effect of direct current on OTM, application of these methods has been limited since 1987 (20). The major drawback of application of electric stimulation in the oral cavity is the problem of how to provide electrical supply (21). Unlike orthopedics, applying the electric current in the oral cavity necessitates using invasive and semi-invasive methods like surgical soft tissue flap in the buccal vestibule or insertion of electrodes directly into the gingival sulcus. Furthermore, it is not logical to place the battery packs outside the oral cavity and connect them to the intraoral appliances by electrical wires, since it complicates their application in the oral cavity (21). Thus, many researchers tried to find applicable methods to overcome this problem by using the bite force and temperature differences as a source of generating electricity in the oral cavity (21-23); however, there is still no definitive way to provide electrical stimulation in the clinical setting (20). To date, several animal and clinical studies have been done via embedding a miniature electric source in a removable appliance surrounding the target

teeth (9,16,24). However, since OTM is an inflammation-based phenomenon, irritation and inflammation of the surrounding soft tissue may decrease or amplify the effect of electric current on the observed OTM (24). Davidovitch *et al.* (9,10) reported that locally applied external electric current might be effective only in 2-3 mm area adjacent to electrodes. Hence, the tissue resistance near the electrodes has the potential to significantly decrease the electric current directed to bone.

To overcome the reported shortcomings of the application of external direct current, in this study, we sought to assess the effect of direct intra-canal electrical stimulation on OTM to find the best method of electricity delivery and determine whether intracanal application of controlled DEC could accelerate the amount of OTM in young adult mixed breed dogs.

## Methods

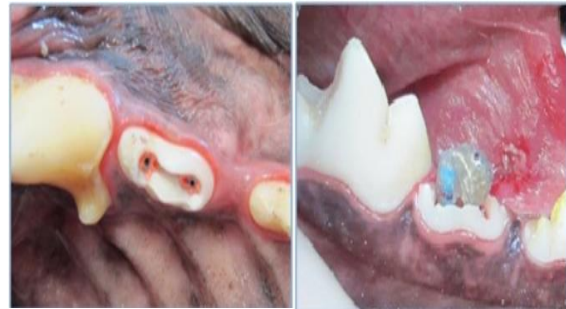Five male,  $13 \pm 1$  month-old mixed breed dogs with a mean weight of  $20 \pm 5$ kg were used in this study. The status of their dentition was checked before initiation. They were caged individually and fed with soft dog food and water. Four sites in each dog were used in this experimental split-mouth study.

The study design was approved in the Ethics Committee of Shahid Beheshti University of Medical Sciences. Also, the study was conducted in accordance with the guidelines for ethical conduct in the care and use of animals. Procedures were carried out under general anesthesia. The dogs were preanesthetized with subcutaneous injection

of 0.03mg/kg atropine (Darou pakhsh, Tehran, Iran) and intramuscular injection of 0.2mg/kg butorphanol (Butomidol, Richter Pharma AG, Wels, Austria). Anesthesia was induced using a combination of 0.27mg/kg diazepam (Chemi Darou, Tehran, Iran), and 5.5mg/kg ketamine hydrochloride (Alfasan, International B.V., Woerden, Holland) intravenously as the anesthetic agent; 0.9% normal saline was also administered (10 ml/kg/hour). In addition, 22mg/kg cefazolin was injected intravenously. Maintenance of anesthesia was achieved by intravenous injection of appropriate amounts of ketamine hydrochloride and xylazine hydrochloride 5mg/kg at 30-minute intervals. The oral cavity was irrigated with 0.02% chlorhexidine mouthwash before the intraoral procedures.

Fourth premolars were chosen for our study because of several considerations including the number of roots, root lengths, position of the root relative to each other and available volume of crown, which permit the device to be embedded at the coronal access cavity. In addition, large interproximal spaces between dogs' first molar teeth and the fourth premolar is useful for inducing tooth movement without tooth extraction. The access cavities were prepared on the occlusal surface of the fourth premolars in each quadrant, using a #010 round diamond bur (Tizkavan, Tehran, Iran) at high-speed and under constant saline irrigation. Endodontic treatment of all fourth premolars was performed using the crown-down technique with nickel-titanium rotary files (ProTaper, Dentsply Maillefer, Ballaigues, Switzerland). On one side of each jaw, the access cavity was filled with a packaged

direct electric stimulator (watch battery 1.55V) and resistance in an acrylic cap including two conductive stainless steel wires extending toward the apex in a rigid conductive sleeve. The remaining spaces in canals were filled by means of flowable gutta-percha (Meta Biomed Co., Cheongju, Korea) and AH-26 sealer (Dentsply, DeTrey, Konstanz, Germany) (Figure 1).



**Figure 1- (A) Root canal therapy of the fourth premolar, including a conductive sleeve in both mesial and distal roots containing extending wires from miniature electric device. (B) Experimental device embedded in place.**

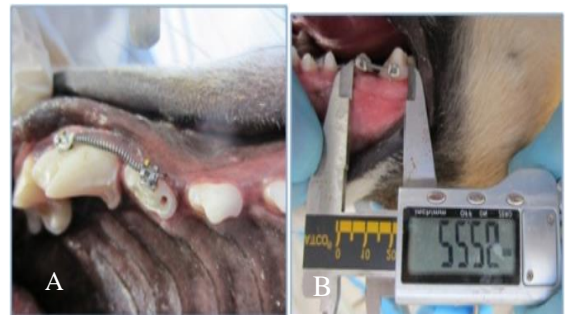The amount of electricity was monitored with digital multimeter and the electrical current was confirmed to be 15uA. The lengths of canals were assessed by means of apex locator. The positive pole (cathode) was inserted in the mesial root while the negative one (anode) was inserted in the distal root. The crowns were sealed and restored using light-cure composite resin (3M Unitek, Monrovia, CA, USA). The contralateral side served as the control group and was filled with a sham appliance. Simultaneously, the enamel surface was cleaned and etched for 30 seconds and orthodontic brackets (Roth, 0.022 inch) were bonded to the fourth premolars and first molars. These teeth were slid apart from each other by an active NiTi-based push coil spring (Ormco, Orange, CA, USA) on 0.018 stainless steel segmental arch wires,

providing a force of 58.8 CN at both sites. Slight occlusal reduction was done to permit keeping the experimental devices in place and also, the sites were examined weekly for any dislodgement. Antibiotic therapy included intramuscular injection of 22mg/kg cefazolin, tid, for three days; 50mg tramadol bid was injected intramuscularly to reduce pain for two days postoperatively.

The amount of OTM was measured by comparing the change in distance between the adjacent teeth at four time intervals (T1: Two weeks, T2: Four weeks, T3: Six weeks, T4: Eight weeks). The exact amounts of tooth movement were measured clinically by sliding Boley gauge caliper (Dentaurum, Ispringen, Germany) with sharp tips, at the mesial of the fourth premolar and buccal groove of the first molar on a horizontal plane parallel to the occlusal plane (Figure 2). Two measurements were made for each side by two independent examiners and the average distance was recorded. This technique was accurate regarding the inter-observer difference (standard deviation of mean differences about 0.02mm) in the present study similar to a previous study (24).

Two dogs were sacrificed with an overdose of anesthesia after four and the rest after eight weeks (T2: Four weeks, T4: Eight weeks) for histological analysis. The manipulated areas were removed from the jaws and fixed in 10% formalin. Before decalcification in nitric acid, cone beam computed tomography scans were taken. The fixed blocks were soaked in nitric acid with an adequate pH for one month. Decalcified sites were cut into pieces as small as the root and the adjacent bone area.

The specimens were sectioned mesiodistally parallel to the long axis of the roots (4 $\mu$ m thickness) with a microtome, and stained with hematoxylin and eosin. Qualitative histomorphometric assessments of the coded specimens were made by the same examiner twice with a light microscope and digital photographs were obtained and recorded. The experimental process was well tolerated in all samples. The animals were kept under soft diet and none of them lost weight significantly. In all samples, the experimental devices remained in place and intact.



**Figure 2-** (A) Orthodontic brackets and active NiTi coil springs on 0.018 segmental stainless steel were used for generating reciprocal force on the fourth premolar and the first molar. (B) Measuring the tooth movement distance using sliding Boley gauge caliper intra-orally.

In this split-mouth experimental study, descriptive statistics (including the mean and standard deviation) for the rate of OTM in each group were calculated. Considering the normal distribution of data (Shapiro-Wilk test), the mean values of OTM were analyzed statistically and compared by paired t-test between the control and experimental groups.

## Results

Measurements revealed a significant increase in OTM at electrically stimulated

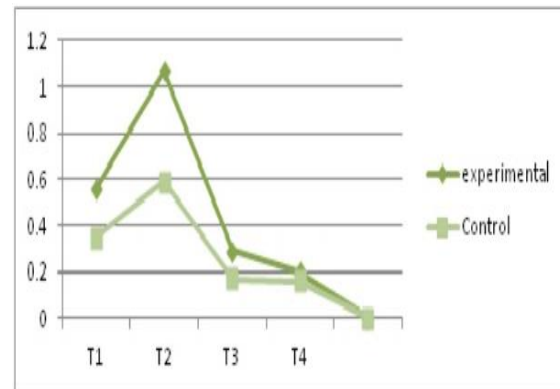
sites compared to the control sites on the other side of the jaw at only T2 time interval ( $P<0.05$ )(Table 1). There was no statistically significant difference between the experimental and the control side in the amount of tooth movement at other time intervals (T1, T3 and T4). Table 1 shows the mean amount of tooth movement at each time interval. The overall amount of OTM in experimental and control groups was statistically significant ( $P<0.05$ ).

**Table 1- The mean and standard deviation of movement of the fourth premolars in the experimental and control groups during each experimental period (\* $P<0.05$ )**

	Experimental side	Control side	P value
T1: 2 weeks	0.56 ± 0.32	0.35 ± 0.29	0.094
T2: 4 weeks	1.07 ± 0.57	0.59 ± 0.29	0.030*
T3: 6 weeks	0.29 ± 0.13	0.17 ± 0.07	0.107
T4: 8 weeks	0.20 ± 0.11	0.16 ± 0.12	0.352
Sum	1.93 ± 0.68	1.15 ± 0.38	0.016*

In both the study and the control groups, the highest amount of tooth movement was observed during the second time interval (four weeks), followed by the third time interval (six weeks)(Figure 3). A descending pattern of the rate of tooth movement in both groups was noted as such. On the other hand, almost the same amount of tooth

movement was measured during the last two time intervals in the control side.



**Figure 3- Comparison of orthodontic tooth movement at each experimental time point.**

Precise evaluation of the amount of tooth movement via intra-arch comparison (Tables 2 and 3) showed a significant difference between the study groups only at T4 in the maxillary arch ( $P<0.05$ ). The observed differences in the lower arch were not statistically significant at any time interval ( $P>0.05$ ).

**Table 2- The mean and standard deviation of movement of fourth premolars in the experimental and control groups during each experimental period in the upper jaw (\* $P<0.05$ )**

	Experimental side	Control side	P value
T1: 2 weeks	0.57 ± 0.22	0.37 ± 0.33	0.05
T2: 4 weeks	1.02 ± 0.62	0.64 ± 0.36	0.10
T3: 6 weeks	0.34 ± 0.18	0.16 ± 0.07	0.11
T4: 8 weeks	0.23 ± 0.06	0.12 ± 0.04	0.03*
Sum	2.11 ± 0.59	1.20 ± 0.23	0.019*

**Table 3- The mean and standard deviation of movement of fourth premolars in the experimental and control groups during each experimental period in the lower jaw (\* $P < 0.05$ )**

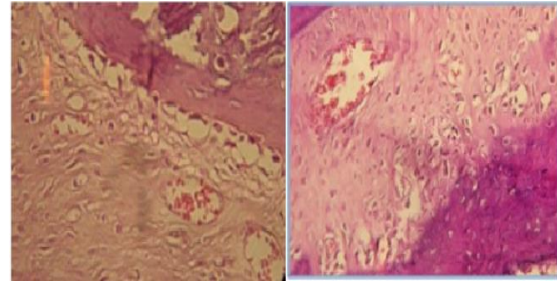
	Experimental side	Control side	P value
T1: 2 weeks	0.55 ± 0.43	0.32 ± 0.27	0.37
T2: 4 weeks	0.94 ± 0.55	0.54 ± 0.24	0.23
T3: 6 weeks	0.24 ± 0.08	0.18 ± 0.09	0.62
T4: 8 weeks	0.17 ± 0.15	0.20 ± 0.10	0.46
Sum	1.74 ± 0.79	1.10 ± 0.52	0.26

#### Histological findings:

In the distal side of the fourth premolar roots (tension side), widening of the periodontal ligament space and accumulated osteoblasts near the surface of the bone spicules were noticed on the microphotographs from both experimental and control groups after four weeks (T2). However, this proliferation of capillaries and osteoblasts was more significant in the experimental groups (Figure 4A). The same picture was observed after eight weeks at the tension side, in addition to the thin extensions of bone spicules along the direction of the tooth movement in both control and experimental groups.

In the mesial side of the fourth premolars (compression side), narrowing of the periodontal ligament and active osteoclasts were observed. However, this osteoclastic activity at the experimental side was more significant compared to the control group at both time intervals (T2 and T4) (Figure 4B). The overall cell activity related to bone

remodeling (osteoblasts and osteoclasts) was more evident in the experimental group, especially at T2 compared to T4.



**Figure 4- Histological microphotographs of the experimental groups: (A) Tension side: A widened periodontal ligament filled with fibroblasts and collagen fibers with active osteoblasts at the surface of the bone spicules (H & E staining, ×200); (B): Compression side: a narrow periodontal ligament with osteoclastic activity at the bony surface (H & E staining, ×200).**

#### Discussion

The results of this study demonstrated that direct electric currents, when applied to the canals, are capable of accelerating OTM in canine animal model. In our study, similar to other tooth-movement studies, the mean rate of OTM in the experimental group was significantly greater than that in the control group (24). The peak OTM in both groups was observed at T2 (four weeks) and declined thereafter without any reactivation of the appliance, which is compatible with general curve of OTM. The amount of fourth premolar tipping with continuous 0.018 stainless steel sectional wires, was moderate in both arches.

After understanding the piezoelectric nature of bone tissue, many studies were conducted with the aim of induction of bone formation by means of external electrical current (4,9,10). In all studies, accelerated bone formation and resorption were reported near the anode and cathode, respectively (24). In

the literature, the basic mechanisms of these changes are mainly related to the alterations in the micro-environment of cells and direct induction of cellular activity (18,19). For example, a reduction in oxygen concentration and increase in pH near the negative electrode can affect osteogenic activity of cells. In an alkaline environment, calcium release occurs, which favors the initiation of osteogenesis (24). However, the precise mechanism is still unknown (25).

In this study, the anode was inserted into the distal root, the cathode was inserted into the mesial root and the expected movement of teeth was determined to be in the mesial direction. Davidovitch *et al.* (9,10) reported that differential effects were localized to the restricted areas adjacent to electrodes within 2-3mm area and thus, the position of the electrodes needs to be determined precisely. In previous studies, the routine position was in the gingival sulcus or on the gingival tissue around the teeth (9,24). The major side effects were irritation and inflammation of the surrounding soft tissue and reduction of electric current to the bone following soft tissue resistance to the electric current. However, in this study, this side effect was prevented by using the intra-canal approach. Considering differential effects surrounding cathode and anode, there is a potential to increase or even decrease the remodeling potential (anchorage preparation) of the surrounding bone with proper selection of electrodes relative to the direction of OTM. This potential could be examined by evaluation of the rate of tooth movement with reverse setting, which clarifies the ability of direct current for anchorage enhancement during OTM.

In this study, the amount of electric current was determined following available guidelines. The 15 $\mu$ A constant direct current is the optimal setting of electric current application including variation in amplitudes, frequencies and type of electricity (26). However, the type of material used in the electrodes plays a pivotal role in determination of this current (19). To date, no study was aimed to report the optimal intensity of current based on the teeth location (upper and lower arch). Of course, application of this approach awaits further research to determine the optimal intensity based on bone density.

About the timing, different studies compared the rate of OTM at various time intervals (27). Park *et al.* (24) reported that significant increase in bone remodeling activity and subsequent tooth movement seemed to be continuing until the third week and stopped thereafter in the experimental groups. In this study, we evaluated the amount of tooth movement every two weeks up to eight weeks for the half of the samples. The results showed a significant difference only at four weeks, which is not in contrast to previous studies (24). The overall amount of OTM was also significantly greater in the experimental group compared to the control group (Table 1). When subgroup analysis was restricted to each arch (upper or lower), the difference in the amount of OTM between the experimental and control groups was only significant at T4 (8 weeks) and overall amount of tooth movement in the upper arch. Lower arch did not demonstrate any significant increase in OTM rate between the experimental and control groups. This observation could be possibility

related to higher density of lower arch in comparison to the upper arch (28). However, to generalize these data to the clinical setting, generally higher density of alveolar bone in animals compared to humans should be taken into account (29).

In this study, we used intracanal approach since the electrolyte present at the apex of the teeth can easily pass the current to the bone. Also, this point of application is much closer to the center of resistance of the teeth, which is the farthest area for the osteoclastic cells to reach (30). By doing so, we might possibly promote the opportunity of increasing the rate of bodily tooth movement indirectly. However, it is not logical to compromise tooth vitality just because of increasing the rate of tooth movement. Therefore, further studies are required to find more clinically applicable methods to apply direct electrical stimulation. But,

considering the significant positive effects of electric current on healing of bony defects (31,32), chronic ulcer healing (33) and also suppression of bacteria (34), intracanal approach may be useful for orthodontic movement of teeth with pre-existing endodontic lesions.

## Conclusion

According to the methodology proposed and based on the results of this study, it may be concluded that, direct intracanal electric stimulation via a miniature electric device used in this study is effective for increasing the rate and amount of OTM in dogs.

**Acknowledgement:** "None Declared"

**Conflict of interest:** "None Declared"

## References:

1. Sebaoun JD, Surmenian J, Dibart S. [Accelerated orthodontic treatment with piezocision: a mini-invasive alternative to conventional corticotomies]. *Orthod Fr.* 2011 Dec;82(4):311-9.
2. Tyrovola JB, Spyropoulos MN. Effects of drugs and systemic factors on orthodontic treatment. *Quintessence International* . May2001;32(5):365-71.
3. Genc G, Kocadereli I, Tasar F, Kilinc K, El S, Sarkarati B. Effect of low-level laser therapy (LLLT) on orthodontic tooth movement. *Lasers in medical science.* January 2013;28(1):41-7.
4. Finotti M, Del Torre M, Roberto M, Miotti FA. [Could the distalization of the mandibular molars be facilitated? A new therapeutic method]. *Orthod Fr.* 2009 Dec;80(4):371-8.



5. Altan BA, Sokucu O, Ozkut MM, Inan S. Metrical and histological investigation of the effects of low-level laser therapy on orthodontic tooth movement. *Lasers Med Sci.* 2012 Jan;27(1):131-40.
6. Torri S, Weber JB. Influence of low-level laser therapy on the rate of orthodontic movement: a literature review. *Photomed Laser Surg.* 2013 Sep;31(9):411-21.
7. Tweedle JA. The effect of local heat on tooth movement. *Angle Orthod.* 1965 Jul;35:218-25.
8. Litton SF. Orthodontic tooth movement during an ascorbic acid deficiency. *Am J Orthod.* 1974 Mar;65(3):290-302.
9. Davidovitch Z, Finkelson MD, Steigman S, Shanfeld JL, Montgomery PC, Korostoff E. Electric currents, bone remodeling, and orthodontic tooth movement. I. The effect of electric currents on periodontal cyclic nucleotides. *Am J Orthod.* 1980 Jan;77(1):14-32.
10. Davidovitch Z, Finkelson MD, Steigman S, Shanfeld JL, Montgomery PC, Korostoff E. Electric currents, bone remodeling, and orthodontic tooth movement. II. Increase in rate of tooth movement and periodontal cyclic nucleotide levels by combined force and electric current. *Am J Orthod.* 1980 Jan;77(1):33-47.
11. Shayesteh YS, Eslami B, Dehghan MM, Vaziri H, Alikhassi M, Mangoli A, et al. The effect of a constant electrical field on osseointegration after immediate implantation in dog mandibles: a preliminary study. *J Prosthodont.* 2007 Sep-Oct;16(5):337-42.
12. Gardner SE, Frantz RA, Schmidt FL. Effect of electrical stimulation on chronic wound healing: a meta-analysis. *Wound Repair Regen.* 1999 Nov-Dec;7(6):495-503.
13. Evans RD, Foltz D, Foltz K. Electrical stimulation with bone and wound healing. *Clin Podiatr Med Surg.* 2001 Jan;18(1):79-95.
14. Jacobs JD, Norton LA. Electrical stimulation of osteogenesis in periodontal defects. *Clin Orthop Relat Res.* 1977 May;(124):41-52.
15. Friedenber ZB, Brighton CT. Bioelectricity and fracture healing. *Plast Reconstr Surg.* 1981 Sep;68(3):435-43.
16. Hashimoto H. Effect of micro-pulsed electricity on experimental tooth movement. *Nihon Kyosei Shika Gakkai Zasshi.* 1990 Aug;49(4):352-61.
17. Modarresi J, Aghili H, Karandish M, Jalali B, Zahir ST. Effect of direct electric current on parietal bone osteogenesis. *J Craniofac Surg.* 2012 Nov;23(6):1607-9.

18. Bassett CA. Biologic significance of piezoelectricity. *Calcif Tissue Res.* 1968 Mar;1(4):252-72.
19. Brighton CT. Use of constant direct current in the treatment of nonunion. *Instr Course Lect.* 1982;31:94-103.
20. Long H, Pyakurel U, Wang Y, Liao L, Zhou Y, Lai W. Interventions for accelerating orthodontic tooth movement: a systematic review. *Angle Orthod.* 2013 Jan;83(1):164-71.
21. Kameda T, Ohkuma K, Sano N, Ogura H, Terada K. Intraoral conversion of occlusal force to electricity and magnetism by biting of piezoelectric elements. *Dent Mater J.* 2012;31(6):1001-7.
22. Sasaki S, Karube I. The development of microfabricated biocatalytic fuel cells. *Trends Biotechnol.* 1999 Feb;17(2):50-2.
23. Kolahi J, Abrishami M, Davidovitch Z. Microfabricated biocatalytic fuel cells: a new approach to accelerating the orthodontic tooth movement. *Med Hypotheses.* 2009 Sep;73(3):340-1.
24. Park SJ, Lee YJ, Park YG, Davidovitch Z. A study on the effects of Electrical stimulation by the miniature Electric device on the tooth movement and tissue remodeling. *Korean J Orthod.* 2003 Aug;33(4):279-291.
25. Isaacson BM, Bloebaum RD. Bone bioelectricity: what have we learned in the past 160 years? *J Biomed Mater Res A.* 2010 Dec;95(4):1270-9.
26. Bassett CA, Becker RO. Generation of electric potentials by bone in response to mechanical stress. *Science.* 1962 Sep;137(3535):1063-4.
27. Jung MH. Age, extraction rate and jaw surgery rate in Korean orthodontic clinics and small dental hospitals. *Korean J Orthod.* 2012 Apr;42(2):80-6.
28. Goldie RS, King GJ. Root resorption and tooth movement in orthodontically treated, calcium-deficient, and lactating rats. *Am J Orthod.* 1984 May;85(5):424-30.
29. Reitan K, Kvam E. Comparative behavior of human and animal tissue during experimental tooth movement. *Angle Orthod.* 1971 Jan;41(1):1-14.
30. Ren Y, Kuijpers-Jagtman AM, Maltha JC. Immunohistochemical evaluation of osteoclast recruitment during experimental tooth movement in young and adult rats. *Arch Oral Biol.* 2005 Dec;50(12):1032-9.

31. Verdonk R, Goubau Y, Almqvist FK, Verdonk P. Biological methods to enhance bone healing and fracture repair. *Arthroscopy*. 2015 Apr;31(4):715-8.
32. Lavine LS, Lustrin I, Shamos MH, Moss ML. The influence of electric current on bone regeneration in vivo. *Acta Orthop Scand*. 1971;42(4):305-14.
33. Barnes R, Shahin Y, Gohil R, Chetter I. Electrical stimulation vs. standard care for chronic ulcer healing: a systematic review and meta-analysis of randomised controlled trials. *Eur J Clin Invest*. 2014 Apr;44(4):429-40.
34. Aydin M, Gunay I, Pelit A, Serin MS. Deposition profile of antibacterial anodic silver in root canal systems of teeth. *J Biomed Mater Res*. 1997 Spring;38(1):49-54.